

Angiomyxolipoma in the 5th Metatarsal Base Region: A Case Report

Seung-Bum Chae, Sang-Wook Lee*, Won-Kee, Choi and Jae-Jung Kim

Department of Orthopaedic Surgery, Catholic University Medical Center, Daegu, Korea

*Corresponding author: Sang-Wook Lee, Department of Orthopaedic Surgery, Daegu Catholic University College of Medicine, 33 Duryugongwon-ro 17-gil, Nam-gu, Daegu 42474, Korea, Tel: +82-53-650-4272; Fax: +82-53-652-4272 E-mail: sbchae@cu.ac.kr

Rec date: Aug 25, 2016; Acc date: Sep 23, 2016; Pub date: Sep 29, 2016

Copyright: © 2016 Chae SB, et al. This is an open-access article distributed under the terms of the Creative Commons Attribution License, which permits unrestricted use, distribution, and reproduction in any medium, provided the original author and source are credited.

Abstract

The angiomyxolipoma is a very rare clinical entity that is considered a variant form of a common lipoma or of a spindle-cell lipoma, however two distinct entities are currently controversial. We report a 56-year-old previous healthy woman who had chief complaint of slow growing mass on the right foot for 3 years. Radiologic examination, ultrasonography, excision biopsy, immunohistochemistry was evaluated. Final diagnosis of angiomyxolipoma was done. We reviewed current articles about angiomyxolipoma and compared with our result. We discussed about its clinical significance.

Keywords: Angiomyxolipoma; Foot; Soft tissue mass; Lipoma

Introduction

Angiomyxolipoma was first described in 1996 by Mai et al. [1]. In most cases, angiomyxolipoma is asymptomatic, solitary, well demarcated mass. There are 20 reported cases of angiomyxolipoma which were found in subcutaneous tissue (10 cases), spermatic cord (2 cases), subungual (1 case), intra articular (2 cases), oral cavity (2 cases), colon (1 case), posterior mediastinal area (1 case), kidney (1 case), and upper lip (1 case) [1-9]. Subcutaneous occurrence of scalp, back, thigh, wrist, knee, forearm, and plantar area were reported. Among 20 patients, only 4 cases were female. In this report we introduce a female patient with subcutaneous angiomyxolipoma in the foot base region, and discuss about diagnosis and treatment.

Case Report

We report a 56-year-old previous healthy woman who had chief complaint of slow growing mass on the right foot for 3 years.

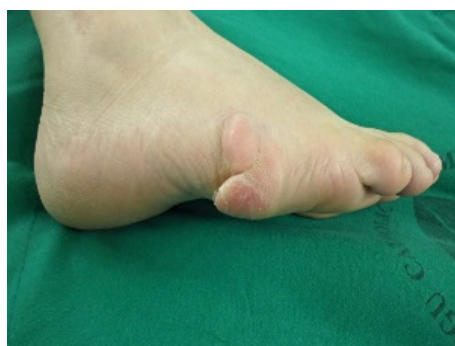

Figure 1: Pre-operation. Hyperkeratosis was seen.

The patient had skin hyperkeratosis on the lateral side of 5th metatarsal base and had occasional pain, VAS score of 2 per examination, there was a relatively well demarcated subcutaneous

mass, soft and has irregular surface, oval shape with 2 cm diameter, on the fifth metatarsal base area (Figure 1). The patient had tenderness on mass area. The patient had no trauma history and related past history. The mass showed non-specific radiolucent soft tissue mass density on plain film. Ultrasonography was performed, and revealed an inhomogeneous, lobulated, slightly hyperechoic mass lesion. It measured $1.7 \times 0.9 \times 1.4$ cm on diameter and partly showed slightly increased blood flow (Figure 2).

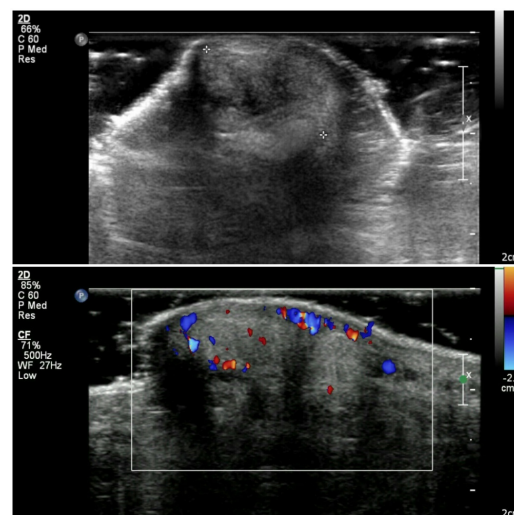


Figure 2: (a) Ultrasound, (b) Vascular Doppler study.

The patient wanted to delay the surgical removal and we carefully followed up the patient for 14 months and there was no change of the character and the size of the mass. After 14 months of follow up, the patient underwent the surgery for excisional biopsy. The surgery was done under peripheral nerve block anaesthesia with semi-lateral recumbent position. Routine orthopaedic drape was done and esmarch tourniquet was applied. Transverse incision was done and lipogenic mass was dissected for biopsy. Skin layer by layer suture was done after

vigorous irrigation with gentle compressive dressing. Intraoperative finding showed that the mass mimicked lipoma grossly.

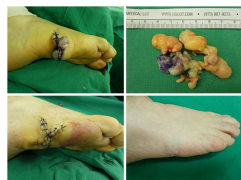

Figure 3: (a) Intra operation (b) Excised mass (c) Post operation, (d) follow up, wound healed.

But microscopically, it showed specific myxomatous findings. Random mixture of myxoid areas, fibrotic areas, mature adipose tissue, blood vessels and minimal inflammatory invasion was observed. It showed positive staining of the CD31, CD34, Vimentin, S-100 protein (S100), smooth muscle actin (SMA), Desmin, Von willebrand factor

(factor 8) and negative staining of human melanoma black 45 (HMB-45), Ki-67, alkaline lymphoma kinase (ALK), cytokeratin AE1/AE3 (CK AR1/3) in immunohistochemical analysis (Table 1).

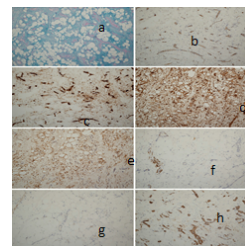


Figure 4: Immunohistochemistry and immunostain (a) Alcian blue, (b) CD31, (c) CD34, (d) Vimentin, (e) s100, (f) Desmin, (g) factor 8, (h) SMA, *Antibody: ABBOTT company.

Case	Reference	CD31	CD34	Vimentin	S-100	SMA	Desmin	HMB-45	Ki-67	ALK	CK QE1/3	Factor 8	Alcian blue
1	Mai et al.	NP	NP	+	+	+	NP	-	NP	NP	NP	NP	NP
2	Zamecnik	NP	+	NP	NP	-	NP	-	NP	NP	NP	NP	NP
3	Okafor et al.	NP	+	+	+	NP	NP	-	NP	NP	NP	NP	NP
4	Sciot et al.	NP	+	+	+	+	NP	-	NP	NP	NP	NP	NP
5	Tardio et al.	NP	+	+	+	+	-	-	<5	NP	NP	NP	NP
6	Lee et al.	NP	+	+	+	+	-	NP	<3	NP	NP	NP	NP
7	Lee et al.	NP	+	+	+	+	-	-	NP	NP	NP	NP	NP
8	Sanchez et al.	NP	NP	NP	NP	NP	NP	NP	NP	NP	NP	NP	NP
9	kang et al.	NP	+	+	-	-	-	-	<5	NP	NP	NP	NP
10	Song et al.	NP	+	+	+	+	-	-	NP	NP	NP	NP	NP
11	Kim et al.	NP	NP	NP	NP	NP	NP	NP	NP	NP	NP	NP	NP
12	Martinez et al.	NP	+	+	+	+	NP	-	0	NP	NP	NP	NP
13	Pukar et al.	NP	+	+	+	+	-	-	NP	NP	NP	NP	NP
14	Bergin et al.	NP	+	+	NP	NP	NP	NP	NP	NP	NP	NP	NP
15	Al shraim et al.	NP	NP	NP	NP	NP	NP	NP	NP	NP	NP	NP	NP
16	Hantous-Zannad et al.	NP	NP	NP	NP	NP	NP	NP	NP	NP	NP	NP	NP
17	Hammedi et al.	NP	+	+	+	+	-	-	<1	NP	NP	NP	NP
18	traboulsi et al.	NP	+	+	-	+	-	-	5	-	-	NP	NP

19	Woo et al.	NP	NP	NP	NP	NP	NP	NP	NP	NP	NP	NP	NP
20	Ruchi et al.	NP	+	NP	+	NP	NP	NP	NP	NP	NP	NP	NP
21	present case	+	+	+	+	+	-	0	-	-	-	+	+

Table 1: The results of immunohistochemical and Alcian blue stain.

Final diagnosis of angiomyxolipoma was achieved.

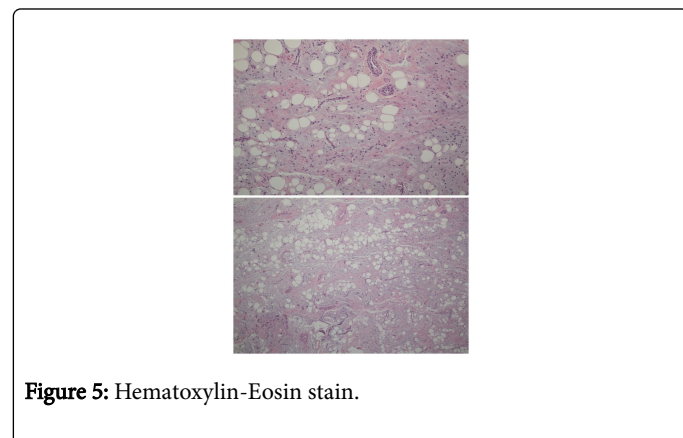


Figure 5: Hematoxylin-Eosin stain.

Surgical wound has mild pain but clean in inspection. On 4 weeks after surgery follow up, the hyperkeratosis was exfoliated. On 6 weeks follow up, the wound was completely healed with no pain. After 1 year of follow up, there has been no recurrence (Figures 3-5).

Discussion

Angiomyxolipoma was first reported by Mai et al. and there has been 20 reported case of since then. About half of patient with angiomyxolipoma has subcutaneous lesion but various different occurrence location was also reported. 16 men and 4 women have been reported and it is suggested that male predominance exists. The patient age ranged from 4 to 70 years with irregular distribution. There is no predilection to race, ethnicity or age [9,10].

Among 20 reported patients, 12 patients had painful mass and 8 patients had painless mass. Depending on location, mass symptoms were also reported. 18 cases were single lesion and 2 cases were multiple lesion [11-13]. By reported literature, disease duration ranged from 3 months to 7 years and follow up duration ranged from 2 months to 8 years but no malignant change or local recurrence were reported [7-9].

Radiologic specific finding doesn't exist and the tumor has heterogeneous signal intensity on MR because of its heterogeneous mixture property of components [11]. Its cut surface is yellowish, mixture of fat and mucus. The tumor sometimes has focal haemorrhage with vessel ectasia. In this case, we found focal increased local blood flow on USG.

Microscopically, paucicellular myxoid tissue, mature adipose tissue, dilated and various sized congestive blood vessels were randomly mixed and mild inflammatory infiltration was observed. We did immunohistochemical stain for further differential diagnosis. The three major components of angiomyxolipoma were mature tissue and the mass has its all unique cellular property. The vascular component

of tumor had immunoreactivity for various markers. CD31 (endothelial cell) CD34 (endothelial cell), Vimentin (marker for mesenchymal origin), SMA (smooth muscle), Desmin (intermediate filament in muscle) and factor-8 (endothelial cell) were stained and demonstrated its containing of mature vessel tissue component. The adipose tissue had immunoreactivity for S-100 protein (intermediate filament of adipocyte), and Vimentin. Negative reactivity for HMB-45 (antibody for melanoma), KI-67 (nuclear protein necessary for cellular proliferation) and ALK (anaplastic lymphoma kinase) discarded the possibility of myxoidliposarcoma and lipoblastoma. CK AE1/3 (cytokeratin) was negative and no evidence of epithelial differentiation was found. Alcian blue stained the paucicellular myxoid component of tumor. It revealed the shape of disorganized proliferation of myxoid tissue and loss of glandular structure.

After 1 years of follow-up, no recurrence has been observed in this case, assuming the benign nature of the lesion. But Careful follow-up was needed because one possible but important differential diagnosis is myxoidliposarcoma which is highly malignant lesion more common than angiomyxolipoma [11,12]. Other differential diagnosis contains spindle cell lipoma, angiomyolipoma, angiolipoma, angiofibrosarcoma, superficial angiofibroma, fibroepithelial stromal polyps, myxoidlipomatous tumors, myxoid leiomyoma which are all benign mass, differs from each other by histologic proportion of lipomatous, angiomatous, myomatous, fibrous property [12].

We suggest that clinicians should consider early biopsy when a patient has growing lipomatous lesion, because the final diagnosis can be only achieved by pathologic biopsy and immunochemistry.

References

1. Mai KT, Yazdi HM, Collins JP (1996) Vascular myxolipoma ("angiomyxolipoma") of the spermatic cord. Am J SurgPathol 20: 1145-1148.
2. Zamecnik M (1999) Vascular myxolipoma (angiomyxolipoma) of subcutaneous tissue. Histopathology 34: 180-181.
3. Martínez-Mata G, Roció ME, Juan LE, et al. (2011) Angiomyxolipoma (vascularmyxolipoma) of the oral cavity. Report of a case and review of the literature. Head Neck Pathol 5: 184-187.
4. Anand M, Deshmukh SD, Gulati HK (2012) Multiple subcutaneous angiomyxolipomas associated with olecranon bursa cyst: A rare presentation of a rare entity. Indian J Dermatol Venereol Leprol 78: 204-206.
5. Pukar M (2012) Angiomyxolipoma of transverse colon – A case report. Turk J Gastroenterol 23(2): 156-159.
6. Hantous-Zannad S, Neji H, Zidi A (2012) Posterior mediastinal angiomyxolipoma with spinal canal extension. Tunis Med; 90(8): 816-818.
7. Hammedi F, Fouli S, Hadhri R (2013) Angiomyxolipoma Report of a new case in subcutaneous tissue and review of the literature. JCRP 1: 17-19.
8. Nair S, Ramalingam W.V.B.S., Bharadwaj R (2013) Angiomyxolipoma: Unusual swelling of oral cavity. MJAFI 1-3.
9. Traboulsi SL, Wazzan W, AbouGhaida RR (2014) Renal angiomyxolipoma: Its First Appearance. Urol Case Rep 2: 89-92.

-
10. Song M, Seo SH, Jung DS (2009) Angiomyxolipoma (Vascular Myxolipoma) of Subcutaneous Tissue. Ann Dermatol 21: 189-192. English. Case Report.
 11. Sandberg AA (2004) Updates on the cytogenetics and molecular genetics of bone and soft tissue tumors: lipoma. Cancer Genet Cytogenet 150: 93-e115.
 12. Weiss SW, Goldblum JR, Enzinger FM (2001) Enzinger and Weiss's Soft Tissue Tumors. Philadelphia: Mosby-Harcourt Health Sciences.
 13. Kang, YooSeok, et al. (2008) A case of multiple angiomyxolipoma. Korean J Dermatol 46: 1090-1095.