

Antihyperglycemic Activity, Antihyperlipidemic Activity, Hepatoprotective Activity and Histopathological Analysis of Natural Honey in Streptozotocin Induced Diabetic Rats

Asaduzzaman M^{1*}, Nahar L², Hasan M³, Khatun A⁴, Shajedul Haque M¹, Hasan N¹, Tamanna Z¹, Huda N¹, Fazley Rabbi M¹, Ray M⁵, Nur Islam M⁵, Maniruzzaman M⁵, Mobassirul Islam M⁵, Dastagir N⁶ and Sarker S⁷

¹Department of Biochemistry and Molecular Biology, University of Rajshahi, Rajshahi, Bangladesh

²MBBS, Gonoshasthaya Samaj vittik Medical College and Hospital, Dhaka, Bangladesh

³Department of Biophysical Chemistry, Kyoto Pharmaceutical University, Nakauchi-cho, Misasagi, Yamashina-Ku, Kyoto, Japan

⁴Department of Pharmacology, Kyoto Pharmaceutical University, Nakauchi-cho, Misasagi, Yamashina-Ku, Kyoto, Japan

⁵Department of Pharmacy, University of Rajshahi, Rajshahi, Bangladesh

⁶Department of Public Health and Informatics, Jahangirnagar University, Savar, Dhaka

⁷Department of Microbiology and Veterinary Public Health, Chittagong Veterinary and Animal Sciences University, Chittagong, Bangladesh

Abstract

Honey contains a variety of phytochemicals and other substances, such as organic acids, vitamins and enzymes, which may serve as a source for dietary antioxidants. Antioxidants shows improve insulin level and protect insulin resistant in diabetes mellitus. Honey bee venom reduces blood glucose level as well as lipid profile through increased insulin secretion and glucose take-up. For that reason, honey could be considered as a potential remedy for diabetes as well as Cardiovascular Disease (CVD). The objective of this study was to determine the medicinal activity of honey and its role on antihyperglycemic, antihyperlipidemic, hepatoprotective activity and histopathological analysis of natural honey in Streptozotocin- induced diabetic rats. The experimental rats were divided into six groups (n = 6). Diabetes Mellitus (DM) was induced by single intraperitoneal injection (65 mg/kg BW) of freshly prepared Streptozotocin hydrate solution in 0.9% saline solution. Hyperlipidemic was induced by mixture of cholesterol (1.5%) and cholic acid (0.5%) with diet of rats. At the end of treatment, the blood glucose level and lipid profile was measured by using commercial kits. Histopathology of liver and heart were performed of observed any changes in the cellular structures (degradation and regeneration) of the rats after receiving the sample for 28 consecutive days with respect to control group. Honey bee-treatment significantly decrease blood glucose level in diabetic rats. TC, TG, LDL, VLDL are significantly (p < 0.05) decrease whereas HDL significantly increase (p < 0.001). The SGPT and SGOT were significantly decrease (p < 0.05) which showed hepatoprotective activity of honey. Honey has favorable effect on the histopathological changes in Streptozotocin- induced diabetic rats. On the basis of above findings, it can be concluded that, supplementation of honey could significantly contribute to control blood glucose level as well as lipid profile in diabetic subjects. Honey showed prevent various complications of diabetes and improve some haematological parameters.

Keywords: Honey; Glucose; Antihyperglycemic; Antihyperlipidemic; Hepatoprotective

Introduction

Diabetes mellitus is a metabolic disorder characterized by hyperglycemia, secretion insufficiency and receptor insensitivity to endogenous insulin [1]. It is a complex progressive disorder characterized by impaired insulin sensitivity, reduced insulin secretion and progressive failure of β -cells. Its incidence is associated with high morbidity and mortality rates. Increased oxidative stress is believed to play an important role in the etiology and pathogenesis of chronic complications of diabetes [2,3]. Free radicals are very reactive species, capable of inducing oxidation of the biological membrane of phospholipids and proteins, resulting in modifications of cell function and cellular death [4-6]. The risks of diabetic complications are particularly cardiovascular diseases (CVD) and peripheral vascular disease (PVD) [7]. Complications such as coronary artery disease (CAD), stroke, neuropathy, renal failure, retinopathy amputations, blindness etc. are known to be associated with diabetes mellitus [8]. Epidemiological reports have shown that the effect of postprandial hyperglycemia on cardiovascular risk is greater than the effect of fasting hyperglycemia. Despite excellent potencies, synthetic antidiabetic drugs had offered unwanted therapeutic profiles marked by fluid retention, drug-induced hypoglycemia, and increased rate of lactic acidosis, liver malfunctioning due to cirrhosis, weight gain and cardiac dysfunction [9]. Myocardial infarction (MI) is serious manifestations of Ischemic

heart disease. In the course of cardiac surgery and MI, ventricular arrhythmias such as ventricular tachycardia and ventricular fibrillation are the most important causes of mortality [10]. In management of such conditions, drug may be lifesaving. In the case of natural honey has been applied for medicinal purposes of cardiovascular diseases (CVD) [11]. Honey showed against cardiovascular risk factors such as hyperlipidemia by the antioxidant properties because antioxidants are neutralizing free radicals [12-14]. Diabetes mellitus is commonly associated with hepatic dysfunction or abnormalities such as elevations in serum alkaline phosphatase, aspartate aminotransferase (AST) and alanine aminotransferase (ALT), by the supplementation of honey it recover liver damage with the activation of glucokinase enzyme in the

***Corresponding author:** Asaduzzaman MD, Department of Biochemistry and Molecular Biology, University of Rajshahi, Rajshahi-6205, Bangladesh, Tel: +88-01719248007; E-mail: asad09bmb@gmail.com

Received December 05, 2015; **Accepted** March 22, 2016; **Published** March 30, 2016.

Citation: Asaduzzaman M, Nahar L, Hasan M, Khatun A, Shajedul Haque M, et al. (2016) Antihyperglycemic Activity, Antihyperlipidemic Activity, Hepatoprotective Activity and Histopathological Analysis of Natural Honey in Streptozotocin Induced Diabetic Rats. J Cytol Histol 7: 402. doi:10.4172/2157-7099.1000402

Copyright: © 2016 Asaduzzaman M, et al. This is an open-access article distributed under the terms of the Creative Commons Attribution License, which permits unrestricted use, distribution, and reproduction in any medium, provided the original author and source are credited.

process of glycogen synthesis [15]. There is no systematic data available on the physicochemical and medicinal properties of Bangladeshi honey. This study was undertaken to analyse Bangladeshi honey for better understanding of its medicinal properties.

Materials and Methods

Sample Collection: Multifloral honey samples were collected from the largest mangrove forest of the world, Sundarban, Bangladesh, in February 2015.

Animals care

Adult male and female Wistar rats (180-210 g) were used in this study. Animals were bred and reared in the animal house facility of the Department of Biochemistry and Molecular Biology, University of Rajshahi, at a constant room temperature of 25°C and in an environment with the humidity ranging between 35% and 65%. The rats were housed in plastic cages with soft wood-chip bedding and received a natural day-night cycle. The rats were provided with a standard laboratory pellet diet and water *ad libitum*. The experiments were conducted according to the ethical guidelines approved by the Institute of Biological Science (IBSc), Rajshahi University, Bangladesh.

Induction of diabetics

Diabetes was induced by single intraperitoneal administration of streptozotocin (65 mg/kg) body weight dissolved in 0.1 M citrate buffer, pH 4.5 in rats fasted for 16 hours. Another group of rats was injected with citrate buffer alone without streptozotocin. This group served as control. Two days after streptozotocin injection, development of diabetes was confirmed by measuring blood glucose levels in blood samples taken from tail vein. Rats with blood glucose concentrations of 11 mmol/L or higher were considered to be diabetic. Blood glucose levels of the control rats remained normal (< 4.2 mmol/L). Glucose measurement was performed with an Accu-Chek glucometer (Roche, Germany).

Blood collection

Blood samples from all groups were collected on days 1,7,14,21 and 28 in a fasting state from rat's marginal ear vein by 26G needle and syringe. Plasma concentrations of triglyceride (TG), total cholesterol (TC), HDL-cholesterol (HDL-C), LDL-cholesterol (LDL-C), VLDL, SGPT, SGOT were measured using a quantification kit (Linear chemicals, Barcelona, Spain) by automatic Bioanalyzer (Hitachi 7180, Hitachi, Tokyo, Japan). Statistical analysis was carried out using Science (SPSS) version 17.0. The data are expressed as mean ± SEM. P value <0.05, p < 0.001 were considered statistically significant.

Experimental animals grouping and treatment

The experimental rats were six groups and each group contain six rats (n = 6). Distilled water, honey and glibenclamide were administered once daily by oral gavage. The animals were treated for 4 weeks as follows:

Group-1: Non-diabetic rats + Distilled water (0.5 ml).

Group-2: Diabetic rats + Distilled water (0.5 ml).

Group-3: Diabetic rats + Honey (1.0 g/kg body weight).

Group-4: Hyper Cholesterol rats = cholesterol (1.5%) and cholic acid (0.5%) mix with diet.

Group-5: Hyper cholesterol rats + Honey (1.0 g/kg body weight).

Group	Blood sample drawing days				
	Day 1	Day 7	Day 14	Day 21	Day 28
Normal (control)	5.6 ± 0.1	5.8 ± 0.2	5.8 ± 0.1	5.8 ± 0.2	5.7 ± 0.1
Diabetic control	20.1 ± 0.5 ^{a*}	21.5 ± 0.4 ^{a*}	21.6 ± 0.7 ^{a*}	23.4 ± 0.5 ^{a*}	24.5 ± 0.5 ^{a*}
Diabetic+ Glibenclamide	20.3 ± 0.9 ^{b*}	16.4 ± 0.4	13.5 ± 0.5 ^{b*}	11.5 ± 0.7 ^{b*}	9.3 ± 0.3 ^{b*}
Diabetic + Honey	21.2 ± 1.0 ^{b#}	18.6 ± 0.8 ^{b#}	16.7 ± 1.3	14.9 ± 1.1	12.3 ± 0.5 ^{b#}

* Body weight decreases with injection of STZ. Body weights were measure with day 1 interval for 28 days. Each value is the mean ± SEM n = 6. Blood glucose level in the treated rats were significantly different from normal and diabetic control groups at ^{a*}P < 0.001, whereas ^{b*}P < 0.001 and ^{b#}P < 0.05 indicated the significantly difference from diabetic control group.

Table 1: Effect of honey on the blood glucose level of experimental rats (mmol/L).

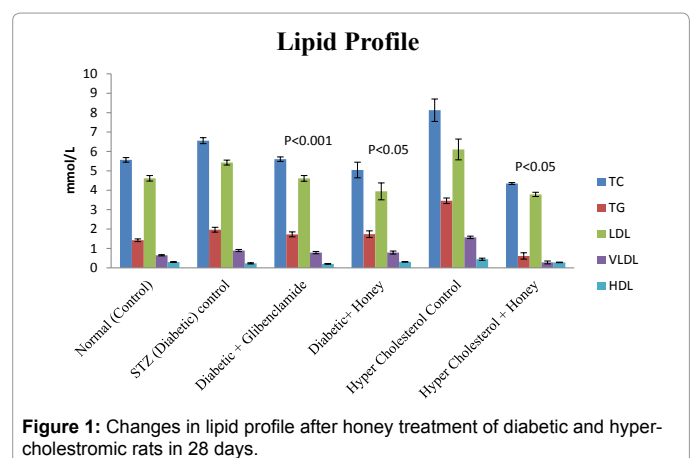


Figure 1: Changes in lipid profile after honey treatment of diabetic and hypercholesterolemic rats in 28 days.

Group-6: Diabetic rats + glibenclamide (0.5 mg/kg body weight).

Experiment of histopathology of liver and heart

According to [16] processing and staining technique was as follow: Tissue (liver and Heart) obtained from all experimental groups were washed immediately with saline and then fixed in 10% buffered neutral formalin solution. After fixation, the tissue was processed by embedding in paraffin. Then, the tissues were sectioned and stained with hematoxylin and eosin (H&E) and examined under high power microscope (200X,400X) and photomicrographs were taken.

Results

Table 1 showed blood glucose and body weight changes in experimental rats. The blood sugar measurements in diabetic rats after a 4-week treatment period showed significant variations among different groups (P < 0.001). Days 1, 7th, 14th, 21th, 28th, the diabetics rats group blood sugar level increasing maximum 23-25 mmol/L. In 28 days supplementation of honey blood glucose level significantly decrease 47.25% whereas Glibenclamide 63.47% (P < 0.001) (Figure 1).

Figure 1 showed the antihyperlipedemic activity of honey. In 28 days the level of Total cholesterol (TC), Triglycerides (TG), LDL, VLDL increase in diabetic rats group 23.05%, 11.73%, 27.30%, 12.35% respectively whereas the level of HDL decrease 30.43%. By the supplementation of honey the level of TC, TG, LDL, VLDL were decrease whereas HDL increase significantly (P < 0.05). In hypercholesterolemic rats group the Total cholesterol (TC), Triglycerides (TG), LDL, VLDL increasing as 46.55%, 82.31%, 38.03%, 82.80%, respectively whereas

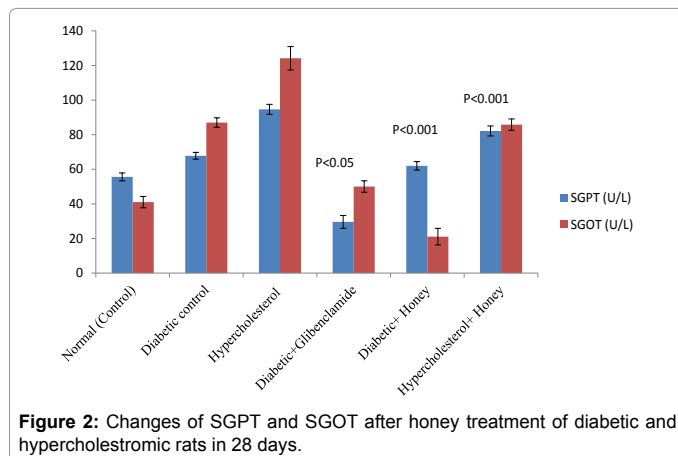


Figure 2: Changes of SGPT and SGOT after honey treatment of diabetic and hypercholesteremic rats in 28 days.

the level of HDL decrease 37.40% , By the supplementation of honey the level of TC, TG, LDL, VLDL were decrease whereas HDL increase significantly ($P < 0.05$) (Figure 2).

Figure 2 showed the hepatoprotective activity of honey in experimental rats. Increasing of SGPT and SGOT level after diabetes induction which was compensated by honey significantly ($P < 0.05$). The reduction of SGPT by honey was 38.19% respectively whereas 23.59% for glibenclamide. The reduction of SGOT level was highly significant for honey than glibenclamide.

Histopathological study

(A) Normal control: Showing normal-appearing of hepatocytes, portal space (PS), sinusoids (arrows), and Kupffer cells. (B) Diabetic control: Diabetic control histopathology of rats liver shown the micro fat droplet deposition (Black arrow) and the onset of sinusoidal enlargement (arrows) and small amount of fatty vacuoles, respectively. (C) Glibenclamide (10 mg/kg): Standard drug treated group shown histopathology similar to the normal control group. (D) Honey showed apparently normal architecture. The structure was quite similar to that of the control group and tissue damage and necrosis were of less extent in these groups than the DC group. (E) Liver from hypercholesterolemic rats sacrificed showing progressive worsening of sinusoidal enlargement (arrows) and liver fatty degeneration. (F) Honey treatment: Liver remained in apparently normal architecture with no deposition of cholesterol and triglyceride and no vesicular steatosis in the liver tissues (Figures 3 and 4).

(A) Normal control: Normal control group shown normal histopathology of the heart. (B) Diabetic control: Diabetic control histopathology shown increased interstitial space and distort the intercalated disc (Black arrow). (C) Glibenclamide (10 mg/kg): Glibenclamide treated drug shown the normal histopathology of heart. (D) Honey for three weeks led to a normal histological organization in the heart cells and nuclei. The antioxidant activity may have prevented the oxidative damage at the myocardium in STZ-induced diabetic rats. (E) Hypercholesterolemic control group heart histopathology showed degenerating muscle fibers and muscle fibers vacuolization, fibrosis, transverse striations and wide interfascicular spaces. (F) The heart cells and nuclei altered to a normal histological organization with honey treatment. Cardiac myofibres were arranged in normal structure. The samples were obtained from the same heart anatomical regions. For each group, 6 rats were examined and 50 pictures were taken. The above picture for each group was chosen randomly from the 80 pictures in this group. Original magnification 25X.

Discussion

The results from this study have shown that hyperglycemia Induced by injecting STZ in rats leads to cell death of neuronal cells in the hippocampus. In this study, honey treatment showed blood glucose levels lowering activity in streptozotocin induced diabetic rats. STZ monohydrate induces type-2 diabetes in experimental rats through exclusive destruction of insulin producing beta cells in pancreas [17]. Glibenclamide or honey significantly reduced blood glucose concentrations in our study which is similar to findings from previous studies [18]. Honey also contains elements such as zinc, selenium, copper, calcium, potassium, chromium, manganese, etc. [19]. Some of these minerals are reported to play vital roles in the maintenance of normal glucose tolerance and insulin secretion from the pancreatic β -cells [20]. Other ions such as copper and zinc are also known to be involved in glucose and insulin metabolism [21]. Even though the amounts of these minerals in honey may be small, it is worthwhile to note that these trace elements are not actually required in large quantities. Daily supplementation of the diabetic rats with honey for three weeks might attain sufficient concentrations of these minerals to elicit pharmacological responses which synergistically contribute to the hypoglycemic effect. Furthermore, improved secretion of insulin from the pancreas (possibly due to protective effect on beta cells) might contribute to the hypoglycemic effect of honey. The honey treatment lowered plasma glucose, cholesterol, triglyceride, and LDL levels and increased HDL levels in diabetic rats compare to untreated diabetic group. Our results were consistent with findings of Mousavi et al. which also confirmed hypoglycaemic and hypolipidemic activity of honey in diabetic mice [22]. In another study, honey reduces glycaemia and cholesterolemia in healthy subjects depending on the inoculated

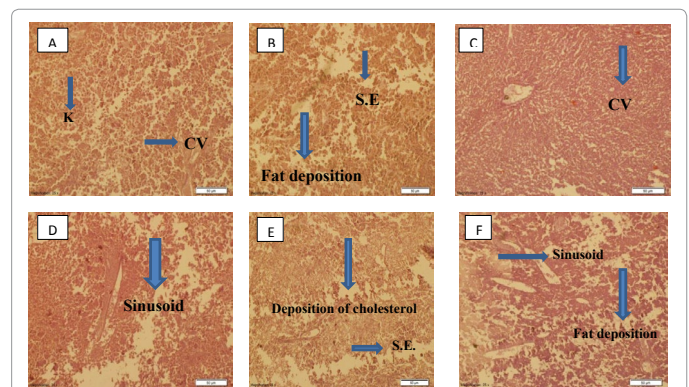


Figure 3: Fluorescence Microphotograph of Liver in different groups of rats.

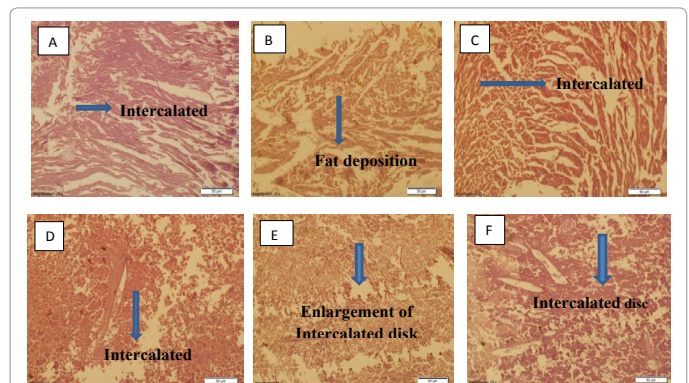


Figure 4: Fluorescence Microphotograph of Heart in different groups of rat.

dose [23]. The diabetic control rats showed insignificant increases in TG and VLDL levels while no significant change was observed in total cholesterol, HDL cholesterol and LDL cholesterol levels. Our findings are similar to those of Bin and his colleagues who also found insignificant lipid abnormalities in diabetic rats [24]. The decreased levels of TG and VLDL cholesterol in diabetic rats that received glibenclamide or metformin seem to corroborate previous findings that these drugs do ameliorate dyslipidemia [25-27]. Besides, significantly lower levels of VLDL cholesterol and TG observed in diabetic rats that received a glibenclamide or honey further demonstrate that honey has hypoglycemic agent's produces synergistic effect in reducing VLDL cholesterol and TG in diabetic rats. The SGOT and SGPT level was increased in diabetic patient as an indication of the liver damage that back to their respective normal level after treatment with honey and glibenclamide. The low level of SGOT and SGPT in honey consuming diabetic rats comparing to control rats indicated the normal function of liver [28]. Honey is a source of natural antioxidants that contain a number of phenolic acids, flavonoids, ascorbic acid, tocopherol, catalase, or other antioxidant enzymes and additives. All of these substances operate together to provide a synergistic antioxidant effect, scavenging and eliminating free radicals [29], which may help to inhibit hepatic or renal injury. El Denshary et al. also investigated the role of honey in carbon tetrachloride-induced hepatotoxicity and confirmed honey's potential role in significantly decreasing MDA levels in the liver. Histopathological examination of the liver section obtained from the control rats and rats treated with only honey showed normal hepatocyte architectures with the presence of the central vein (CV), cytoplasm, and nucleus. The liver tissues of the APAP-treated rats, however, showed marked CV distortion, edema, necrosis, and inflammatory cells, all of which are indicative of hepatic damage. The liver sections of the rats treated with honey followed by APAP intoxication clearly showed changes that indicated beneficial effects. Korkmaz and Kolankaya [30] reported that the non-protein sulfhydryl groups in some amino acids and in other components of honey may be involved in the prevention of toxin-induced morphological changes, including CV distortion or degeneration in liver tissues. Halawa et al. [31] also observed that honey can protect liver and kidney cells in rats from oxidative damage. Besides various normal functions liver excretes the breakdown product of hemoglobin namely bilirubin into bile. Pre-treatment of honey prevented severity of liver damage.

Conclusion

From the above findings it can be conclude that honey has great significance in the management of Diabetes Mellitus in STZ induced rats. The hypoglycaemic and hypolipidemic activity of honey on Streptozotocin induced diabetic rats through suppression of pancreatic beta cell inflammation, promotion of insulin secretion and promotion of glucose uptake in adipose tissue due to improvement of lipid uptake into adipose tissue and hydrolysis of triglyceride. The results of this study demonstrate that honey has a potent hepatoprotective action upon acetaminophen-induced oxidative stress and liver toxicity in rat. The hepatoprotective effect of honey can be correlated directly with its ability to reduce activity of serum enzymes and enhance antioxidant defense status. The findings of this study suggest that honey can be used as a safe, cheap, and effective alternative chemo preventive and protective agent in the management of liver diseases.

Statistical Analysis

The assays were carried out in triplicate, and the results were expressed as mean values and the standard deviation (SD). Results were

analyzed by using Scientific Package of Social Science (SPSS) version 17.0. Two different set of statistics, which is descriptive and analytical statistics was applied. The descriptive statistic was used to analyze mean, standard deviation (SD) whereby analytical statistics, one-way ANOVA was used to determine statistical significance ($p < 0.05$, $p < 0.001$) among the groups.

Acknowledgement

The financial supported was given by The Ministry of National Science and Technology (NST) Bangladesh, University Grant Commission (UGC) Bangladesh and Faculty of Science Rajshahi University, Rajshahi-6205, Bangladesh.

References

1. Rolo AP, Palmeira CM (2006) Diabetes and mitochondrial function: Role of hyperglycemia and oxidative stress. *Toxicol Appl Pharmacol* 212: 167-78.
2. Baynes JW (1991) Role of oxidative stress in development of complications in diabetes. *Diabetes* 40: 405-12.
3. Vincent AM, Brownlee M, Russell JW (2002) Oxidative stress and programmed cell death in diabetic neuropathy. *Ann N Y Acad Sci* 959: 368-83.
4. Therond P, Bennefont-Rousselot D, Davit-Spraul A, Conti M, Legrand A (2000) Biomarkers of oxidative stress: An analytical approach. *Curr Opin Clin Nutr Metab Care* 3: 373-84.
5. Droge W (2002) Aging-related changes in the thiol/disulfide redox state: Implications for the use of thiol antioxidants. *Exp Gerontol* 37: 1333-45.
6. Damasceno DC, Volpato GT, Calderon IMP, Rudge MVC (2002) Oxidative stress and diabetes in pregnant rats. *Anim Reprod Sci* 72: 235-44.
7. Bajaj JS, Madan R (1993) Diabetes in tropics and developing countries. *IDF bull* 38: 56.
8. Nathan DM (1996) The pathophysiology of diabetic complications: How much does the glucose hypothesis explain? *Ann Intern Med* 124: 286-289.
9. Rosen CJ (2010) Revisiting the rosiglitazone story—lessons learned. *N Engl J Med* 363: 803-806.
10. Selwyn AP, Braunwald E (2004) Ischemic heart diseases. In: Kasper LD, Fauci SA (eds.) *Harrison's Principles of Internal Medicine*. 16th (edn.) New York: The Mc GrawHill companies pp: 1434-1444.
11. Hume JR, Grant AO (2007) Agents used in cardiac arrhythmias. In: Katzung BG (ed.) *Basic and Clinical Pharmacology* 1. (10th edn.) San Francisco: The Mc GrawHill company's pp: 211-216.
12. Ahmed AK, Hoekstra MJ, Hage JJ, Karim RB (2003) Honey-medicated dressing: Transformation of an ancient remedy into modern therapy. *Ann Plast Surg* 50: 143-148.
13. Schramm DD, Karim M, Schrader HR, Holt RR, Cardetti M, et al. (2003) Honey with high levels of antioxidants can provide protection to healthy human subjects. *J Agric Food Chem* 51: 1732-1735.
14. Chepulis LM (2007) The effect of honey compared to sucrose, mixed sugars, and a sugar-free diet on weight gain in young rats. *J Food Sci* 72: S224-S229.
15. Al-Waili NS (2003) Intravenous and intrapulmonary administration of honey solution to healthy sheep: Effects on blood sugar, renal and liver function tests, bone marrow function, lipid profile, and carbon tetrachloride-induced liver injury. *J Med Food* 6: 231-47.
16. Bancroft DJ, Stevens A (1982) *Theory and practice of histological techniques*. (2nd edn.) Churchill Livingstone. Medical Division of Longman Group Limited.
17. Rakietyen N, Rakietyen ML, Nadkarni MV (1963) Studies on the diabetogenic action of streptozotocin (NSC-37917). *Cancer Chemother Rep* 29: 91-98.
18. Erejuwa OO, Sulaiman SA, AbWahab MS (2009) Effects of Malaysian tualang honey supplementation on glycemia free radical scavenging enzymes and markers of oxidative stress in kidneys of normal and streptozotocin-induced diabetic rats. *Int J Cardio* 137: S45.
19. Bogdanov S, Jurendic T, Sieber R (2008) Honey for nutrition and health: a review. *J Am Coll Nutr* 27: 677-689.
20. Kar A, Choudhary BK, Bandyopadhyay NG (1999) Preliminary studies on the inorganic constituents of some indigenous hyperglycaemic herbs on oral glucose tolerance test. *J Ethnopharmacol* 64: 179-184.

21. Arquilla ER, Packer S, Tarmas W (1978) The effect of zinc on insulin metabolism. *Endocrinology* 103: 1440-1449.
22. Mousavi SM, Imani S, Haghighi S, Mousavi SE, Karimi A (2012) Effect of Iranian honeybee (*Apis mellifera*) venom on blood glucose and insulin in diabetic rats. *J Arthropod Borne Dis* 6: 136.
23. Ivas C (2011) Glycemia and lipidemia variations of the rabbits inoculated with Bee venom. *USAMV, Romania* pp: 19-23.
24. Zhu B, Shen H, Zhou J, Lin F, Hu Y (2005) Effects of simvastatin on oxidative stress in streptozotocin-induced diabetic rats: A role of glomeruli protection. *Nephron Exp Nephrol* 101: e1-e8.
25. Al-Khalidi A, Jawed FH, Tawfiq NH (1980) Effects of bees honey, zahdi dates and its syrup on blood glucose and serum insulin of diabetics. *Nutr Rep Int* 21: 631-643.
26. Krentz AJ, Bailey CJ (2005) Oral antidiabetic agents: current role in type 2 diabetes mellitus. *Drugs* 65: 385-411.
27. Wiernsperger NF, Bailey CJ (1999) The antihyperglycaemic effect of metformin: Therapeutic and cellular mechanisms. *Drugs* 58: 31-39.
28. Laws A, Reaven GM (1992) Evidence for an independent relationship between insulin resistance and fasting plasma HDL-cholesterol, triglyceride and insulin concentrations. *J Intern Med* 231: 25-30.
29. Johnston JE, Sepe HA, Miano CL, Brannan RG, Alderton AL (2005) Honey inhibits lipid oxidation in ready-to-eat ground beef patties. *Meat Science* 70: 627-631.
30. Korkmaz A, Kolankaya D (2009) Anzer honey prevents N-ethylmaleimide-induced liver damage in rats. *Exp Toxicol Pathol* 61: 333-337.
31. Halawa HM, El-Nefiawy NE, Makhlof NA, Mady AA (2009) Evaluation of honey protective effect on lead induced oxidative stress in rats. *Journal of the American Society of Mining and Reclamation* 2: 197-209.

Citation: Asaduzzaman M, Nahar L, Hasan M, Khatun A, Shajedul Haque M, et al. (2016) Antihyperglycemic Activity, Antihyperlipidemic Activity, Hepatoprotective Activity and Histopathological Analysis of Natural Honey in Streptozotocin Induced Diabetic Rats. *J Cytol Histol* 7: 402. doi:[10.4172/2157-7099.1000402](https://doi.org/10.4172/2157-7099.1000402)

OMICS International: Publication Benefits & Features

Unique features:

- Increased global visibility of articles through worldwide distribution and indexing
- Showcasing recent research output in a timely and updated manner
- Special issues on the current trends of scientific research

Special features:

- 700 Open Access Journals
- 50,000 editorial team
- Indexing at major indexing services
- Rapid review process
- Quality and quick editorial, review and publication processing
- Indexing at PubMed (partial), Scopus, DOAJ, EBSCO, Index Copernicus and Google Scholar etc
- Sharing Option: Social Networking Enabled
- Authors, Reviewers and Editors rewarded with online Scientific Credits
- Better discount for your subsequent articles

Submit your manuscript at: <http://www.omicsonline.org/submission/>