

## Antropyloric Duplication Cyst in a Boy with Non Bilius Vomiting

Virtut Velmishi\*

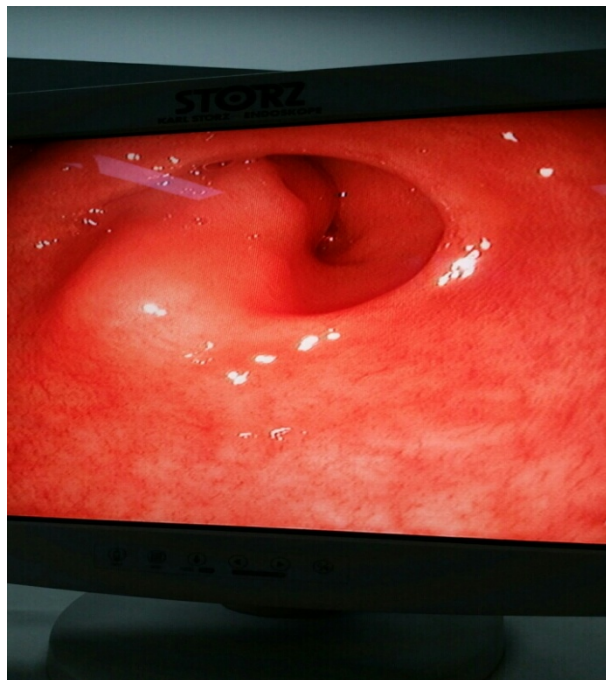
Department of Pediatrics, Mother Teresa Hospital, Albania

\*Corresponding author: Virtut Velmishi, Department of Pediatric Gastroenterology, Mother Teresa Hospital, Dibra Street, Nr 370, Tirana, Albania, Tel: 00355672057335; E-mail: [tutimodh@yahoo.com](mailto:tutimodh@yahoo.com)

Received date: Jul 25, 2016; Accepted date: Jul 27, 2016; Published date: Jul 29, 2016

Copyright: © 2016 Velmishi V. This is an open-access article distributed under the terms of the Creative Commons Attribution License, which permits unrestricted use, distribution and reproduction in any medium, provided the original author and source are credited.

### Clinical Image



**Figure 1:** Antropyloric duplication cyst image in an upper digestive endoscopy.

A four year-old boy was presented to our clinic because of recurrent non bilius vomiting. He had not history of previous serious illness. His examination showed a boy with normal height and weight for his age. During objective examination we didn't reveal anything abnormal. The blood cells count and biochemical examinations were totally normal. He underwent to an abdominal ultrasound which suspected a gastric duplication cyst. We performed an abdominal CT which confirmed the diagnostic of gastric duplication cyst. We decided to perform also an upper digestive endoscopy which showed an antropyloric duplication cyst (Figure 1) as a bulging mass blocking the pyloric passage. This child was referred to surgery for intervention.