

## Atypical Fibroxanthoma Arising on Chronic Burn Scar: A Rare Case Report and the Review of the Literature

Elif Calis\*, Asli Cakir, Mustafa Keskin and Ilknur Turkmen

Department of Pathology, Istanbul Medipol University, Turkey

Department of Plastic and Reconstructive Surgery, Istanbul Medipol University, Turkey

\*Corresponding author: Elif Calis, Department of Pathology, Istanbul Medipol University, Turkey, E-mail: elifcalis261@gmail.com

Received date: July 17, 2018; Accepted date: Nov 26, 2018; Published date: Nov 29, 2018

Copyright: ©2018 Calis E, et al. This is an open-access article distributed under the terms of the Creative Commons Attribution License, which permits unrestricted use, distribution, and reproduction in any medium, provided the original author and source are credited.

### Abstract

Atypical Fibroxanthoma (AFX) is a rare cutaneous mesenchymal neoplasm, predominantly found on sun-damaged skin of the head and neck in elderly patients. But uncommonly it can develop on a burn scar with or without actinic damage. Malignancy development is the major complication of severe burns and malignant transformations of those burn scars are accepted as Marjolin's ulcers clinically. The most common malignancy in this setting is Squamous Cell Carcinoma (SCC), followed by Basal Cell Carcinoma (BCC) and Malignant Melanoma (MM). Mesenchymal tumors especially malign forms quite infrequently seen on scar tissue. Herein, we present a rare and unusual case of AFX arising on the non-sun-damaged area within a chronic burn scar of a young patient. Four cases of burn-related AFX reported in the literature are reviewed and the histopathological features and differential diagnosis are discussed.

**Keywords:** Actinic damage; Marjolin's ulcer; Non-sun-damaged skin

### Introduction

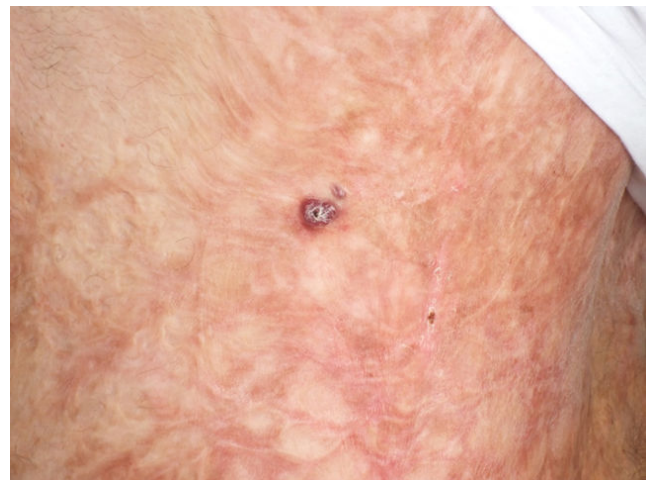Atypical Fibroxanthoma (AFX) is an uncommon, low-grade sarcoma, characterized by morphologic features of malignancy but indolent clinical behavior. AFX mainly affects elderly males in the seventh decade [1,2].

Presentation at a younger age is exceptional but may be seen in the setting of Xeroderma Pigmentosum or Li Fraumeni syndrome [3,4]. Malignant transformation of untreated chronic wounds is a well-known issue. Beside the common tumors are SCC, BCC, and MM, there are also other tumors such as sarcomas [5]. AFX is very rare in this setting and there have been only four previous reports of AFX in chronic burn scar to the best of our knowledge.

Here, we present a case of AFX arising in a chronic burn scar without associated actinic damage and review the literature.

### Case Report

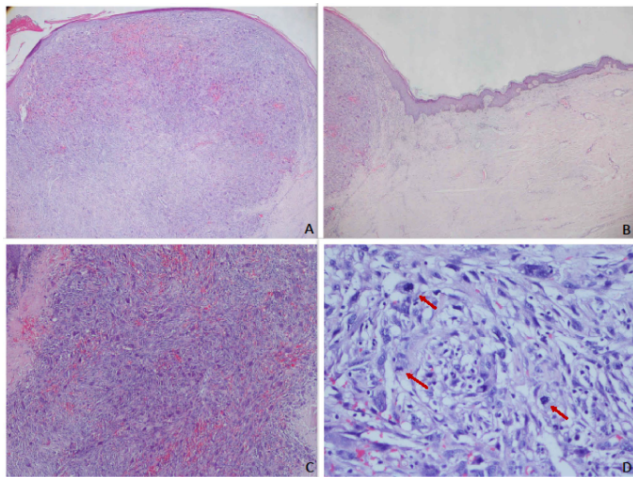
A 31-year-old male patient with a history of a thermal burn 20 years ago, admitted to plastic surgery service in Medipol Mega Hospital with the complaint of an intractable ulcer on his left side of mid-back despite conservative treatment for 6 months. On physical examination, there was an extensive burn scar affecting his entire back. On the scar area two exophytic nodular lesions were seen with erythematous scaly appearance, 1.3 cm and 0.5 cm in size with 0.2 cm distance in between (Figure 1). The surrounding skin showed mild contracture. Wide excision and split-thickness skin graft were performed with a clinical diagnosis of Marjolin's ulcer.



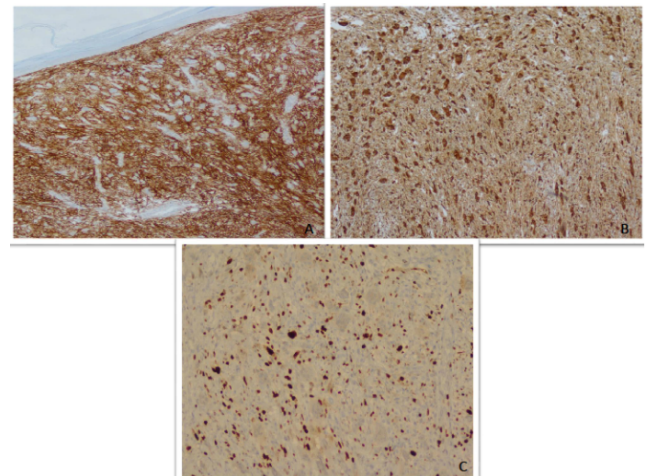
**Figure 1:** Patient with wide contracted burn scar located at the middle of the back and two ill-defined nodular lesions, 1.3 and 0.5 cm in diameter.

Histologically both of nodular lesion had a relatively well-defined border in the dermis (Figure 2a). There was no epidermal connection or precursor lesion in the epidermis. The overlying epidermis was atrophic. Fibrosis due to the old burn scar in the surrounding skin was evident (Figure 2b). The tumor was composed of pleomorphic spindle cells, admixed with multinucleated osteoclast-like giant cells and mononuclear inflammatory cells including lymphocytes, plasma cells, and histiocytes. Hemorrhage was prominent in focal areas (Figure 2c). Mitosis was frequent and also had atypical and bizarre forms (Figure 2d). There was neither necrosis nor vascular, lymphatic or perineural invasion. Deep invasion into the subcutaneous fat was not observed. There was no evidence of epithelial or squamous differentiation. The

surgical resection margins were clear of the tumor. The immunohistochemical staining revealed strong positivity for CD68 and CD10 (Figure 3a and 3b). Neoplastic cells were negative with cytokeratin, p63, HMB45, Smooth Muscle Actin (SMA) and CD34. P53 expression was not seen, and Ki67 proliferation index was not very high (7-8%) (Figure 3c). On the basis of the pathological and immunohistochemical findings, a final diagnosis of atypical fibroxanthoma was given. In two years of clinical follow-up, no local recurrence or distant metastasis was observed.



**Figure 2:** (a) Low-power view of the well-circumscribed dermal nodule with no involvement of the subcutis (HandE, original magnification 20X); (b) Burn-induced scar tissue formation around the tumor. Note actinic damage does not appear (HandE, original magnification 20X); (c) Spindled tumor cells in haphazard or fascicular pattern and bizarre multinucleated pleomorphic cells present, extensive hemorrhage is seen (HandE, original magnification 40X); (d) Frequent mitotic figures shown with red arrows (HandE, original magnification 200X).



**Figure 3:** (a,b) Immunohistochemically, a homogeneous expression of CD10 and CD68, respectively (Original magnification 40X); (c) Ki67 proliferation index (7-8%) (Original magnification 100X).

## Discussion

Atypical fibroxanthoma is rare in the general population and almost always occurs in severely sun damaged skin. The pathogenesis of AFX is still unclear, but most publications agree that ultraviolet-induced damage is an important factor in its development. For example, most lesions are found in the head and neck region, where exposure to sunlight is the highest [1,2,6].

Several factors have been described in the development of malignant tumors in the burn scars. These are chronic irritation and inflammation, potential carcinogens found in burnt skin, anoxia and abnormal immune surveillance resulting from damaged lymphatics and avascular tissue [5,7]. According to one of the proposed theories, the burn itself is not carcinogenic, but the tissue becomes more susceptible to other carcinogens such as ultraviolet radiation [8,9].

AFX frequently presents in the dermis as a well-circumscribed nodule with overlying epidermal collarette. Histologically, composed of a variable admixture of pleomorphic epithelioid, spindled, and multinucleated tumor giant cells with bizarre and pleomorphic nuclei. Mitotic activity is brisk and includes atypical forms [2,6]. Diagnosis requires extensive sampling and an expanded panel of immunohistochemistry. Markers such as CD68, CD10, vimentin, and SMA are not specific but are positive in the majority of tumoral cells [6]. The differential diagnosis includes a wide range of tumors having a spindle and sarcomatous features. Epithelial tumors (poorly differentiated SCC), melanocytic tumors (spindle cell MM) and sarcomas (cutaneous leiomyosarcoma, dermatofibrosarcoma protuberans, pleomorphic dermal sarcoma, angiosarcoma) should be excluded. For this reason, S-100, HMB-45, Melan-A (for MM), cytokeratins (for poorly differentiated carcinomas), SMA, desmin, H-caldesmon (for leiomyosarcomas), and CD31 (for angiosarcomas) should be used [6]. Main differential diagnosis is with Pleomorphic Dermal Sarcoma (PDS). Both are closely related cutaneous mesenchymal tumors which have same immunohistochemical expression pattern but have different clinicopathologic features. AFX does not show invasion of the deep subcutaneous tissue, and there are

no tumor necrosis, lymphovascular invasion or perineural infiltration. If these findings are present, the diagnosis should be PDS. It invades not only deep subcutaneous tissues but also frequently skeletal muscle and underlying fascia [1,2,6].

A comprehensive review of the reported four AFX cases arising in burn scar and current case are given in Table 1. Location of tumors was head and neck (three cases) and upper back (two cases). All patients were male. The age distribution was 31-93 (mean age: 61.2) and the current case was the youngest. The reported period between the injury and AFX detection was more than 40 years. In the current case, the latent period was about 20 years. Tumor size ranged between 1.3-4.2 cm (mean: 2.6 cm). In the follow-up, one patient had SCC and MM 10 years later [10], one patient's information wasn't available, in other cases metastasis and new cancer development has not been reported. Only one case had concomitant SCC [11]. In three reports there was accompanying actinic keratosis, the authors presumed that the

summative effect of actinic damage on the burn scar or skin graft-induced the evolution of AFX. In contrast to these three cases, one case and our patient's AFX developed directly within a burn scar, within non-sun exposed skin in an area that histopathologically showed no elastosis [12].

The general choice of treatment in AFX is wide excision with or without a skin graft. If excision is adequate, AFX has an excellent prognosis and metastasis is rare [6]. There were no metastatic lesions in the reported cases of AFX in burn scars. Our case has 2 years follow-up and no local recurrence or distant metastasis is observed.

This case is the fifth case report of AFX, developing within a burn scar and the second case observed non-sun-exposed dorsal skin which represents rare sites of occurrence and the youngest patient's in the literature.

| Patient                | Age gender | Localization                | Size (cm)         | Type of burn  | Actinic damage | Latent period (years) | Duration of complaints | Simultaneous neoplasm | Follow-up metastasis or other cancers       |
|------------------------|------------|-----------------------------|-------------------|---------------|----------------|-----------------------|------------------------|-----------------------|---|
| Eckert F et al. [11]   | 66/M       | The left side of his face   | Not recorded      | Thermal burn  | Present        | >50                   | Not recorded           | SCC                   | Not recorded                                |
| Hiscutt EL et al. [10] | 50/M       | The angle of the mandibular | 1.3 × 1.2 cm      | Flame Burn    | Present        | 47                    | 2 months               | No                    | 10 years later he presented with SCC and MM |
| Ergün SS et al. [13]   | 66/M       | Left cheek                  | 4.2 × 2.3 cm      | Flame burn    | Present        | 65                    | 8 months               | No                    | No  |
| Ito A et al. [12]      | 93/M       | Left upper back             | 3.5 × 2.7 cm      | Moxa-cautery* | Not observed   | Not recorded          | 1 year                 | No                    | No  |
| Current case           | 31/M       | Mid back                    | 1.3 cm and 0.5 cm | Thermal burn  | Not observed   | 20                    | 6 months               | No                    | No  |

**Table 1:** Review of the reported cases and the current case. \*Moxa cautery represents a Japanese folk remedy that is believed to relieve several symptoms, including pain.

## References

- Brenn T (2014) Pleomorphic dermal neoplasms: A review. *Adv Anat Pathol* 21: 108-130.
- Koch M, Freundl AJ, Agaimy A, Kiesewetter F, Kuenzel J, et al. (2015) Atypical fibroxanthoma-histological diagnosis, immunohistochemical markers and concepts of therapy. *Anticancer Res* 35: 5717-5735.
- Shalabi N, Galor A, Dubovy SR, Thompson J, Bermudez-Magner JA, et al. (2015) Atypical Fibroxanthoma of the Conjunctiva in Xeroderma Pigmentosum. *Ocul Oncol Pathol* 1: 254.
- Lee SM, Zhang W, Fernandez MP (2014) Atypical Fibroxanthoma arising in a young patient with Li-Fraumeni syndrome. *J Cutan Pathol* 41: 303.
- Kowal-Vern A, Criswell BK (2005) Burn scar neoplasms: A literature review and statistical analysis. *Burns* 31: 403-413.
- Lopez L, Velez R (2016) Atypical fibroxanthoma. *Arch Pathol Lab Med* 140: 376.
- Mellemkjaer L, Holmich LR, Gridley G, Rabkin C, Olsen JH (2006) Risks for skin and other cancers up to 25 years after burn injuries. *Epidemiology* 17: 668-673.
- Bostwick J, Pendergast WJ, Vasconez LO (1976) Marjolin's ulcer: An immunologically privileged tumor? *Plast Reconstr Surg* 57: 66-69.
- Dvorak HF (1986) Tumors: wounds that do not heal. Similarities between tumor stroma generation and wound healing. *N Engl J Med* 315: 1650-1657.
- Hiscutt EL, Adams JR, Ryan JM, Langtry JA, Natarajan S (2009) Atypical fibroxanthoma, lentigo maligna melanoma and squamous cell carcinoma arising in the site of a thermal burn treated with skin grafts. *Br J Oral Maxillofac Surg* 47: 157.
- Eckert F, Schaich B, Landthaler M (1991) Spinocellular cancers and myxoid atypical fibroxanthoma of an actinically damaged burn scar. *Hautarzt* 42: 254.
- Ito A, Yamada N, Yoshida Y, Morino S, Yamamoto O (2011) Myofibroblastic differentiation in atypical fibroxanthomas occurring on sun-exposed skin and in a burn scar: An ultrastructural and immunohistochemical study. *J Cutan Pathol* 38: 670.
- Ergün SS, BÜYÜKBABANI N, Su Ö (2011) Atypical fibroxanthoma in a chronic burn scar of the cheek. *J Dermatol* 38: 1000-1003.