

Can Lupus Mastitis be Treated Surgically?

Taner Dandinoglu^{1*}, Ozgür Dandin², Yasam Kemal Akpak³, Tuncer Ergin⁴ and Murat Karadeniz⁵

¹Department of Physical Medicine and Rehabilitation, Bursa Military Hospital, Bursa, Turkey

²Department of General Surgery, Bursa Military Hospital, Bursa, Turkey

³Department of Obstetrics and Gynecology, Mevki Military Hospital, Ankara, Turkey

⁴Department of Radiology, Bursa Military Hospital, Bursa, Turkey

⁵Department of Physical Medicine and Rehabilitation, Çorlu Military Hospital, Tekirdağ, Turkey

*Corresponding author: Taner Dandinoglu, Department of Physical Medicine and Rehabilitation, Bursa Military Hospital, Bursa, Turkey, Tel: +90 533 691 40 66; E-mail: dandinoglu@gmail.com

Rec Date: Mar 10, 2014; Acc Date: Mar 21, 2014; Pub Date: Mar 27, 2014

Copyright: © 2014 Dandinoglu T, et al. This is an open-access article distributed under the terms of the Creative Commons Attribution License, which permits unrestricted use, distribution, and reproduction in any medium, provided the original author and source are credited.

Abstract

Lupus mastitis is a rare chronic inflammatory reaction of the sub-cutaneous fatty tissue of the breast and may appear in 2-3% of patients with systemic lupus erythematosus. Surgical intervention is not needed for the treatment of lupus mastitis, and if necessary the least invasive procedure should be chosen. In this case, despite the use of hydroxychloroquine and oral steroids, patient with malignancy risk and ongoing complaints went to excision. Surgery appears to be effective in patients with ongoing complaints despite the adequate medical treatment.

Introduction

Lupus mastitis (LM) is an uncommon and rare clinical presentation of systemic lupus erythematosus (SLE) which is described as benign inflammation of the deep subcutaneous adipose tissue of the breast. While a vast majority of patients present with systemic or discoid lupus (DL), LM can be the initial finding [1]. When the breast is affected, the term LM is used. The etiology is not clearly known. Skin manifestations of LM are as follows: epidermal atrophy, hyperkeratosis, lipoatrophy, erythema, hypertrichosis, ulceration and if left untreated - even fistulization, atrophy with scarring and retraction may develop. LM has a chronic course with aggravation and remission. Clinically close follow-up is required as flare ups can emerge in a different area. Antibodies can present, but are not required for the diagnosis [1,2]. Breast lupus panniculitis are usually solid and can mimic malignancies [3]. If skin changes are evident, it may be difficult to distinguish LP from inflammatory breast cancer [4]. While hydroxychloroquine is the first line treatment option for LM, systemic steroids and cyclophosphamide may also be used [5]. Deep localisation of the lesions mostly require tissue biopsy to determine whether a neoplasm exists or not. In patients diagnosed with SLE or DL, aggressive surgical interventions can trigger exacerbation [6]. In this paper, we report a case of surgically treated lupus mastitis which has ongoing complaints despite medical treatment for nearly two years.

Case

A 46-year-old woman presented to an outpatient clinic with redness, retraction and discharge from her left nipple (Figure 1). Medical history revealed that she has been using hydroxychloroquine at 400 mg/day for 1 year and 10 mg/kg/day prednisone for nearly 2 years (due to suspicion of aggravation, 1 mg/kg/day prednisone for the last 3 months). Despite this medical treatment regimen, the patient continued to have the same complaints.

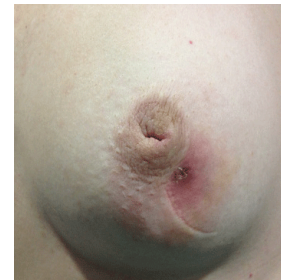

Figure 1 : A 46-year-old woman with redness, retraction and discharge from left nipple

Antinuclear antibody titers were low. C-reactive protein (CRP), erythrocyte sedimentation rate (ESR) and other routine lab tests were in normal range. Leucopenia, anemia and thrombocytopenia were not observed. A breast ultrasound revealed increased echogenicity of the sub-cutaneous adipose tissue and parenchyma due to edema, thickening of the skin and a sub-cutaneous fistula extending through the skin in the lower outer quadrant of the left breast.

The suspicious mass was completely excised due to malignancy risk and complaints refractory to guideline medical treatment. No complications were seen post operatively, and wound healing was also normal (Figure 2). Histopathological examination of the excised tissue revealed lymphocytic lobular panniculitis containing plasma cells and fat necrosis (Figure 3). In addition to hydroxychloroquine at 200 mg/day, the patient has been using prednisone 10 mg/day post operatively. A follow-up program including 6 consecutive monthly breast ultrasounds was planned. In the 10 months since the patient's intervention, she has had no further symptoms of panniculitis in her breast.

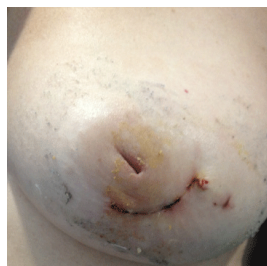

Figure 2 : Patient's left breast after intervention

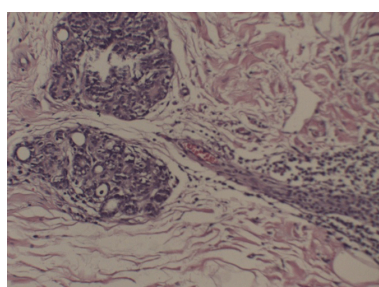


Figure 3 : 46-year-old woman with lupus mastitis. Photomicrographs of histopathologic specimen of excised tissue show lymphocytic panniculitis

Discussion

Panniculitis is an inflammatory condition of sub-cutaneous fat tissue which is associated with several conditions including SLE and other connective tissue diseases. When associated with SLE or DL and presenting with breast involvement it is called LM. It occurs in 2% to 3% of SLE patients [2]. Typical lesions are deep subcutaneous nodules described as a firm, irregular, well-circumscribed palpable mass which is suspicious for a breast neoplasm [6,7]. Mammographic image of LM typically shows a dense, irregular, heterogeneous breast tissue [8]. A breast ultrasound can show skin thickening and a heterogeneous mass which is usually hyperechoic and may extend into the sub-cutaneous fat [9]. Histological examination reveals panniculitis with a marked lymphocytic infiltrate of the fat lobules which mimics a breast tumor [10].

Antimalarial drugs are the primary medical treatment option for LM, corticosteroids may also be used in combination or alone. Surgical

interventions take place when lesions mimic a neoplasm. Although the patient with LM is under risk of malignancy, surgery should only be considered in patients with ongoing complaints despite appropriate medical treatment, because of the possibility of triggering the risk of additional exacerbations [6].

In this report, despite the use of hydroxychloroquine and oral steroids for nearly 2 years, the patient with ongoing complaints and suspected malignancy went to excision for a clear diagnosis and management of the disease. Histopathologic specimen of excised tissue shows lymphocytic panniculitis, which is congruent with LM.

In this case, although it has been reported that trauma can initiate or exacerbate the disease, surgery appears to be effective in patients with an increased risk for malignancy and ongoing complaints despite appropriate medical treatment. In conclusion, we aimed to emphasize and note that surgery may be reasonable and more appropriate under certain conditions for carefully selected LM patients. Additional experimentations and studies are needed to determine certain decisions.

References

1. Kinonen C, Gattuso P, Reddy VB (2010) Lupus mastitis: an uncommon complication of systemic or discoid lupus. *Am J Surg Pathol* 34: 901-906.
2. Summers TA Jr, Lehman MB, Barner R, Royer MC (2009) Lupus mastitis: a clinicopathologic review and addition of a case. *Adv Anat Pathol* 16: 56-61.
3. Rosa M, Mohammadi A (2013) Lupus mastitis: a review. *Ann Diagn Pathol* 17: 230-233.
4. Fernandez-Flores A, Crespo LG, Alonso S, Montero MG (2006) Lupus mastitis in the male breast mimicking inflammatory carcinoma. *Breast J* 12: 272-273.
5. Castro GR, Appenzeller S, Soledade C, Bértolo MB, Costallat LT (2004) Mastitis refractory to cyclophosphamide in systemic lupus erythematosus. *Clin Exp Rheumatol* 22: 786.
6. Bayar S, Dusunceli E, Ceyhan K, Unal E, Turgay M (2007) Lupus mastitis is not a surgical disease. *Breast J* 13: 187-188.
7. Cerveira I, Costa Matos L, Garrido A, Oliveira E, Solheiro H, et al. (2006) Lupus mastitis. *Breast* 15: 670-672.
8. Georgian-Smith D, Lawton TJ, Moe RE, Couser WG (2002) Lupus mastitis: radiologic and pathologic features. *AJR Am J Roentgenol* 178: 1233-1235.
9. Sabaté JM, Gómez A, Torrubia S, Salinas T, Clotet M, et al. (2006) Lupus panniculitis involving the breast. *Eur Radiol* 16: 53-56.
10. Arsenovic N, Terzic M (2008) Lupus mastitis mimicking a breast tumor. *J Obstet Gynaecol Res* 34: 919-921.