

## Candidemia with Prosthetic Aortic Graft: Case Report

Dan Sun<sup>1</sup>, Hongmei Jiao<sup>1\*</sup>, Jiali Du<sup>1</sup>, Ying Zhu<sup>2</sup>, Zhifang Fu<sup>1</sup>, Zeng Zeng<sup>1</sup>, Bo Zheng<sup>3</sup> and Alexa Lean<sup>4</sup>

<sup>1</sup>Department of Geriatrics, Peking University First Hospital, Beijing, PR China

<sup>2</sup>Department of Radiology, Peking University First Hospital, Beijing, PR China

<sup>3</sup>Institute of Clinical Pharmacology, Peking University First Hospital, Beijing, PR China

<sup>4</sup>The George Washington University School of Medicine, USA

\*Corresponding author: Hongmei Jiao, Department of Geriatrics, Peking University First Hospital, No 8, Xishiku Avenue, Beijing, PR China, Tel: 0086-10-83572167; Fax: 0086-10-66552095; E-mail: [jiaohm@139.com](mailto:jiaohm@139.com)

Received date: September 26, 2016; Accepted date: January 16, 2017; Published date: January 23, 2017

Copyright: © 2017 Sun D, et al. This is an open-access article distributed under the terms of the Creative Commons Attribution License, which permits unrestricted use, distribution, and reproduction in any medium, provided the original author and source are credited.

### Abstract

Infections of prosthetic aortic grafts status post-acute aortic dissection with *Candida albicans* (*C. albicans*) are rare. The gold standard of treatment for aortic graft infection is a combination of surgical resection and lifelong antimicrobial drug therapy, however postoperative mortality rates remain high. Here we present a 44-year-old man who presented with 2 months of fever, painful microembolic lesions localized to his right hypothenar eminence, right conjunctival hyperemia, right neural hearing loss, and a systolic murmur radiating from the aorta towards the neck. *C. albicans* was isolated from 3 separate blood cultures. Computed tomography (CT) displayed distinct thrombotic material affixed to the aortic prosthetic graft in the brachiocephalic artery. The patient was then treated with intravenous (IV) fluconazole for 8 weeks. During the treatment period, the patient suffered from brain hemorrhage in the right temporal lobe, presenting with hemiparesis. After 8 weeks on IV fluconazole, oral fluconazole was then administered. Through 12 months of follow up, he remained asymptomatic, lab values only notable for slightly elevated inflammatory markers. This case suggests that for some patients, either unwilling or unable to endure surgery, candidemia associated with a prosthetic graft can be managed conservatively, with antifungal therapy alone.

**Keywords:** Prosthetic aortic graft; *Candida albicans*; Prosthesis-related infections

**Abbreviations:** *C. albicans*: *Candida albicans*; CT: Computed Tomography; HIV: Human Immunodeficiency Virus; hs-CRP: High Sensitive C Reactive Protein; IV: Intravenous; MCA: Middle Cerebral Artery

### Introduction

Aortic prosthetic graft infection is a severe, yet rare, complication of operations related to acute aortic dissection. However, these infrequent infections have devastating mortality rates of 18-75% [1,2]. Specifically, aortic prosthetic graft infections requiring emergent treatment are associated with early and late mortality, as well as limb loss [3].

The diagnosis of aortic graft infection is based on clinical symptoms, imaging studies, and microbiological findings [4,5]. CT is the ideal imaging modality, with the caveat that culturing, if performed properly, is the ultimate method of diagnosis. Because of its high sensitivity, specificity, and speed, CT should be the first examination ordered in suspected cases [5].

Previous cases of systemic candidiasis typically report fatal outcomes [6,7]. Reoperation for graft replacement, combined with lifelong antifungal treatment, is considered the current gold standard therapy for this severe infection [4,8-11]. Importantly, surgical management is associated with high morbidity and mortality due to the complicated nature of this replacement procedure [12,13]. There have been few, if any, well-designed trials to study the use of

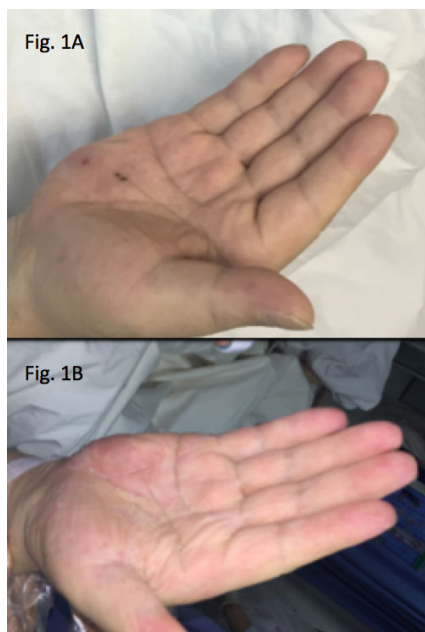
antimicrobial therapy alone in the treatment of prosthetic aortic graft infection. Surgical specialists carry out most studies, and antibiotic treatment is mentioned as an adjunct to operative intervention [5].

This case suggests that for some patients diagnosed with candidemia associated with prosthetic graft who are unwilling, or unfit for surgical intervention, can be managed conservatively with antifungal therapy alone. Though, in the course of our therapy, a microembolic incident occurred; the patient recovered rapidly, and the embolic material significantly disappeared without surgical intervention. A case report should not be used to recommend a therapeutic approach, but it can provide an example of another, successful, therapeutic choice.

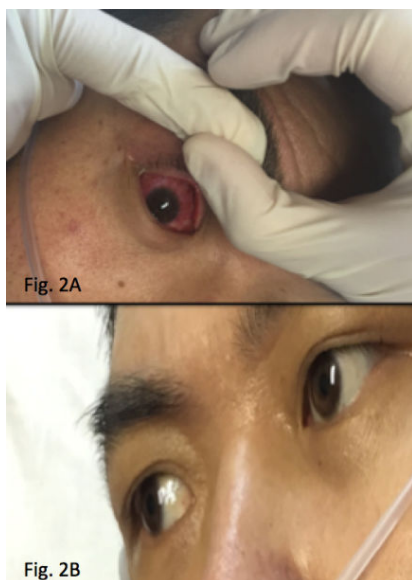### Case Presentation

A 44-year-old man with a past medical history of untreated hypertension presented to Peking University First Hospital with a chief complaint of fever (temperature of 104.5°F [40.3°C]) for 2 months. Seventeen months prior, he underwent prosthetic aortic graft and descending aortic stent-graft implantation due to a DeBakey Type I aortic dissection. Broad-spectrum antibiotics were administered for more than 1 month as empirical treatment for the fever, however he showed no improvement. Physical examination revealed painful, microembolic lesions at his right hypothenar eminence (Figure 1A), right conjunctival hyperemia (Figure 2A), right neural hearing loss, and a systolic murmur beginning from the aortic focus and radiating towards his neck. His white blood cell count was 8,700/mm<sup>3</sup> and serologic inflammatory marker, high sensitive C reactive protein (hs-CRP), was elevated to 71 mg/L. His Human Immunodeficiency Virus

(HIV) test was negative, and there was no evidence of intravenous drug abuse.



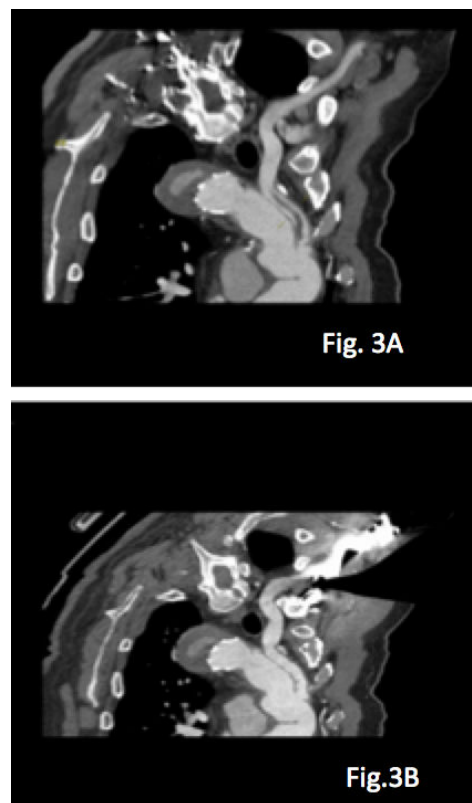
**Figure 1:** Photo of right hypothenar eminence before (1A) and after (1B) treatment with IV fluconazole.



**Figure 2:** Conjunctival Hyperemia before (2A) and after (2B) treatment with IV fluconazole.

*C. albicans* was then isolated from 3 separate blood cultures within 24 h. Antifungal sensitivity testing revealed full susceptibility to fluconazole, voriconazole, and amphotericin B. No evidence of endocarditis was found on transthoracic echocardiography. Due to the localization of the patient's signs on the upper, right part of his body,

we suspected the brachiocephalic artery to be the source of infection. CT showed distinct, adherent embolic material on the aortic prosthetic graft in the brachiocephalic artery (Figure 3A). Based on the patient's history, blood cultures, and imaging studies, he was diagnosed with *C. albicans* infection of the aortic prosthetic graft.

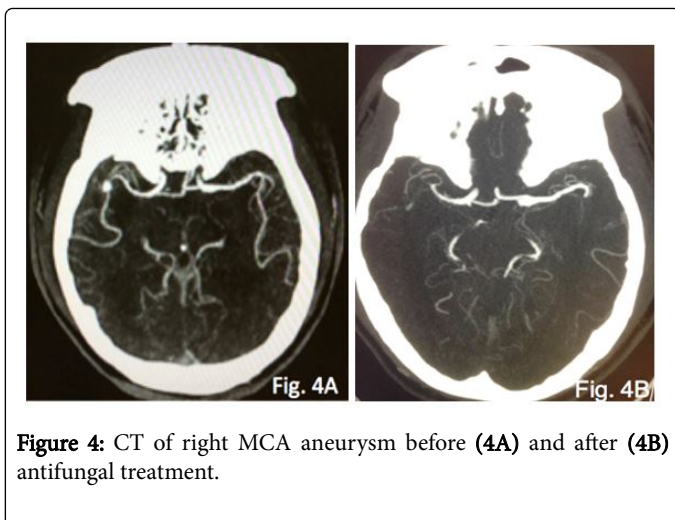


**Figure 3:** CT Scan demonstrating the size decrease before (3A) and after (3B) antifungal treatment.

Given the patient's high risk to benefit ratio of undergoing a surgical procedure, we opted for a more conservative approach: antifungal therapy. After 2 weeks of IV fluconazole treatment (600 mg/d, 7.5 mg/kg/d), his temperature declined to 98.6°F (37°C) and repetitive blood cultures remained negative for *C. albicans*. Significant improvement in conjunctival hyperemia (Figure 2B) as well as resolution of the microembolic lesions (Figure 1B) was also observed.

Of note, two weeks after admission the patient experienced sudden onset left limb hemiparesis. CT displayed an aneurism of the right middle cerebral artery (MCA) (Figure 4A), bleeding into his right frontal lobe, and infarction of his right temporal lobe. After another 4 weeks of IV fluconazole therapy (800 mg/d, 10 mg/kg/d), the patient presented no further clinical evidence of microembolism. The patient was discharged with the recommendation of lifelong antifungal therapy (oral fluconazole, 400 mg/d).

He was then followed for 12 months, remaining asymptomatic. On repeat CT at 4 months post treatment, the size of the embolism adherent to the aortic prosthetic graft at the brachiocephalic artery was decreased significantly (Figure 3B). Additionally, the aneurism in the right MCA also occluded (Figure 4B).



## Conclusion

This case demonstrates the importance of recognizing all microbes in a patient with a history of persistent fever and prosthetic graft placement. Currently, the literature data support surgical and antimicrobial therapy when approaching patients with aortic prosthetic graft infection. However, this case shows the possibility of recovery in patients with high risk to benefit ratio treated with conservative, antifungal treatment, if blood cultures are positive for *C. albicans*. There is need for further case studies and reports to further solidify this notion of conservative therapy as reliable treatment for patients with high risk of operative complications when dealing with candidemia and prosthetic grafts.

## Consent

The presented case entered the IRB approved consent of case presentation without personal health information was obtained.

## Acknowledgement

Special thanks given to Dr. Hongmei Jiao, who worked through the paper and gave instructive suggestions, and also thankful for Alexa Lean for revising this manuscript.

## References

1. Calligaro KD, Veith FJ (1991) Diagnosis and management of infected prosthetic aortic grafts. *Surgery* 110: 805-813.
2. Lyons OT, Baguneid M, Barwick TD, Bell RE, Foster N, et al. (2016) Diagnosis of Aortic Graft Infection: A Case Definition by the Management of Aortic Graft Infection Collaboration (MAGIC). *Eur J Vasc Endovasc Surg* 52: 758-763.
3. Mingoli A, Sapienza P, di Marzo L, Sgarzini G, Burchi C, et al. (1997) Management of abdominal prosthetic graft infection requiring emergent treatment. *Angiology* 48: 491-495.
4. Setacci C, Chisci E, Setacci F, Ercolini L, de Donato G, et al. (2014) How to diagnose and manage infected endografts after endovascular aneurysm repair. *Aorta (Stamford)* 2: 255-264.
5. FitzGerald SF, Kelly C, Humphreys H (2005) Diagnosis and treatment of prosthetic aortic graft infections: confusion and inconsistency in the absence of evidence or consensus. *J Antimicrob Chemother* 56: 996-999.
6. Cooley DA, Burnett CM (1993) Fungal infection in a dissecting aneurysm of the thoracic aorta. *Tex Heart Inst J* 20:51-54.
7. Bakoyiannis CN, Georgopoulos SE, Tsekouras NS, Klonaris CN, Papalambros EL, et al. (2007) Fungal infection of aortoiliac endograft: a case report and review of the literature. *Ann Vasc Surg* 21: 228-231.
8. Lawrence PF (1995) Management of infected aortic grafts. *Surg Clin North Am* 75: 783-797.
9. Valentine RJ (2001) Diagnosis and management of aortic graft infection. *Semin Vasc Surg* 14: 292-301.
10. Treska V, Certik B, Molacek J (2016) Management of aortic graft infections-the present strategy and future perspectives. *Bratislava Med J* 116: 125-132.
11. Kilic A, Arnaoutakis DJ, Reifsnnyder T, Black JH 3rd, Abularrage CJ, et al. (2016) Management of infected vascular grafts. *Vasc Med* 21: 53-60.
12. Erb S, Sidler JA, Elzi L, Gurke L, Battegay M, et al. (2014) Surgical and antimicrobial treatment of prosthetic vascular graft infections at different surgical sites: a retrospective study of treatment outcomes. *PLoS One* 9: e112947.
13. Smeds MR, Duncan AA, Harlander-Locke MP, Lawrence PF, Lyden S, et al. (2016) Treatment and outcomes of aortic endograft infection. *J Vasc Surg* 63: 332-340.