

## Case Report: Post-Operative Airway Obstruction in A Patient with Reinke's Edema

Alyson Russo, Ebony Blaize, Lynette Mark and C David Mintz\*

Department of Anesthesiology and Critical Care Medicine, Johns Hopkins Medical Institutes, Baltimore, USA

\*Corresponding author: C David Mintz, Department of Anesthesiology and Critical Care Medicine, Ross 370, 720 Rutland Ave, Johns Hopkins Medical Institutes, Baltimore, MD 21205, USA, Tel: 917-733-0422; E-mail: cmintz2@jhmi.org

Received date: March 27, 2017; Accepted date: April 08, 2017; Published date: April 14, 2017

Copyright: © 2017 Russo A, et al. This is an open-access article distributed under the terms of the Creative Commons Attribution License, which permits unrestricted use, distribution, and reproduction in any medium, provided the original author and source are credited.

### Abstract

Here we present the case of a 64 year old female with a history of neck radiation and Reinke's edema that experienced unexpected respiratory failure after a sedation anesthetic. After the case terminated, the patient was noted to be hypoventilating and stridorous. Mask ventilation, laryngeal mask airway ventilation, and direct laryngoscopy failed. The patient was intubated with video laryngoscopy. Reinke's edema, a benign lesion characterized by swelling of the vocal folds, was thought to contribute to the difficulty in ventilating and intubating this patient. We present a discussion of Reinke's edema and its potential relevance to the practice of anesthesia.

**Keywords:** Reinke's edema; Reinke's cyst; Airway obstruction

### Introduction

Reinke's edema is a swelling of the vocal folds that affects voice quality and can contribute to airway obstruction. The following case report argues that Reinke's edema can impede ventilation or intubation, and proposes that advanced airway tools should be readily available when anesthetizing a patient with Reinke's edema. An internal review board waiver was obtained prior to publication of this report.

### Pre-Anesthetic History

The patient, a 64-year-old female with a history of thyroid cancer, presented to the interventional radiology service for placement of a percutaneous endoscopic gastrostomy (PEG) tube. Other medical history included a remote 15 pack-year smoking history, migraines, and uncomplicated knee arthroscopy.

The patient presented in November 2015 with decreased vocal volume and left-sided vocal cord paralysis. A CT scan of her neck revealed a left-sided thyroid nodule, which when biopsied demonstrated papillary thyroid carcinoma. During pre-operative evaluation, "moderate edema of the vocal folds" was noted, consistent with Reinke's edema. The patient underwent a total thyroidectomy, neck dissection, and sacrifice of the left recurrent laryngeal nerve in March 2016. Post-operatively, she was monitored in the ICU secondary to stridor and vocal cord edema. Her stridor resolved without the need for intubation.

In April 2016, the patient presented with on-going hoarseness and was found to have "unilateral, complete left vocal cord paralysis." She received a Trans-oral vocal fold injection to augment the paretic vocal fold and improve phonation. Radiation therapy for her thyroid cancer commenced in May 2016, but she soon developed pain with swallowing, as well as nausea, decreased appetite, and weight loss. She was referred for PEG tube placement to help meet her nutritional needs.

### Anesthetic Course

A preoperative exam revealed a grossly normal, Mallampati class II airway with a three finger-breath thyromental distance. Previous anesthetic records indicated easy mask ventilation and intubation with a Macintosh 3 blade and a grade I view of the vocal cords.

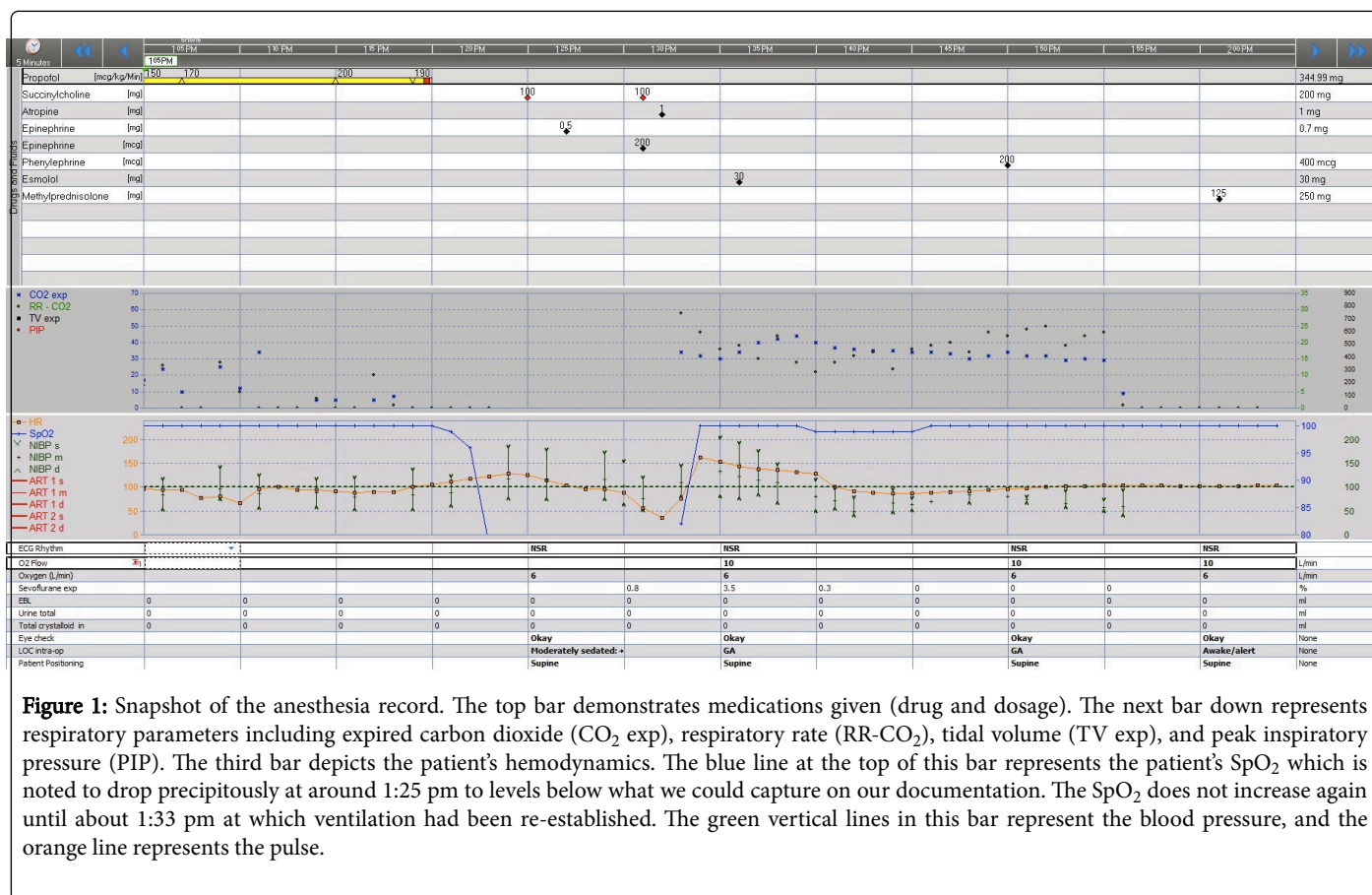
The anesthetic plan consisted of propofol sedation, with supplemental midazolam and fentanyl as needed. Standard monitors were used during the procedure. Supplemental oxygen was provided through a facemask and a propofol infusion was initiated. Two bolus doses of fentanyl (total 50 mcg) and one bolus dose of midazolam (total 1 mg) were given intraoperatively. Oxygen saturation remained at or near 100% throughout the procedure. After successful PEG placement, the propofol infusion was discontinued and the patient began to regain consciousness.

While preparing for transfer to the recovery room, a reduction in chest rise, decrease in mask fogging, and a loss of capnography tracing was appreciated. The facemask used during sedation was replaced with a mask connected to an anesthesia circuit to deliver 100% oxygen, and the patient's head was repositioned to help relieve possible airway obstruction. Hypoventilation progressed and stridorous breath sounds were appreciated. Working on a presumptive diagnosis of laryngospasm, the anesthesiologist called for help, placed an oropharyngeal airway, and attempted to mask ventilate using a jaw thrust maneuver, but was unsuccessful. The oxygen saturation rapidly dropped below 60% and the patient lost consciousness. At that point, an intubating dose of succinylcholine was given to facilitate ventilation or enable rapid progression to endotracheal intubation. No improvement in ventilation was noted, so direct laryngoscopy with a Miller 2 blade was attempted. The epiglottis was easily displaced, but the anesthesiologist could not identify vocal cords or a clear glottic opening.

A second anesthesiologist then attempted mask ventilation without success. An LMA was placed, and appeared to seat appropriately, but there was a negligible waveform on capnography with ventilation attempts, no evidence of adequate tidal volumes, and no improvement of the patient's oxygen saturation or mental status. An intramuscular

dose of 500 mcg of epinephrine was then given to treat presumptive bronchospasm, and another 200 mcg of epinephrine was given intravenously to treat bradycardia. A second dose of succinylcholine was given intravenously to facilitate a second attempt at endotracheal intubation with a video laryngoscope. The vocal cords were deviated to the left and a partial view of the right vocal cord and glottic opening was recognizable. An endotracheal tube was placed and end-tidal capnometry, chest rise and adequate tidal volumes were appreciated. During this time 1mg of atropine was administered intravenously to further treat bradycardia. Oxygen saturation rapidly improved with restoration of ventilation.

The patient was transported to the medical intensive care unit (MICU) for further respiratory monitoring. Prior to extubation, the patient completed a basic neurologic examination and followed commands appropriately. She was given intravenous dexamethasone and methylprednisolone to mitigate any swelling from the intubation attempts. Fiberoptic evaluation of her glottis in the MICU by the otolaryngology service demonstrated “watery, right arytenoid swelling with hooding” and “left vocal cord paralysis.” Her ICU course was uncomplicated and she was discharged home after 2 days Figure 1.



**Figure 1:** Snapshot of the anesthesia record. The top bar demonstrates medications given (drug and dosage). The next bar down represents respiratory parameters including expired carbon dioxide (CO<sub>2</sub> exp), respiratory rate (RR-CO<sub>2</sub>), tidal volume (TV exp), and peak inspiratory pressure (PIP). The third bar depicts the patient's hemodynamics. The blue line at the top of this bar represents the patient's SpO<sub>2</sub> which is noted to drop precipitously at around 1:25 pm to levels below what we could capture on our documentation. The SpO<sub>2</sub> does not increase again until about 1:33 pm at which ventilation had been re-established. The green vertical lines in this bar represent the blood pressure, and the orange line represents the pulse.

## Discussion

The difficulty encountered in ventilating this patient put her at substantial risk for hypoxic brain injury. Her complex history of airway surgery and neck radiation likely contributed to the abnormal appearance of her glottic structures, but it is hard to explain why two experienced anesthesiologists were unable to achieve mask ventilation. In this case, it is difficult to fully rule out severe bronchospasm below the level of the vocal cords, but the patient did not have any prior history of reactive airway disease, and treatment with epinephrine did not improve attempts to ventilate, making this diagnosis unlikely. Upper airway obstruction, such as by laryngospasm, is one of the most common reasons for difficult ventilation, but standard techniques to relieve laryngospasm all failed in this case. Finally, given the patient's history of unilateral vocal cord paralysis we deem severe laryngospasm by itself to be unlikely to fully explain the failed ventilation.

Thus we conclude that obstruction at the level of the vocal cords is the most likely explanation and propose that the patient's history of Reinke's edema may have contributed.

Reinke's edema, also known as Reinke's cyst, is described as a histologically benign lesion with swelling of the superficial layer of the lamina propria on the vocal folds [1-3]. It can present as unilateral or bilateral swelling, leading to a decrease in vocal pitch, hoarseness, dysphonia, or airway compromise [2,4]. The condition is most commonly diagnosed in women, who present with more profound voice changes than men [5]. Reinke's edema has an association with smoking, excessive vocal strain, and laryngo-pharyngeal reflux disease [2,3]. Its strong association with smoking is thought to be related to increased vascular permeability from the chemicals found in cigarettes [6-8]. Once a patient develops symptoms, the diagnosis is made by direct inspection of the vocal folds. Patients are counseled to avoid smoking and are sometimes started on proton pump inhibitors to decrease the degree of reflux [2]. Smoking cessation not known to

reverse the disease once present, but can halt disease progression or prevent recurrence if a patient has surgical intervention [2,7]. Voice therapy is also utilized to reduce further strain or damage to the vocal cords. Surgical intervention is usually a last line in therapy [2].

Based on our experience with this patient, we propose that Reinke's edema has the potential to complicate ventilation. The swelling could cause a physical obstruction to air flow between the upper airway and the trachea, which would be resistant to muscle relaxation and jaw lift maneuvers that are usually effective in laryngospasm. We believe that further study of any correlation between difficult airway management and the presence of Reinke's edema is warranted. In the interim, we recommend anesthesia providers proceed with caution and have tools for advanced airway management immediately available when caring for patients with Reinke's edema.

### Conflicts of Interest

None

### References

1. Rosen CA (2006) Benign vocal fold lesions and phonosurgery: In: Bailey B, Johnson J, Newlands S, ed. *Head and Neck Surgery-Otolaryngology*. (4th edn). Philadelphia, PA: Lippincott-Raven 840.
2. Bohlender J (2013) Diagnostic and therapeutic pitfalls in benign vocal fold diseases. *GMS Curr Top Otorhinolaryngol Head Neck Surg* 12: Doc01.
3. Goswami S, Patra TK (2003) A Clinico-pathological studies of Reinke's oedema. *Indian J Otolaryngol Head Neck Surg* 55: 160-165.
4. Zeitels S, Casiano R, Gardner G, Hogikyan N, Koufman J, et al. (2002) Management of common voice problems: Committee report. *Otolaryngol Head Neck Surg* 126: 333-348.
5. Rubin JS, Yanagisawa E (2014) Benign vocal fold pathology through the eyes of the laryngologist. In: *Diagnosis and Treatment of Voice Disorders*. (4th edn). San Diego, CA: Plural Publishing 2014: 104.
6. Martins R, Tavares E, Pessin A (2016) Are vocal alterations caused by smoking in Reinke's edema in women entirely reversible after microsurgery and smoking cessation? *J Voice* S0892-1997(16)30115-1.
7. Rosen C, Simpson B (2008) Polypoid Corditis. In: *Operative Techniques in Laryngology*. Berlin, Germany: Springer-Verlag Berlin Heidelberg 113.
8. Jovanovic M, Mulutinovic Z, Perovic J, Grubor A, Milenkovic S, et al. (2007) Contact telescoping reveals blood vessel alterations of vocal fold mucosa in Reinke's edema. *J Voice* 21: 366-360.