

## Caspase-12 as a Biomarker of Aquatic Pollution in *Oreochromis niloticus*

Soha M Hamdy<sup>1</sup>, Amany M Shaban<sup>1\*</sup>, Amany A Mahmoud<sup>2</sup>, Nahed S Gad<sup>3</sup> and Wael A Ibrahim<sup>1</sup>

<sup>1</sup>Chemistry Department, Faculty of Science, El Fayoum University, El- Fayoum, Egypt

<sup>2</sup>Biochemistry Department, Research Institute of Ophthalmology, Egypt

<sup>3</sup>Pollution Department, National Institute of Oceanography and Fisheries, Egypt

\*Corresponding author: Amany M Shaban, Faculty of Science, Fayoum University, Egypt, Tel: 00201147511575; E-mail: [amm11@fayoum.edu.eg](mailto:amm11@fayoum.edu.eg)

Received date: September 22, 2016; Accepted date: October 15, 2016; Published date: October 22, 2016

Copyright: © 2016 Hamdy SM, et al. This is an open-access article distributed under the terms of the Creative Commons Attribution License, which permits unrestricted use, distribution and reproduction in any medium, provided the original author and source are credited.

### Abstract

Biomarkers have recently been used in studies of aquatic environment. Here we present data on stress related bio-markers in *Oreochromis niloticus* (Nile tilapia) as indicators of aquatic pollution. The samples of study were collected from contaminated aquatic habitats (Qaroun Lake and its neighboring fish farm), in comparison with the reference site. Heavy metal concentrations as Fe, Mn, Zn, Cu and Cd were determined in the water and the fish tissues. Oxidative stress biomarkers (Malondialdehyde, reduced glutathione, glutathione S transferase and catalase) together with endoplasmic reticulum stress biomarker (Caspase-12) were determined in both the plasma and the tissue samples. Histopathological examination of kidney and muscles with SDS electrophoresis of muscle proteins were used to study the influence of pollution on Nile tilapia. Heavy metal concentrations of water and tissue samples from contaminated habitats were significantly higher than the reference site. A highly significant difference in stress related biomarkers was recorded in the fish from contaminated habitats. Histopathological modulations and disrepairs were observed in fish tissues collected from contaminated habitats. Results have shown differences in banding pattern of muscle proteins of Nile tilapia collected from polluted sites. These results provide evidence that caspase-12 is a useful biomarker for aquatic pollutions.

**Keywords:** Biomarkers; Oxidative stress; Endoplasmic reticulum stress; Hypoxia; *Oreochromis niloticus*

### Introduction

The extreme contamination of aquatic habitats has become a major environmental and health problem worldwide [1]. Aquatic ecosystems are subjected to many environmental contaminants, so a set of biomarkers was determined to assess the biological effects [2].

In recent years, the environmental contamination by metals was proved [3-6]. Metals were contaminants due to their toxicity and its bioaccumulation in aquatic organisms [7].

The endoplasmic reticulum (ER) is the organelle with a central role in the control of biologically active proteins [8]. Accumulation of inactive proteins in the ER has led to ER stress that induces the unfolded protein response (UPR) [9]. The target of the UPR is to facilitate adaptation of the cells to environmental changes and to re-establish normal ER functions [10]. When severe ER stress extensively impairs the ER functions, apoptosis is necessary not only for removing the cells that threaten the integrity of the organism, but also for development and differentiation. One of the apoptotic pathways depends on the activation of ER-localized cysteine protease, caspase-12 [11]. Caspase-12 then initiates a caspase cascade culminating in apoptosis and cell death.

The aim of this study is to evaluate the toxic effects of environmental pollutants using caspase-12 in *O. niloticus* along contaminated water of both Qaroun Lake and the neighbouring fish farm, compared with a model fish farm that irrigated with fresh water from the river Nile.

### Materials and Methods

#### Sites of collection

A total of 72 fish of Nile tilapia, *Oreochromis niloticus* (24 fish/site) were collected from the following sites:

**Site 1:** The reference site: Fish farm of the Faculty of Agriculture, Fayoum University: Irrigated with fresh water from the river Nile.

**Site 2:** The fish farm at Qaroun Lake: This farm depends on agricultural drainage water.

**Site 3:** Qaroun Lake at the outlet of El-Wadi drainage canal, which receives agricultural and sewage drainage water from Fayoum province.

#### Water and fish sampling

Water samples were collected approximately 50 cm below the water surface. Blood samples of fish were withdrawn from the arteria caudales; some were collected in EDTA treated tubes; the plasma obtained were used for the determination of Reduced glutathione, Glutathione S transferase (GST), Catalase, malondialdehyde (MDA) and caspase-12. While serum samples were used for the determination of alanine aminotransferase (ALT), aspartate aminotransferase (AST) and total protein. Serum was also subjected to SDS electrophoresis.

Each fish sample collected was dissected for its kidney and muscles. Muscle tissues were dissected from the region between the pelvic and dorsal fins. For biochemical analysis, tissues were homogenized with a PBS (phosphate buffered saline, pH 7.4).

## Chemical analysis

**Heavy metal determination in water:** Total Fe, Mn, Zn, Cu and Cd in water samples were detected using GBC atomic absorption spectrophotometer (Savanta AA) after adding nitric acid as digestion technique (APHA [12]).

**Residual heavy metals determination:** All tissues were dried at 105°C until reaching to a constant weight. Then 1g of each dry tissue was digested using the method of Goldberg et al. [13]. The concentrations of Fe, Mn, Zn, Cu and Cd in all tissues were measured by atomic absorption spectrophotometer (GBC, savanta AA). Results were expressed in mg/Kg dry weight of the tissue.

## Biochemical analysis

Reduced glutathione (GSH) was determined according to Beutler et al. [14]. Glutathione S transferase (GST) was measured according to Habig et al. [15]. Catalase was determined according to Aebi [16]. Malondialdehyde (MDA) was measured according to Satoh and Ohkawa et al. [17,18]. Caspase-12 was also determined using ELISA Kit from My BioSource.

## SDS-PAGE

SDS gel electrophoresis of serum and muscle proteins was done according to Laemmli [19].

## Histological examination

After dissecting kidney and muscle tissues of the fish, the tissues were fixed in Bouin's solution for 24 h. The tissues were dehydrated in an ascending series of alcohol, cleared in xylene and embedded in paraffin wax. Sections of 4-6 µm thick were cut, processed, and stained with hematoxylin and eosin (H & E). They were examined under a complex Olympus light microscope and photographed by a builtin camera.

## Statistical Analysis

The analysis was done using the statistical package for the social science (SPSS. Version 16.0, Chicago, IL, USA); all results were expressed as the mean ± S.D. The data were analyzed by one way analysis of variance (ANOVA). To compare the difference among the groups, post hoc testing was performed by the least significant difference (LSD). The  $P \geq 0.05$  was considered statistically significant.

## Results

### Water analysis

	Site 1 (Reference site)	Site 2 (Qaroun fish farm)	Site 3 (Qaroun Lake)
Fe	0.26 ± 0.07	1.73 ± 0.07*	2.33 ± 0.14*
Mn	0.05 ± 0.005	0.29 ± 0.023*	0.50 ± 0.061*
Zn	0.032 ± 0.004	0.32 ± 0.054*	0.48 ± 0.045*
Cu	0.084 ± 0.007	0.42 ± 0.07*	0.68 ± 0.06*
Cd	0.029 ± 0.002	0.256 ± 0.05*	0.468 ± 0.04*

**Table 1:** Heavy metals concentrations (mg/L) in water samples collected from different studied sites (\* $P < 0.001$  vs. the reference site).

**Concentrations of heavy metals in water:** The concentrations of Fe, Mn, Zn, Cu and Cd in water collected from site 2 and site 3 were significantly higher ( $P < 0.001$ ) than the samples collected from reference site (Table 1).

## Tissue analysis

### Residual heavy metals

**Heavy metals in kidney:** The concentrations of iron, manganese, zinc, copper, and cadmium in kidney tissues of fish were collected from different sites. A highly significant increase ( $p < 0.001$ ) in heavy metals concentrations was reported in kidney tissues of fish from site 2 and site 3 compared to the reference site. Fish from site 3 have shown a significant elevation in iron ( $p < 0.05$ ), manganese ( $p < 0.001$ ), zinc ( $p < 0.05$ ), copper ( $p < 0.05$ ), and cadmium ( $p < 0.05$ ) when compared to site 2 (Table 2).

	Site 1 (Reference site)	Site 2 (Qaroun fish farm)	Site 3 (Qaroun Lake)
Fe	5.0 ± 0.45	73 ± 5.5*	91 ± 4.0*
Mn	1.5 ± 0.3	18.1 ± 0.7*	24.2 ± 1.0*
Zn	13.5 ± 0.4	102 ± 10.5*	132 ± 6.1*
Cu	2.4 ± 0.55	37.3 ± 4.9*	47 ± 2.6*
Cd	1.06 ± 0.05	5 ± 0.47*	6.6 ± 0.62*

**Table 2:** Heavy metals concentrations (mg/kg dry weight) in liver tissues of *Oreochromis niloticus* collected from the investigated sites (\* $P < 0.001$  vs. the reference site).

**Heavy metals in muscles:** The concentrations of heavy metals in muscles revealed a highly significant increase ( $p < 0.001$ ) in case of fish from site 2 (except for Cd that showed a significant increase ( $p < 0.05$ )) and site 3 when compared to reference site. Fish from site 3 have shown a significant elevation in iron ( $p < 0.001$ ), manganese ( $p < 0.05$ ), zinc ( $p < 0.001$ ), copper ( $p < 0.05$ ), and cadmium ( $p < 0.05$ ) when compared to site 2 (Table 3).

	Site 1 (Reference site)	Site 2 (Qaroun fish farm)	Site 3 (Qaroun Lake)
Fe	5.0 ± 0.45	73 ± 5.5*	91 ± 4.0*
Mn	1.5 ± 0.3	18.1 ± 0.7*	24.2 ± 1.0*
Zn	13.5 ± 0.4	102 ± 10.5*	132 ± 6.1*
Cu	2.4 ± 0.55	37.3 ± 4.9*	47 ± 2.6*
Cd	1.06 ± 0.05	5 ± 0.47*	6.6 ± 0.62*

**Table 3:** Heavy metals concentrations (mg/kg dry weight) in muscle tissues of *Oreochromis niloticus* collected from the investigated sites (\*\* $P < 0.05$ , \* $P < 0.001$  vs. the reference site).

### Stress related biomarkers

**Stress related biomarkers in kidney:** Table 4 has shown that a highly significant increase ( $p < 0.001$ ) in MDA, GSH, GST and caspase-12 together with a highly significant decrease ( $p < 0.001$ ) in catalase activity that was recorded in kidney tissues of fish from site 2 and site 3 when compared to the reference site.

	Site 1 (Reference site)	Site 2 (Qaroun fish farm)	Site 3 (Qaroun Lake)
MDA (nmol/g tissue)	307 ± 18.1	414 ± 14.2*	749 ± 21.3*
GSH (mmol/g tissue)	0.55 ± 0.10	1.23 ± 0.1*	1.79 ± 0.14*
GST (U/g tissue)	36.1 ± 2.4	1.23 ± 0.1*	71.5 ± 3.7*
Catalase (U/g tissue)	45.8 ± 3.8	33.6 ± 2.1*	23.0 ± 2.4*
Caspase-12 (ng/g tissue)	28.4 ± 2.1	66.5 ± 4.4*	83.6 ± 4.5*

**Table 4:** Levels of MDA, GSH, GST, catalase and caspase-12 in kidney tissues of fish collected from different studied site (\* $P < 0.001$  vs. the reference site).

**Stress related biomarkers in muscles:** A significant elevation in MDA ( $p < 0.05$ ), GSH ( $p < 0.05$ ), GST ( $p < 0.05$ ) and caspase-12 ( $p < 0.001$ ) together with a highly significant reduction ( $p < 0.001$ ) in catalase activity were reported in muscle tissues of fish collected from site 2 when compared to the reference site.

	Site 1 (Reference site)	Site 2 (Qaroun fish farm)	Site 3 (Qaroun Lake)
MDA (nmol/g tissue)	178 ± 25.1	208 ± 25.8**	476 ± 20.8*
GSH (mmol/g tissue)	0.41 ± 0.03	0.92 ± 0.05**	1.37 ± 0.18*
GST (U/g tissue)	22.2 ± 2.4	36.8 ± 2.8**	57.9 ± 5.5*
Catalase (U/g tissue)	29.4 ± 1.3	19.6 ± 1.8*	11.0 ± 1.4*
Caspase-12 (ng/g tissue)	1.2 ± 0.43	7.2 ± 0.64*	10.1 ± 0.87*

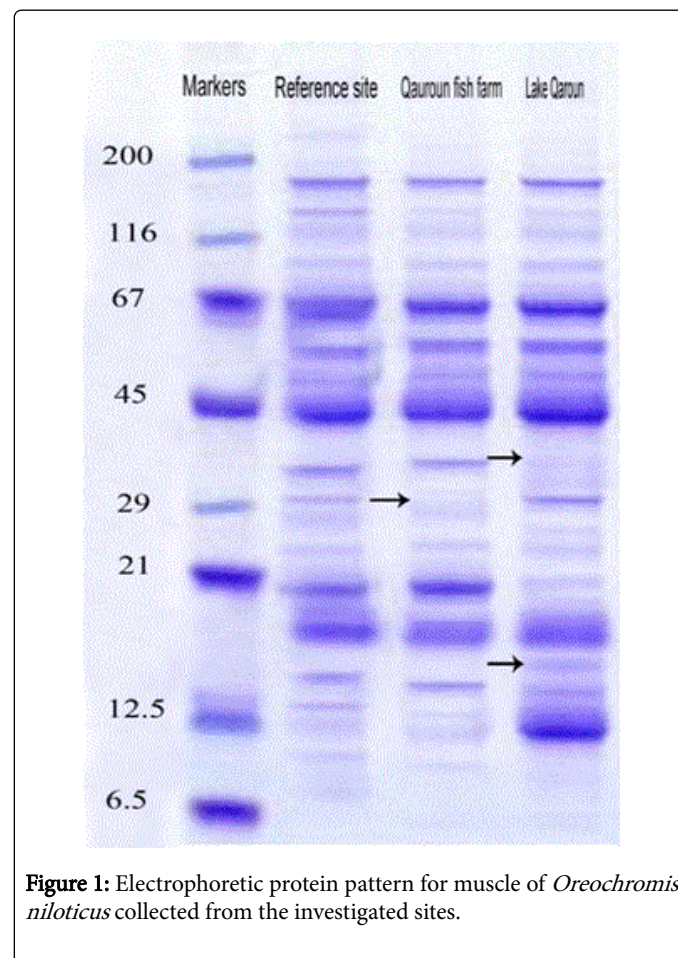
**Table 5:** Levels of MDA, GSH, GST, catalase, caspase-12 and VEGF in muscle tissues of fish collected from different studied site (\*\* $P < 0.05$ , \* $P < 0.001$  vs. reference site).

Moreover, fish from site 3 have shown a highly significant increase ( $p < 0.001$ ) in MDA, GSH, GST and caspase-12 and a highly significant decrease ( $p < 0.001$ ) in catalase activity compared to reference site (Table 5).

### SDS gel electrophoresis of muscles

Protein pattern of muscles of fish, *O. niloticus* collected from different sites is shown in Figure 1. Site 2 samples exhibit the

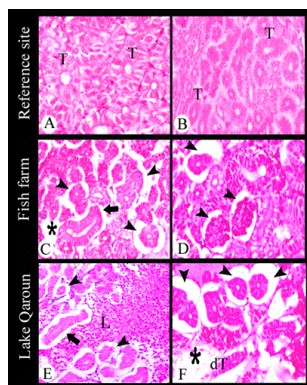
disappearance of one band at molecular weight of 29 kDa compared to the reference site. Samples of site 3 have shown a disappearance of one band in between molecular weights of 29 kDa and 45 kDa compared to the reference site. Formation of one extra band in between molecular weights of 12.5 kDa and 21 kDa was observed in site 3 samples compared to the reference site.



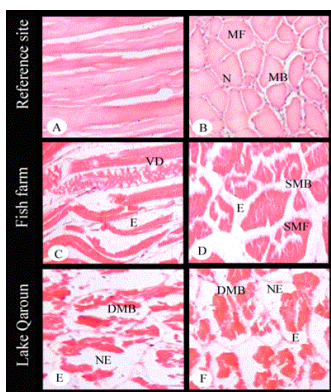
**Figure 1:** Electrophoretic protein pattern for muscle of *Oreochromis niloticus* collected from the investigated sites.

### Histopathological observations

**Histopathological observations of kidney:** Fish collected from reference site exhibited normal kidney tubules (renal parenchyma) and a normal hematopoietic interstitial (intertubular) tissue surrounding the tubules (Figures 2A and 2B). The posterior kidney of the fish collected from site 2 has shown different degrees of glomerular shrinkage (Figures 2C and 2D). Some tubular epithelial cells were separated from the basement membrane resulting from edema (Figure 2C). A necrotic foci in-between tissue parenchyma was clearly visible (Figure 2C). The posterior kidney of the fish collected from site 3 has shown different degrees of glomerular shrinkage (Figures 2E and 2F). Some tubular epithelial cells were separated from the basement membrane resulting from edema (Figure 2E). Leukocyte infiltration was noted (Figure 2E). Necrotic foci also represented a tubular degeneration in-between tissue parenchyma which was clearly visible (Figure 2F). Cloudy swelling (Also termed albuminous degeneration) became an evident alteration of tubular epithelial cells, resulting in loss of shape with a granular cytoplasm (Figure 2F).



**Figure 2:** Sections in posterior kidney of *Oreochromis niloticus* from (A&B) the reference site, (C&D) site 2, (E&F) site 3. A & B tubules (T), C) different degrees of glomerular shrinkage (arrowhead), tubular epithelial cells were separated from the basement membrane resulting from edema (thick arrow) and necrotic foci (asterisk), D) different degrees of glomerular shrinkage (arrowhead), E) different degrees of glomerular shrinkage (arrowhead), tubular epithelial cells separated from the basement membrane resulting from edema (thick arrow) and mononuclear leukocyte infiltration (L), F) different degrees of glomerular shrinkage (arrowhead), necrotic foci with cloudy swelling (asterisk), and tubular degeneration (dT).



**Figure 3:** Sections in muscle of *Oreochromis niloticus* stained with hematoxylin and eosin. A) L.S. of muscle of fish from the reference site, B) T.S. of muscle of fish from the reference site showing muscle bundle (MB), muscle fiber (MF) and nuclei (N), C) L.S. of muscle of fish from site 2 showing edema in-between muscle bundles (E) and vacuolar degeneration in muscle bundles (VD), D) T.S. of muscle of fish from site 2 showing edema in-between muscle bundles (E), splitting of muscle fibers (SMF) and shortening of muscle bundles (SMB). E) L.S. of muscle of fish from site 3 showing necrosis (NE) and degeneration of muscle bundles (DMB). F) T.S. of muscle of fish from site 3 showing edema in-between muscle bundles (DMF), necrosis (NE) and degeneration of muscle bundles (DMB).

**Histopathological observations of muscles:** The muscle of fish from reference site has shown the normal arrangement of muscle fibers and muscle bundles with nucleus at the periphery of fibers (Figures 3A and

3B). Sections of fish muscle from site 2 have shown some remarkable changes like vacuolar degeneration in muscle bundles, edema in-between muscle bundles, splitting of muscle fibers and shortening of muscle bundles (Figures 3C and 3D). The muscle of site 3 fish has shown edema in-between muscle bundles, necrosis, and complete degeneration of muscle bundles (Figures 3E and 3F).

## Discussion

Heavy metals are of the most important pollutants due to their toxicity [20]. In the current study, the source of heavy metals in sites 2 and 3 are from agricultural and sewage drainage water. Also, the Lake is a closed basin, so the accumulation of chemical pollutants is expected, especially during summer seasons. This agrees with Authman and Abbas [21].

The amount of contaminants accumulated in aquatic organisms depends both on its uptake and elimination rates [22]. In the present study, the highest concentrations of the different heavy metals were found in fish collected from sites 2 and 3 and this is in agreement with Omar et al. [23].

In the current study, the response of *O. niloticus* to pollutants was evaluated using various oxidative stress biomarkers that are termed bio-indicators of aquatic pollution. A significant increase in lipid peroxidation of kidney and muscles of fish from sites 2 and 3 was observed in the present study. This agrees with Farombi et al. [24] who stated that this increase in lipid peroxidation may be due to bioaccumulation of heavy metals in the organs of the fish.

In fish from sites 2 and 3, the activities of GST and GSH were significantly elevated in kidney and muscle. This increase may be attributed to oxidative stress caused by heavy metals. Our results agree with that reported by Pandey et al. and Mahboob et al. [25,26].

In this study, the activity of catalase decreased in the studied tissues of fish from sites 2 and 3 [27] stated that the decrease in catalase activity may be attributed to the flow of superoxide radicals, which may inhibit catalase activity. Similar findings in connection with the activity of catalase have been reported by Mahboob et al. [26].

Caspase-12 is a molecule that is related to ER stress-induced apoptosis pathways (Shibata et al. [28]). In this study, the level of caspase-12 was significantly high in kidney and muscle of fish collected from sites 2 and 3. This agrees with several studies which reported that heavy metals interfere with protein folding *in vivo*, so affect protein homeostasis and cause ER stress [29-32].

In the present study, the protein electrophoresis showed a high difference between reference and contaminated samples. This agrees with El-Bermawy et al. [33] who concluded that this difference is attributed to the production of a new DNA sequence which synthesizes new protein bands. Our study also agrees with several studies which reported that the disappearance of bands was proved under the action of pollution [34,35].

Histopathological changes can be used as indicators in evaluation of the health of fish subjected to contaminants [36]. In our study, the common alteration found in the kidney of fish collected from sites 2 and 3 was glomerular shrinkage and necrosis. Tubular epithelial cell is separated from basement membrane resulting from edema. This agrees with Zaghoul et al. [37] who study other fish species (*Solea aegyptiaca*). These results prove that the contamination with heavy-

metal changes the structural and functional characteristics of fish kidney.

In the present study, tubular degeneration and mononuclear leucocyte infiltration were observed only in the kidney of site 3 fish. This agrees with Velma and Tchounwou [38] who concluded that this degeneration may be due to the accumulation of inflammatory cells caused by metal toxicity. The cloudy swelling implied in site 3 grows to be an apparent change of tubular epithelial cells. Similar lesion was reported by Camargo and Martinez [39].

In the present study, clear histopathological changes appeared in the fish muscle of both sites 2 and 3, though with high degree in the later one. Fish from site 2 showed edema in-between muscle bundles, splitting of muscle fibers, shortening of muscle bundles and vacuolar degeneration in muscle bundles. On the other hand, Fish from site 3 have shown edema, necrosis and degeneration of muscle bundles. Similar results by other studies [36,40-43] stated that the fish exposed to the heavy metals reflect histological alterations in muscle.

The histopathological atrophy was observed in kidney and muscle of fish collected from sites 2 and 3. This agrees with the results of Omar et al. [23], which suggest too slow defense mechanisms in these tissues to eliminate heavy metals and also shows the sensitivity of fish cells to metal exposure.

In conclusion, the contamination of aquatic habitats with heavy metals was a serious problem, as revealed by the high metal concentrations in water and tissue samples. The concentrations of heavy metals may soon reach a dangerous level affecting the health of local human communities. Application of protein electrophoresis, histopathological, and stress biomarkers provide important indicators in monitoring studies and in comparing different levels of pollution as well. Additionally, this study is considered to be the first that used one of the ER stress biomarkers (Caspase-12) as a powerful monitoring tool for the assessment of aquatic pollution.

## References

- McNeil DG, Fredberg J (2011) Environmental water requirements of native fishes in the middle river catchment, Kangaroo Island, South Australia. A report to the SA department for water. SARDI research report series, Adelaide.
- Viarengo A, Lowe D, Bolognesi C, Fabbri E, Koehler A (2007) The Use of biomarkers in biomonitoring: a 2-tier approach assessing the level of pollutant induced stress syndrome in sentinel organisms. Comp Biochem Physiol C Toxicol Pharmacol 146: 281-300.
- Malik N, Biswas AK, Qureshi TA, Borana K, Virha R (2010) Bioaccumulation of heavy metals in fish tissues of a freshwater Lake of Bhopal. Environ Monit Assess 160: 267-276.
- Aktar MW, Sengupta D, Chowdhury A (2011) Occurrence of heavy metals in fish: a study for impact assessment in industry prone aquatic environment around Kolkata in India. Environ Monit Assess 181: 51-61.
- Qadir A, Malik RN (2011) Heavy metals in eight edible fish species from two polluted tributaries (Aik and Palkhu) of the River Chenab, Pakistan. Biol Trace Elem Res 143: 1524-1540.
- Maceda-Veiga A, Monroy M, de Sostoa A (2012) Metal bioaccumulation in the Mediterranean barbell (*Barbus meridionalis*) in a Mediterranean River receiving effluents from urban and industrial waste water treatment plants. Ecotoxicol Environ Saf 76: 93-101.
- Mohammadi M, Sary AA, Khodadadi M (2011) Determination of heavy metals in two barbs, *Barbus grypus* and *Barbus xanthopterus* in Karoon and Dez Rivers, Khoozestan, Iran. Bull Environ Contam Toxicol 87: 158-162.
- Ron D, Walter P (2007) Signal integration in the endoplasmic reticulum unfolded protein response. Nat Rev Mol Cell Biol 8: 519-529.
- Schroder M, Kaufman RJ (2005) The Mammalian unfolded protein response. Annu Rev Biochem 74: 739-789.
- Inagi R (2010) Endoplasmic reticulum stress as a progression factor for kidney injury. Curr Opin Pharmacol 10: 156-165.
- Nakagawa T, Zhu H, Morishima N, Li E, Xu J, et al. (2000) Caspase-12 mediates endoplasmic reticulum-specific apoptosis and cytotoxicity by amyloid-beta. Nature 403: 98-103.
- American Public Health Association (APHA) (2002) Standard methods of the examination of water and waste water, New York, p: 1193.
- Goldberg ED, Koide M, Hodge V, Flegel AR, Martin J (1993) U S mussel watch: 1977-1978 results on trace metals and radionuclides. Estuar Coastal Shelf Sci 16: 69-93.
- Beutler E, Duron O, Kelly BM (1963) Improved method for the determination of blood glutathione. J Lab Clin Med 61: 882-888.
- Habig WH, Pabst MJ, Jakoby WB (1974) Glutathione S- transferases The first enzymatic step in mercapturic acid formation. J Biol Chem 249: 7130-7139.
- Aebi H (1984) Catalase *in vitro*. Methods Enzymol 105: 121-126.
- Satoh K (1978) Serum lipid peroxide in cerebrovascular disorders determined by a new colorimetric method. Clinica Chimica Acta 90: 37-43.
- Ohkawa H, Ohishi N, Yagi K (1979) Assay for lipid peroxides in animal tissues by thiobarbituric acid reaction. Anal Biochem 95: 351-358.
- Laemmli UK (1970) Cleavage of structural proteins during the assembly of the head of bacteriophage T4. Nature 227: 680-685.
- Aanand S, Purushothaman CS, Pal AK, Rajendran KV (2010) Toxicological studies on the effect of copper, lead, and zinc on selected enzymes in the adductor muscle and intestinal diverticula of the green mussel *Perna viridis*. Ind J Mar Sci 39: 299-302.
- Authman MMN, Abbas HHH (2007) Accumulation and distribution of copper and zinc in both water and some vital tissues of two fish species (*Tilapia zillii* and *Mugil cephalus*) of Lake Qarun, Fayoum Province, Egypt. Pak J Biol Sci 10: 2106-2122.
- Koca YBM, Koca S, Yildiz S, Gurcu B, Osanc E, et al. (2005) Investigation of histopathological and cytogenetic effects on *Lepomis gibbosus* (Pisces: Perciformes) in the Cine stream (Aydin/Turkey) with determination of water pollution. Environ Toxicol 20: 560-571.
- Omar WA, Zaghoul KH, Abdel-Khalek A, Abo-Hegab S (2013) Risk assessment and toxic effects of metal pollution in two cultured and wild fish species from highly degraded aquatic habitats. Arch Environ Contam Toxicol 65: 753-64.
- Farombi EO, Adelowo OA, Ajimoko YR (2007) Biomarkers of Oxidative Stress and Heavy Metal Levels as Indicators of Environmental Pollution in African Cat Fish (*Clarias gariepinus*) from Nigeria Ogun River. Int J Environ Res Public Health 4: 158-216.
- Pandey S, Parvez S, Sayeed I, Haque R, Bin-Hafeez B, et al. (2003) Biomarkers of oxidative stress: a comparative study of river Yamuna fish *Wallago attu* (Bl & Schn). Sci Total Environ 309: 105-115.
- Mahboob S, Alkahem Al-Balawi HF, Al-Misned F, Al-Ghanimand KA, et al. (2014) An evaluation of water pollution in the wadi hanefah, a natural reservoir in Saudi Arabia using oxidative stress indicators in *Poecilia latipinna*. JAPS 24: 475-480.
- Stanic B, Andric N, Zoric S, Grubor-Lajsic G, Kovacevic R (2005) Assessing pollution in the Danube River near Novi Sad (Serbia) using several biomarkers in starlet (*Acipenser ruthenus* L). Ecotoxicol Environ Saf 65: 395-402.
- Shibata M, Hattori H, Sasaki T, Gotoh J, Hamada J, et al. (2003) Activation of caspase-12, by endoplasmic reticulum stress induced by transient middle cerebral artery occlusion in mice. Neuroscience 118: 491-499.
- Holland S, Lodwig E, Sideri T, Reader T, Clarke I, et al. (2007) Application of the comprehensive set of heterozygous yeast deletion

- mutants to elucidate the molecular basis of cellular chromium toxicity. Genome Biol 8: 268.
30. Sharma SK, Goloubinoff P, Christen P (2008) Heavy metal ions are potent inhibitors of protein folding. Biochem Biophys Res Commun 372: 341-345.
  31. Ramadan D, Rancy PC, Nagarkar RP, Schneider JP, Thorpe C (2009) Arsenic (III) species inhibit oxidative protein folding *in vitro*. Biochemistry 48: 424-432.
  32. Jacobson T, Navarrete C, Sharma SK, Sideri TC, Ibstedt S, et al. (2012) Arsenite interferes with protein folding and triggers formation of protein aggregates in yeast. J Cell Sci 125: 5073-5083.
  33. El-Bermawy SM, Ahmed ZA, Ali FI (2001) Changes in Total Proteins in Larvae of Rice Moth *Corcyra Cephalonica* due to Irradiation and Heat Stress. Arab J Nuclear Sci App 34: 323-335.
  34. Muthukumaravel K, Kumarasamy P, Amsath A, Gabriel Paulraj M (2007) Toxic Effect of Cadmium on the Electrophoretic Protein Patterns of Gill and Muscle of *Oreochromis mossambicus*. E J Chemistry 4: 284-286.
  35. Osman AGM, Al-Awadhi RM, Harabawy AS, Mahmoud UM (2010) Evaluation of the Use of Protein Electrophoresis of the African Catfish *Clarias gariepinus* (Burchell, 1822) for Biomonitoring Aquatic Pollution. J Environ Res 4: 235-243.
  36. Thophon S, Kruatrachue M, Upatham ES, Pokethitiyook P, Sahaphong S, et al. (2003) Histopathological alterations of white seabass, *Lates calcarifer*, in acute and subchronic cadmium exposure. Environ Pollut 121: 307-320.
  37. Zaghoul KH, Omar WA, Abdel-Khalek AA, Abo-Hegab S (2011) Ecological monitoring of Mediterranean *Solea aegyptiaca* transplanted into Qaroun Lake, Egypt. Aust J Basic Appl Sci 5: 851-862.
  38. Velma V, Tchounwou PB (2010) Chromium-induced biochemical, genotoxic and histopathologic effects in liver and kidney of goldfish, *Carassius auratus*. Mutat Res 698: 43-51.
  39. Camargo MM, Martinez CB (2007) Histopathology of gills, kidney, and liver of a Neotropical fish caged in an urban stream. Neotropical Ichthyology 5: 327-336.
  40. Sitohy MZ, El-Masry RA, Siliem TA, Mohamed NA (2006) Impact of some trace metals pollution in the River Nile water on muscles of *Clarias gariepinus* inhabiting El-Kanater El-Khyria and Helwan sites. J Agric Res 33: 1207-1222.
  41. Ibrahim SS (2007) Histopathological changes in some body organs of *Oreochromis niloticus* due to heavy metals in water of sabal drainage, El-Menoufia, governorate. J Egypt Acad Soc Environ Develop 8: 117-126.
  42. Yacoub AM, Mahmoud SA, Tayel SI (2008) Health status of *Oreochromis niloticus* in fish farm irrigated with drainage water in El-Fayoum Province, Egypt. Egypt J Aquat Res 34: 161-175.
  43. Kaoud HA, El-Dahshan AR (2010) Bioaccumulation and histopathological alterations of the heavy metals in *Oreochromis niloticus* fish. Nat Sci 8: 147-156.