

Cataract Formation without Specific Ocular Trauma after Traumatic Brain Injury: A Case Report

Carol Li, Sandra Fox and Blessen C Eapen*

Blessen C Eapen, Department of Rehabilitation Medicine, University of Texas Health Science Center, San Antonio, USA

*Corresponding author: Blessen C Eapen, Department of Rehabilitation Medicine, University of Texas Health Science Center, San Antonio, USA, Tel: +1-584-4662; E-mail: blessen.eapen2@va.gov

Received date: July 01, 2016; Accepted date: July 26, 2016; Published date: July 29, 2016

Copyright: © 2016 Li C, et al. This is an open-access article distributed under the terms of the Creative Commons Attribution License, which permits unrestricted use, distribution, and reproduction in any medium, provided the original author and source are credited.

Case Report

29 year-old African American male with no significant past medical history was a restrained driver involved in a motor vehicle side collision sustaining primarily left sided cranial injuries including left zygomatic and greater wing of sphenoid bone fractures, left frontal and temporal lobe epidural hematomas with 4mm shift and subsequent left temporal bone fracture requiring emergent evacuation and craniotomy. Patient was diagnosed with severe traumatic brain injury (TBI) and sustained multiple fractures involving pelvis, cervical, thoracic spine, and face but no reports of specific ocular injuries. During the patient's three-month inpatient neurorehabilitation stay at the VA Polytrauma Center, the patient was followed extensively by an interdisciplinary team including neuro-optometrist and vision rehabilitation specialists. A dilated fundus exam was completed 4 weeks after initial injury, and dot hemorrhages were identified in the inferior retina of right eye, suggesting trauma force to this eye.

A second dilated fundus exam was repeated 2 months after initial injury, and residual exudates from prior dot hemorrhages were again seen in the inferior retina of right eye in addition to cataract formation (Figures 1 and 2). Though patient sustained mostly left sided injuries as listed above, patient also sustained a fracture of the clivus with initial MRI brain demonstrating a small area of infarction to the right temporal lobe near upper brainstem. Given the anatomical proximity of clivus to the retina and basilar artery's connection to posterior cerebral artery, this may suggest a vascular etiology rather than the typical blunt force trauma etiology for patient's right ocular findings. Based on the severity of patient's injury and the absence of premorbid or family history of ocular pathology, this cataract finding is likely related to patient's TBI.

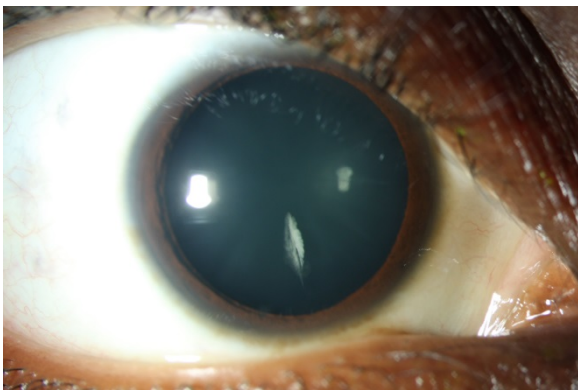


Figure 1: Retina of Eye.

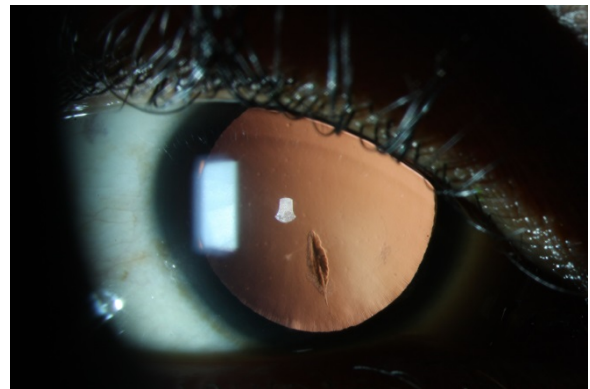


Figure 2: Photosensitivity.

Patient did not have any subjective symptoms other than dry eyes and photosensitivity. Patient did not have any complaints of eye pain, disruption in extraocular movements or diplopia. On initial exam, patient had slight nasal deviation of right eye, exhibited difficulty with smooth pursuit and saccadic movements of bilateral eyes leading to omission and addition reading errors, and had poor depth perception. All oculomotor skills improved and abnormal eye movements resolved with weekly vision rehabilitation. Given that patient's cataract was in the inferior temporal region of retina, functional vision was left intact.

It is well known that brain injury of all severities can cause visual disturbances and abnormalities. Current literature mainly addresses traumatic cataracts as a result of penetrating injuries as it is the leading cause of monocular blindness in pediatric age groups, and is more often associated with worse prognosis [1-3]. Cataracts are common after direct trauma, specifically blunt and open globe trauma and predominantly in males as reported in both pediatric and adult literature. However, non-perforating trauma such as concussive injuries to the orbit, head or body can also cause cataract formation [4,5]. There is limited information in regards to timeline of cataract formation after trauma. In adults, increasing age is the primary risk factor for cataract formation; however, certain military members, especially Marine Corps and Army, have higher incidence of traumatic cataracts due to occupational exposure [4]. Demographically, incidence rate is higher in black and non-Hispanic service members [4]. Given that this patient was also a service member, he may have other occupational exposure that may have put him at risk for cataract formation. However, in setting of known brain injury, etiology of patient's cataract is likely traumatic, though the mechanism may be

more indirect as most of his injuries are left sided. Additionally, the location of this patient's cataract is inferior, which differs from the more common anterior, segmental or subcapsular location [5]. To the authors' knowledge, this is the first case of unilateral traumatic cataract in the setting of traumatic brain injury without a specific associated ocular trauma. Findings from this case emphasize the importance of conducting visual screening to include a fundoscopic eye exam even if patient is generally asymptomatic. This becomes even more important in cases when patients with severe traumatic brain injuries may not have the communication abilities or cognition to convey symptoms. Early identification of cataract can facilitate management and maximize vision outcomes. Traumatic cataracts may lead to lens opacification, which can progress to decreased light perception and vision loss [5]. Fortunately in this case, there was no effect on functional vision given location of cataract, and patient will require periodic monitoring; however, removal of the cataract by a retinal surgeon may be necessary in the future to prevent known

complications like retinal detachment. Additional research is needed to explore the incidence and overall prognosis of this condition in TBI populations.

References

1. Zhu L, Wu Z, Dong F, Feng J, Lou D, et al. (2015) Two kinds of ocular trauma score for paediatric traumatic cataract in penetrating eye injuries. *Injury* 46: 1828-1833.
2. Ventura RE, Balcer LJ, Galetta SL (2014) The Neuro-ophthamology of head trauma. *Lancet Neurology* 13:1006-1016.
3. Shah MA, Shah SM (2011) Morphology of Traumatic Cataract. *British Journal of Ophthalmology* 1: 1-7.
4. Emasealu OV, Dorsey KA, Nagarajan S (2014) Surveillance of cataract in active component service members, US Armed Forces 2000-2013. *MSMR* 21: 10-3.
5. Gombos Dan S, Gombos, George M, (2008) Roy and Fraunfelder's *Current Ocular Therapy*. Page no 560-562.