

## Cementless Long Stem Total Hip Replacement for Revision of Failed Hemiarthroplasty

Adel Mohammad Salama<sup>\*</sup> and Sayed El-Etewy Soudy

Orthopedic Surgery Department, Faculty of Medicine, Zagazig University, Egypt

<sup>\*</sup>Corresponding author: Adel Mohammad Salama, Assistant Professor, Orthopedic Surgery Department, Faculty of Medicine, Zagazig University, Egypt, Tel: 0020553668921; E-mail: YMKhairy@medicine.zu.edu.eg

Received date: October 18, 2016; Accepted date: November 30, 2016; Published date: December 07, 2016

Copyright: © 2016 Salama AM, et al. This is an open-access article distributed under the terms of the Creative Commons Attribution License, which permits unrestricted use, distribution, and reproduction in any medium, provided the original author and source are credited.

### Abstract

**Background:** The total hip replacement after failure of hemiarthroplasty (unipolar or bipolar) has been associated with very high rates complications (intra- and postoperative).

**Patients and Methods:** Forty patients 24 males and 16 females with a mean age of 58 years (range: 48-68) had total hip arthroplasty (THA) revision of aseptic loosening of hip hemiarthroplasty. The mean duration of the follow-up was 42 months (range: 30-72), and the cases lost in follow up were excluded from the study. Failure was defined as revision arthroplasty or radiographic evidence of stem loosening, indicated by an Engh fixation score  $\leq 10$ . Vertical femoral migration of  $>5$  mm was defined as subsidence. Harris Hip Score (HHS), and the Merle d'Aubigne (MDA) score (21) were used for patients evaluation.

**Results:** Clinically, the mean preoperative HHS was improved significantly from 41 (24-56) preoperative to 89 (79-96) points at the last follow up. None of our patients had thigh pain postoperatively. Thirty two patients (80%) patients who had isolated groin pain preoperatively experienced no pain postoperatively, and eight patients had partial improvement. The proximal bone remodeling was recorded on serial X-rays at the last visit compared to the first postoperative radiographs and classified as type A, two cases, type b, 22 cases, and type C, 16 cases.

**Conclusion:** The cement less modular distal locking total hip replacement for revision of failed hemiarthroplasty is successful as regard the clinical and radiological results. The surgeon should care of the possibility of intraoperative complications like fractures and perforations.

**Keywords:** Long stem; Revision; Hemiarthroplasty; Cementless

### Introduction

All patients included in this study have given informed written consent for participating in the research before operation.

This prospective study was conducted at Zagazig University Hospitals, after approval of our ethical committee for research in accordance with the ethical standards laid down in the 1964 declaration of Helsinki and its later amendments.

The total hip replacement after failure of hemiarthroplasty (unipolar or bipolar) has been associated with very high rates complications (intra- and postoperative). There is an increasing incidence of hip replacements in relatively young and physically active patients. The large numbers of fracture neck femur treated with hip hemiarthroplasty increased the need for revision and re-revision [1].

The challenge of revision hip arthroplasty after femoral component failure results from the poor quality of bone, deformity of proximal femur and resulting bone defects after removing the stem and the cement mantle [2]. The remaining bone cannot achieve stable fixation of the femoral stem and maintain it [3]. Cemented long-stem femoral components were used by some surgeons, but sufficient fixation for the implant not provided resulting in early loosening [4-7].

Many surgeons used cement-less, porous-coated, tapered and fluted monoblock stems and reported good results [8-11]. The introduction of modular cement less long femoral stems for revision with added distal fixation by locking screw has changed the quality of revision techniques [12]. Since in the revision cases there is extensive bone loss of the proximal femur and weak and poorly vascularized remaining bone, the calcar replacement can give stability.

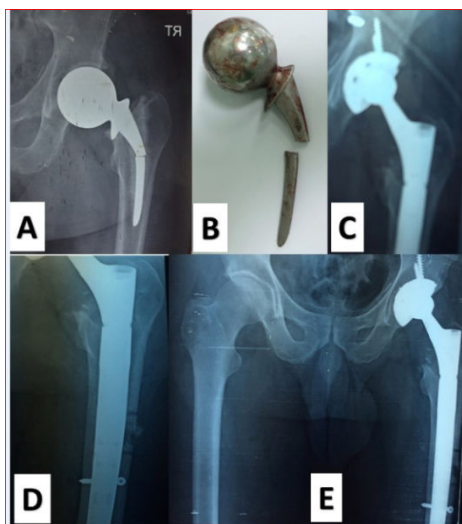
The Russian orthopedist Konstantin Sivash in 1956 introduced the modular cement less prostheses with distal fixation. Many modifications were performed until the S-ROM (Sivash-Range of Motion) was reached. The anatomical landmarks also lost after bone loss of proximal femur. The modularity of the stem gives adjustment of length, and anteversion to give added stability. The press fit stem fixation and distal locking screws give immediate stability up to osteointegration of the implant occur [13-19].

The aim of this prospective study is to evaluate clinically and radiographically the results of revision total hip arthroplasty using the ZMR<sup>®</sup> (Zimmer Modular Revision) calcar replacement, distally locked cement less stem in 40 cases.

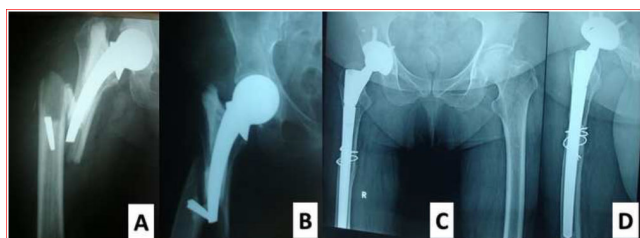
### Patients and Methods

Through the period from January 2008 and December 2014, forty patients 24 males and 16 females with a mean age of 58 years (range: 48-68) had total hip arthroplasty (THA) revision of aseptic loosening

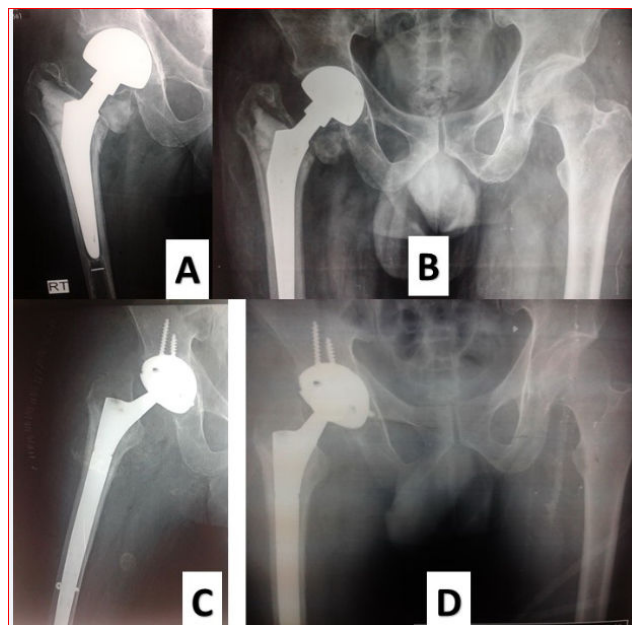
of hip hemiarthroplasty. In 25 patients the aseptic loosening was the cause of revision, periprosthetic fracture in 10 cases, and fracture of the implant in 5 cases (Figure 1). The ZMR® modular cement less distally locked prosthesis was used in all cases. The mean duration of the follow-up was 42 months (range: 30-72), and the cases lost in follow up were excluded from the study. All the operations were performed in our institution and by the same surgical team. The revision was for Thompson prosthesis in 28 cases (Figures 1 and 2) and bipolar hemiarthroplasty in 12 cases (Figure 3).



**Figure 1:** Male patient 58 years old with implant failure (Broken Austin Moore): A) preoperative X-ray; B) intraoperative photo after extraction of prosthesis; C and D) postoperative X-ray after long stem cementless revision; E) X-ray one year postoperative.



**Figure 2:** Female patient 60 years old with periprosthetic fracture femur and (Broken austin moore prosthesis) A and B) preoperative X-ray; C and D) X-ray three years postoperative prosthesis.



**Figure 3:** Male patient 63 years old with loose bipolar hemiarthroplasty and painful hip: A and B) preoperative x-ray; C and D) postoperative x-ray with cementless long stem total hip replacement.

According to Paprosky classification [10], the bone defect in the femur was classified as type 1 in 20 hips (50%), type 2 in 10 hips (25%), and type 3A in 6 hips (15%) and type 3B in 4 hips (10%). Implant stability was measured using the Engh fixation scale [20]. Failure was defined as revision arthroplasty or radiographic evidence of stem loosening, indicated by an Engh fixation score  $\leq 10$ . Vertical femoral migration of  $>5$  mm was defined as subsidence.

### Operative Technique

The hardinge approach in lateral position was used in all cases. Extended trochanteric osteotomy needed in 24 cases. After extraction of the implant and bone cement, the fibrous tissue membrane were removed. The acetabular component was performed first with cement less anatomic fixation with 2 screws at least for secure fixation in all cases. The femoral canal was then reamed and prepared using successive reamers of the system under intraoperative radiology to safeguard against perforation of the canal and misdirection.

When reaming completed the last reamer should be stable inside the medulla, then trials were done to determine the length, anteversion and test for stability. As a prophylactic step a stainless steel loop was fashioned around the distal femur throughout the trials and stem impaction to safeguard against iatrogenic fractures of the femur in cases with weak bone stock.

In five cases, bone graft was taken from the iliac crest and impacted in the femoral canal to help good contact between the stem and bone. After impaction of the definitive stem, the extended trochanteric osteotomy fragment was reduced and fixed to the femur using steel wires cerclage. The wound then closed over suction drain.

The mean blood loss was 1000 (range 750-2000) ml, and the mean operative time was 150 (range 120-240) min. Intravenous cephalosporin antibiotics was used until we the results of cultures taken intraoperative appear, and then the antibiotics were continued according to culture. Early mobilization and mechanical measures against thromboembolism were started second day after the operation with the use of elastic stockings.

Low-molecular-weight heparin was used routinely 24 hours postoperative for 3 weeks postoperative. Indomethacin and was administered for six weeks to prevent heterotopic ossification in 22 cases, and naproxen was used in 18 cases to decrease effect on stomach. Partial weight bearing was allowed in the first using axillary crutches 6 weeks postoperative and full weight bearing from 8 to 9 weeks with contralateral elbow crutch.

The patients were instructed to return for follow-ups three weeks, six weeks, and three months, followed by six months and annually visits.

Clinically, the Harris Hip Score (HHS) [21] was used for patient's evaluation. A score below 70 points of 100 is defined as poor; between 70 and 79, is fair; between 80 and 89, as good; and greater than 90, as excellent results.

The plain X-ray films (AP and lateral views of the hip + AP view of the pelvis) were performed preoperatively, postoperatively and during the follow-up visits. The evaluation of serial X-rays were done to monitor the implant stability. The Callaghan et al. [22] criteria were used for evaluation of proximal femoral bone remodeling. According to them A) increased defect or no remodeling; B) small degree of remodeling; and C) significant bone remodeling. The bone remodeling was measured by the cortical thickening 1 cm below the lesser trochanter.

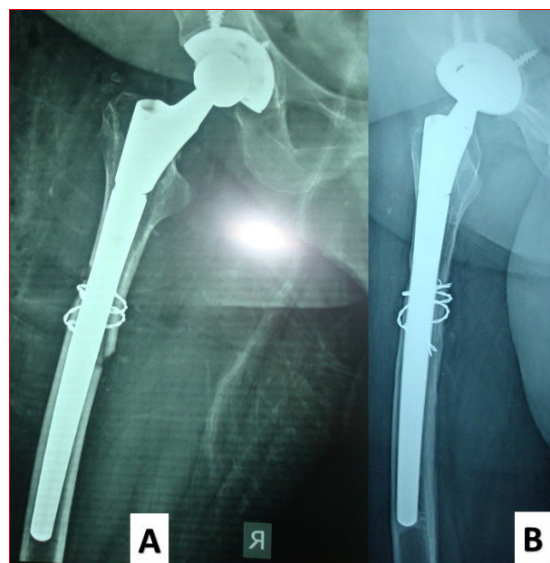
## Results

There were no cases of dislocation or deep infection in this series up to the final follow up visit.

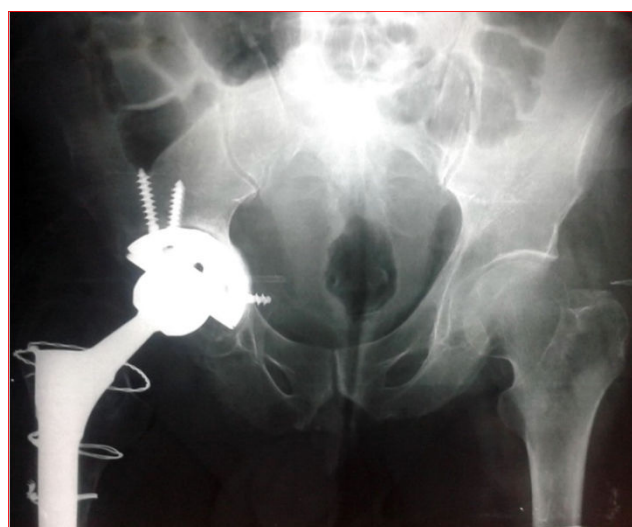Clinically, the mean preoperative HHS was improved significantly from 41 (24-56) preoperative to 89 (79-96) points at the last follow up.

None of our patients had thigh pain postoperatively. Thirty two patients (80%) patients who had isolated groin pain preoperatively experienced no pain postoperatively, and eight patients had partial improvement. At the end of follow-up 24 (60%) of the patients were freely walking without support, 14 (35%) patients using cane for walking and limited for five blocks distance, and 2 (5%) needed walker for indoor movements.

According to the migration criteria of Paprosky [10] none of the cases has femoral stem migration more than 5 mm. Radiologically, there was good osteointegration of the femoral stems with stability up to the last follow up visit (Figure 4). The proximal bone remodeling was recorded on serial X-rays at the last visit compared to the first postoperative radiographs and classified as type A, two cases, type b, 22 cases, and type C, 16 cases, according to Callaghan et al. [22]. On the acetabular side there were 3 cases with loosening but none of them did revision during the follow up period (Figure 5).



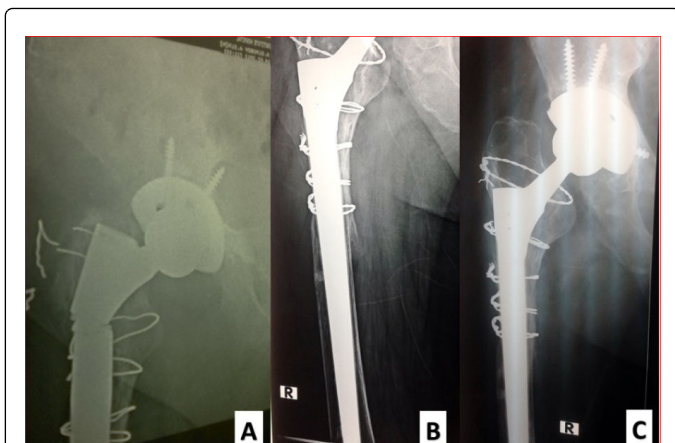
**Figure 4:** Follow up X-ray with bone osteointegration A) 6 weeks postoperative; B) X-ray three years postoperative.



**Figure 5:** Follow up X-ray patient no. 34 with acetabular radiolucent line and medial cup migration.

Surgical complications were reported in five cases. One patient with deep vein thrombosis (DVT) treated medically with anticoagulants and elastic stockings and had no respiratory complications.

One patient with fracture stem at the junction between the proximal calcar replacement and the remaining stem and the patient had revision with new long stem modular prosthesis (Figure 6). Three patients with superficial infection were treated with intravenous antibiotics and repeated dressing with follow up of the infectious process by clinical and laboratory tests.



**Figure 6:** Male patient with broken femoral stem 2 years after the first operation; A) preoperative X-ray; B) X-ray after revision of both acetabular and femoral components; C) X-ray 2 years after the revision.

## Discussion

The pain following hemiarthroplasty may be due to acetabular erosion or loosening of the prosthesis. The pathology here may be caused by excessive length of the neck, impaction, or incongruences between the acetabulum and femoral head [23-25]. Some authors have reported high loosening rates in comparison to primary total hip arthroplasty in conversion of hemiarthroplasty to THA [26-29].

Sharkey et al. reported his study of 45 patients of conversion of hemiarthroplasty to THA and reported that 20% of the patients continued to have groin or buttock pain after THA without identification the cause of unsuccessful result [30]. In this study no patients had thigh pain postoperatively. Thirty two patients (80%) patients who had isolated groin pain preoperatively experienced no pain postoperatively, and eight patients had partial improvement. At the end of follow-up 24 (60%) of the patients were freely walking without support, 14 (35%) patients using cane for walking and limited for five blocks distance, and 2 (5%) needed walker for indoor movements. In the early study of Amstutz and Smith [29], they reported the results of 41 patients with conversion arthroplasty. There were 5 iatrogenic femoral fractures, two medial cortex perforations with protrusion of the stem, two unstable cases, two cases with infection, three cases had deep venous thrombosis and six patients (14.6%) with progressive loosening. Three revisions needed at the end of follow-up. A larger series of 132 hemiarthroplasties that were converted to THA reported by Sierra and Cabanela [28] with 10% rate of loosening after a mean follow-up of 7.1 years and 45% major complications, 12 iatrogenic femoral fractures (9%) and 13 dislocations (9.8%).

In this series, the rate of loosening was 2.5% (one of 40) after a mean follow up of 42 months (range: 30-72).

With the increased rate of hip replacement in young patients and need for revision, the development of cement less modular implants with distal locking was important for the correction of limb discrepancies, and implant stability. The modular stems with calcar replacement can overcome the proximal bone losses in femoral

revision procedures using cement less prostheses with distal fixation [16-19].

Results from revisions on THA cases using modular cementless femoral components with distal fixation prostheses were extremely encouraging. Reported complete component's Osseo integration forms a valuable treatment option for femoral revision of THA cases [29-32,16].

The classification of Paprosky [10] is extremely useful because there is a direct relationship between the stem migration and early mechanical failure. We have no case with incidence more than 5 mm, until the last follow up. The reported incidence of dislocation after conversion arthroplasty varies from 0 to 50% in literatures [27,29]. We have no postoperative dislocation in this series.

Proximal bone remodeling was achieved by different degrees in 28 cases our 40 cases. According to Callaghan et al. [22] two cases were type A, 22 cases type b, and 16 cases type C. These findings are concordant with what of other many studies [31,32].

Clinically, there is a significant improvement in the mean HHS from 41(24-56) preoperative to 89 (79-96) points at the last follow up and these is similar to other results in the literature [8,9,16].

## Conclusion

The cement less modular distal locking total hip replacement for revision of failed hemiarthroplasty is successful as regard the clinical and radiological results. The surgeon should care of the possibility of intraoperative complications like fractures and perforations.

## Conflict of Interest

The author states that there has been no conflict of interest and there were no potential benefits in any form from a commercial party related directly or indirectly to the subject of this manuscript. No funds, grants, or personnel to be acknowledged have been hidden.

## References

1. Kurtz S, Mowat F, Ong K, Chan N, Lau E, et al. (2005) Prevalence of primary and revision total hip and knee arthroplasty in the United States from 1990 through 2002. *J Bone Joint Surg Am* 87: 1487-1497.
2. Pedersen AB, Johnsen SP, Overgaard S, Soballe K, Sorensen HT, et al. (2005) Total hip arthroplasty in Denmark: incidence of primary operations and revisions during 1996, 2002 and estimated future demands. *Acta Orthop* 76: 182-189.
3. Kang MN, Huddleston JI, Hwang K, Imrie S, Goodman SB (2008) Early outcome of a modular femoral component in revision total hip arthroplasty. *J Arthroplasty* 23: 220-225.
4. Kavanagh BF, Ilstrup DM, Fitzgerald RH (1985) Revision total hip arthroplasty. *J Bone Joint Surg Am* 67: 517-526.
5. Haydon CM, Mehin R, Burnett S, Rorabeck CH, Bourne RB (2004) Revision total hip arthroplasty with use of a cemented femoral component results at a mean of ten years. *J Bone Joint Surg Am* 86: 1179-1185.
6. Katz RP, Callaghan JJ, Sullivan PM, Johnston RC (1997) Long-term results of revision total hip arthroplasty with improved cementing technique. *J Bone Joint Surg Br* 79: 322-326.
7. Mulroy WF, Harris WH (1996) Revision total hip arthroplasty with use of so-called second-generation cementing techniques for aseptic loosening of the femoral component. A fifteen-year-average follow-up study. *J Bone Joint Surg Am* 78: 325-330.

8. Cameron HU (1993) The 3-6-year results of a modular non-cemented low-bending stiffness hip implant A preliminary study. *J Arthroplasty* 8: 239-243.
9. Böhm P, Bischel O (2001) Femoral revision with the Wagner SL revision stem: evaluation of one hundred and twenty-nine revisions followed for a mean of 4.8 years. *J Bone Joint Surg Am* 83: 1023-1031.
10. Paprosky WG, Greidanus NV, Antoniou J (1999) Minimum 10 year-results of extensively porous-coated stems in revision hip arthroplasty. *Clin Orthop Relat Res* 369: 230-242.
11. Engh CA, Ellis TJ, Koralewicz LM, McAuley JP, Engh CA (2002) Extensively porous-coated femoral revision for severe femoral bone loss: minimum 10-year follow-up. *J Arthroplasty* 17: 955-960.
12. Ko PS, Lam JJ, Tio MK, Lee OB, Ip FK (2003) Distal fixation with Wagner revision stem in treating Vancouver type B2 periprosthetic femur fractures in geriatric patients. *J Arthroplasty* 18: 446-452.
13. Valle CJ, Paprosky WG (2003) Classification and an algorithmic approach to the reconstruction of femoral deficiency in revision total hip arthroplasty. *J Bone Joint Surg Am* 85: 1-6.
14. Barrington JW, Freiberg AA, Rubash HE (2007) Femoral component revision: modularity. In: Callaghan JJ, Rosenberg AG, Rubash HE (eds.) *The adult hip*. Lippincott Williams & Wilkins, Philadelphia, 2007.
15. McAuley JP, Engh CA (2004) Femoral fixation in the face of considerable bone loss: cylindrical and extensively coated femoral components. *Clin Orthop Relat Res* 429: 429-431.
16. Kwong LM, Miller AJ, Lubinus P (2003) A modular distal fixation option for proximal bone loss in revision total hip arthroplasty: a 2-to 6-year follow-up study. *J Arthroplasty* 18: 94-97.
17. Wirtz DC, Heller KD, Holzwarth U, Siebert C, Pitto RP, et al. (2000) A modular femoral implant for uncemented stem revision in THR. *Int Orthop* 24: 134-138.
18. Park YS, Moon YW, Lim SJ (2007) Revision total hip arthroplasty using a fluted and tapered modular distal fixation stem with and without extended trochanteric osteotomy. *J Arthroplasty* 22: 993-999.
19. McCarthy JC, Lee JA (2007) Complex revision total hip arthroplasty with modular stems at a mean of 14 years. *Clin Orthop Relat Res* 465: 166-169.
20. Engh CA, Massin P, Suthers KE (1990) Roentgenographic assessment of the biologic fixation of porous-surfaced femoral components. *Clin Orthop Relat Res* 257: 107-128.
21. Harris WH (1969) Traumatic arthritis of the hip after dislocation and acetabular fractures: treatment by mold arthroplasty An end-result study using a new method of result evaluation. *J Bone Joint Surg Am* 51: 737-755.
22. Callaghan JJ, Salvati EA, Pellicci PM, Wilson PD, Ranawat CS (1985) Results of revision for mechanical failure after cemented total hip replacement, 1979 to 1982 A two to five-year follow-up. *J Bone Joint Surg Am* 67: 1074-1085.
23. Gingras M, Clarke J, Evarts CM (1980) Prosthesis replacement in femoral neck fracture. *Clin Orthop Relat Res* 152: 147-152.
24. Andersson G, Müller-Nilsen J (1972) Results after arthroplasty of the hip with Moore prosthesis. *Acta Orthop Scand* 43: 39-44.
25. Kaltsas D, Klugman A (1986) A acetabular erosion: A comparison between the Austin Moore and Monk hard top prosthesis. *Injury* 17: 230-236.
26. Bilgen O, Karaeminogullari O, Kulecioglu A (2000) Results of conversion total hip prosthesis performed following painful hemiarthroplasty. *J Int Med Res* 28: 307-312.
27. Hammad A, Abdel-Aal A (2006) Conversion total hip arthroplasty: Functional outcome in Egyptian population. *Acta Orthop Belg* 72: 549-554.
28. Sierra RJ, Cabanela ME (2002) Conversion of failed hip hemiarthroplasties after femoral neck fractures. *Clin Orthop Relat Res* 399: 129-139.
29. Amstutz R, Smith R (1979) Total hip replacement following failed femoral hemiarthroplasty. *J Bone Joint Surg Am* 61: 1161-1166.
30. Sharkey PF, Rao R, Hozack WJ, Rothman RH, Carey C (1998) Conversion of hemiarthroplasty to total hip arthroplasty: Can groin pain be eliminated? *J Arthroplasty* 13: 627-630.
31. Boehm PM (2007) Revision Wagner technique: stem. In: Callaghan JJ, Rosenberg AG, Rubash HE (eds.) *The adult hip*. Lippincott Williams & Wilkins, Philadelphia, 2007.
32. Pina Cabral FJS, Rabello BT, Pina Cabral FM, Silveira SLC, Penedo JLM, et al. (2006) Review of total hip arthroplasty using stem femoral wagner. *Rev Bras Ortop* 41: 393-398.