

Chronicity and Recurrence as Prognostic Factors in Central Serous Chorioretinopathy after Half-Dose Photodynamic Therapy

Susana Penas^{1,2*}, Ana F Costa², Joana R Araújo^{1,2}, Pedro Alves Faria^{1,2}, Elisete Brandão¹, Amandio Rocha-Sousa^{1,2}, Angela Carneiro^{1,2} and Fernando Falcão-Reis^{1,2}

¹Ophthalmology Department, S. João Hospital Center, Porto, Portugal

²Department of Sense Organs, Faculty of Medicine, University of Porto, Portugal

*Corresponding author: Susana Penas, Serviço de Oftalmologia do Centro Hospitalar de São João, EPE, Alameda Professor Hernâni Monteiro, 4200-319 Porto-Portugal, Tel: 00351910725217; Fax: 00351225513669; E-mail: spenas@med.up.pt

Received date: June 17, 2016; Accepted date: September 15, 2016; Published date: September 19, 2016

Copyright: © 2016 Penas S, et al. This is an open-access article distributed under the terms of the Creative Commons Attribution License, which permits unrestricted use, distribution, and reproduction in any medium, provided the original author and source are credited.

Abstract

Purpose: To analyze the influence of pre-treatment chronicity signs and post-treatment recurrence events in short and long-term structural and functional outcomes in central serous chorioretinopathy (CSC) patients submitted to half-dose photodynamic therapy (PDT), and to determine the profile of patients that recurred after treatment.

Methods: A retrospective, observational study included treatment-naïve patients with CSC submitted to half-dose PDT. Best corrected visual acuity (BCVA), central macular thickness (CMT) using OCT and retinal sensitivity (RS) assessed by microperimetry were registered. A sub-analysis was performed considering both chronicity signs and recurrence.

Results: Eighty-four eyes of 73 patients were included in this study. The mean follow up was 32.18 ± 23.03 months. A total of 79 eyes (94%) presented a complete resolution of sub-retinal fluid at the 3-months follow-up visit. Chronicity versus no- chronicity signs: 57 eyes (67.9%) had chronicity signs and 22.8% of those had at least one recurrence. Recurrence was significantly higher in the chronicity group (p=0.031). The chronicity group was significantly older (p=0.009) and with lower baseline CMT (p=0.041). A significant long-term improvement in BCVA, CMT and RS was consistently found in both groups (p<0.05), however patients with chronicity signs presented worse visual outcomes (p<0.05). Recurrence versus no-recurrence: 14 eyes (16.7%) had post-treatment relapses, and 92.9% of those had chronicity signs (p=0.031). Recurrent patients presented with lower baseline CMT as well (p=0.017). A significant long-term improvement was observed for all outcomes in non-recurring patients (p<0.05) whereas a significant improvement in BCVA was only found 3 months after treatment in the recurrent group (p=0.009).

Conclusions: Half-dose PDT is an effective and safe treatment for CSC. Nonetheless, patients with pre-treatment chronicity signs presented more recurrences and worse functional and morphological outcomes, suggesting they should be treated earlier in order to avoid poorer results. Post-treatment recurrence negatively influenced the outcomes.

Keywords: Central serous chorioretinopathy; Half-dose photodynamic therapy; Optical coherence tomography; Macular thickness; Microperimetry; Retinal sensitivity

Introduction

Central serous chorioretinopathy (CSC) is a chorioretinal disorder characterized by serous detachment of the neurosensory retina. The pathophysiology remains poorly understood, but choroidal vascular hyperpermeability, and subsequent retinal pigment epithelium (RPE) dysfunction, due to a mechanical hydrostatic stress, seem to be primarily involved in its pathophysiology [1-5]. CSC can present itself in an acute or chronic stage. Although acute CSC resolves spontaneously in most cases, leaving no or minor visual complaints, the persistence of sub- macular fluid or history of recurrence are common. Chronic forms of CSC can evolve with severe and permanent visual loss, which is often associated with recurrent or persistent forms of disease [6-10].

The anatomic evaluation of CSC patients is usually performed using optical coherence tomography (OCT), providing valuable information regarding both the quantification of sub- retinal fluid (SRF), macular thickness, external retina and RPE integrity as well as the choroidal thickness [8,11,12]. Recently, a new classification of CSC has been proposed based on specific OCT findings, suggesting increasing chronicity [13]. These parameters are more objective than those based on patients recall or time elapsing since first ophthalmic observation.

Photodynamic therapy (PDT) with verteporfin has been accepted as an efficient and safe treatment modality for CSC [1,2,14-16]. Its effect on choroidal permeability proved to reduce choroidal thickness, resolve sub-retinal fluid and reduce the recurrences [15-20]. However, even after the SRF resolution and a visual acuity recovery to normal or near normal levels, a significant percentage of patients still complain of loss of contrast sensitivity, metamorphopsia and dyschromatopsia after PDT. Recent studies assessed retinal functional status in resolved CSC patients. Multifocal electroretinography (mfERG) and microperimetry (MP) have both been used for a functional retinal assessment in these

patients, allowing a clearer understanding of patients' complaints regarding their visual quality [21-24].

Treatment sparing regimens involving reduced dose or fluence protocols (half-dose or half-fluence) have been used to minimize PDT potential side-effects [1,2,25-35]. These safe-enhanced regimens as half-dose treatment efficacy have been widely accepted, although adequate procedure guidelines are still missing and the factors influencing its long-term post-treatment outcomes are still unknown.

Correlating both structural and functional outcomes may provide new insights in the understanding of photodynamic therapy effects in CSC patients. The main purpose of this study is to analyze the influence of pre-treatment chronicity findings and post-treatment recurrence in short and long-term structural and functional outcomes after half-dose PDT in CSC patients. The secondary purpose of this study is to determine the pre and post-treatment characteristics of patients that recurred after PDT in order to preview their pathological profile.

Materials and Methods

This retrospective, observational study enrolled 84 eyes of 73 patients (62 male and 11 female) with acute or chronic CSC who received half-dose PDT at the Ophthalmology Department of São João Hospital, Portugal, between 2006 and 2014. The study design and the collection of data were approved by the Ethics Committee of the hospital. All procedures were conducted in accordance with the Declaration of Helsinki.

The inclusion criteria were: (1) treatment-naïve CSC patients diagnosed based on fundoscopy, OCT, fluorescein angiography (FA) and indocyanine green angiography (ICGA) (2) presenting macular sub-retinal fluid with sub or juxtafoveal focal leaks or multiple areas of leakage, submitted to half-dose PDT; (3) age \geq 18 years; (4) follow-up \geq 3 months. The exclusion criteria included: (1) previous intervention with any forms of therapy; (2) other chorioretinal disorders that could affect visual acuity or cause serous retinal detachment; (3) presence of choroidal neovascularization (CNV); (4) presence of posterior cystoid retinal degeneration; (5) history of intraocular surgery or ocular trauma.

A safe-enhanced PDT protocol for CSC was performed by administering half the normal dose (3 mg/m²) of Verteporfin (Visudyne; Novartis AG, Basel, Switzerland), followed by a 689 nm laser delivery, 10 minutes after the start of the infusion, for 83 seconds, targeting the leaking spots. When multiple leaking areas were detected, a multi-spot treatment was performed. Retreatments were performed in case of persistence or recurrence of sub-retinal fluid.

Patients were evaluated at baseline and followed up at 3, 6, 1, 18 and 24 months, and thereafter annually after PDT. The ophthalmologic examination included: (1) best corrected visual acuity (BCVA) with Early Treatment Diabetic Retinopathy Study (ETDRS) chart measurement at 4 m distance and conversion to logarithm of the minimal angle of resolution (logMar) equivalents; (2) measurement of central macular thickness (CMT) by Stratus OCT (Stratus OCT, Carl Zeiss Meditec, Inc., Dublin, CA, USA) and later with SD-OCT (Spectralis; Heidelberg Engineering, Inc., Heidelberg, Germany); (3) retinal sensitivity (RS) assessment using MP-1 microperimetry (Nidek, Vigonza, Italy). Fluorescein (FA) and indocyanine green angiography (ICGA) were performed in all patients at baseline and during the follow up in eyes with persistence or recurrence of SRF.

The OCT imaging acquisition protocol included a macular 6 × 6 mm-radial volume scan (Stratus OCT) and a macular cube scan 20° × 20° (Spectralis OCT) centered on the fovea and both a high quality horizontal and vertical 6 mm scan through the fovea. Macular sensitivity was measured by fundus-related microperimetry using a standardized macular 20° testing pattern with a 4-2 staircase testing strategy. A Goldmann III stimulus size-grid with a projection time of 200 ms was projected onto the central 20° and the starting stimulus light attenuation was set at 10 dB. A bright red cross with 2° was used as the fixation target. For assessment of fixation, the fundus movements were tracked during examination. Fixation stability was calculated as the percentage of fixation points inside the 2° diameter circle. In each eye a polygon covering the central 4, 12 and 20° field points was manually done. Mean CRS at the 12 locations (number of measurement points) covering the central 4°- field, 45 locations covering the central 12° field, and 76 locations covering the central 20°- was automatically determined by the MP-1 microperimeter.

Based on baseline fundoscopy, OCT and FA findings, chronicity signals were defined and the patients were classified in two categories: with or without chronicity signals. These signals included ipsilateral fundoscopic and/or angiographic assessed retinal pigment atrophic findings, as well as OCT assessed neurosensory retinal thinning and/or irregular external retinal layer surface and/or RPE clumping or atrophy. This classification was performed by a retinal specialist (SP). The comparison of both structural, using central macular thickness, and functional, using BCVA and retinal sensitivity, outcomes was compared between these two groups.

A sub-analysis was also performed considering the occurrence of post-treatment recurrence, and both pre and post treatment characteristics were compared between recurrent and non-recurrent patients.

For statistical analysis, SPSS software version 20.0 (SPSS Inc, Chicago, IL, USA) was used. Based on the sample size, distribution of the samples and variable type, the level of statistical significance was calculated with Mann-Whitney U test, Independent Samples t Test, Fisher's exact test and Wilcoxon signed-rank test. A P value less than 0.05 was considered statistically significant.

Results

A total of 84 eyes of 73 treatment-naïve patients with acute or chronic treated with half-dose PDT were included in this study, 62 (84.9%) males and 11 (15.1%) females, with a mean age of 47.3 ± 10.2 years (range 26 to 70 years). The mean follow up period was 32.2 ± 23.0 months (range 3 to 84 months). Twenty-one patients (28.8%) had bilateral active disease, however only 10 (13.7%) needed a bilateral treatment, since the fellow eye presented a spontaneous resolution. A total of 79 eyes (94%) presented a complete resolution of SRF at the 3-months follow-up visit. Chronicity signals were seen in 57 eyes (67.9%). Recurrent episodes were observed in 14 eyes (16.7%).

A sub-analysis of the outcomes was performed considering both chronicity and recurrence.

Chronicity versus no-chronicity signals

Table 1 and Table 2 summarize the clinical and demographic characteristics of these 2 groups. There were no significant differences between both groups regarding sex distribution, however the chronicity group was significantly older than the no-chronicity one

(49.5 ± 9.2 vs. 43.096 ± 10.9 years, (p=0.009, t test). No significant asymmetries were found in baseline mean BCVA and RS, but the CMT in the chronicity group was significantly lower (308.8 ± 124.7 μm vs.

374.0 ± 151.5 μm) (p=0.04, Mann-Whitney U test). The follow up period was otherwise larger in the chronicity group (p=0.05, t Test). The mean time to SRF resolution was similar between both groups.

	Recurrence (n=11)	No-Recurrence (n=62)	P Value	Chronicity Signals	No-Signals Chronicity	P Value
Mean ± SD age (years) Range	49.18 ± 11.771 32 to 69	46.90 ± 10.024 26 to 70	0.501*	49.48 ± 9.214 32 to 70	42.96 ± 10.945 26 to 69	0.009*
Gender Male: Female%	8:3 72.7%: 27.3%	54:8 87.1%:12.9%	0.719	41:7 85.4%:14.6%	21:4 84%:16%	1.000 ^b
Disease Uni: Bilateral%	6:5 54.5%: 45.5%	46:16 74.2%:25.8%	0.277 ^b	34:14 70.8%:29.2%	18:7 72%:28%	1.000 ^b
Treatment Uni: Bilateral%	8:3 72.7%:27.3%	55:7 88.7%: 11.3%	0.168 ^b	40:8 83.3%:16.7%	23:2 92%:8%	0.478 ^b
*P values<0.05 are considered to be statistically significant. ^a Independent sample t test ^b Fishers exact test						

Table 1: Baseline demographic characteristics of 73 patients.

In the group with chronicity signals the BCVA was 68.7 ± 11.4 letters and a significant improvement was registered every visit until 36 months after treatment (p<0.05, Wilcoxon signed-rank test). No significant differences were seen beyond that time point. A significant decrease in mean CMT was also found every scheduled visit until the 36 month follow up visit (p<0.05 at each time point, Wilcoxon signed-

rank test), losing its statistical significance after that period. The mean RS over the central 4° and 12° was significantly increased in every visit until 36 months and 24 months, respectively (p<0.05 in each time point, Wilcoxon signed-rank test). Furthermore the mean RS over the central 20° also showed an improvement with time, however it was only significant at 12 months (p=0.016, Wilcoxon signed-rank test).

	Recurrence (n=14)	No-Recurrence (n=70)	P Value	Chronicity Signals (n=57)	No-Signals (n=27)	P Value
Mean ± SD follow up (months) Range	53.57 ± 22.873 6 to 84	27.90 ± 20.692 3 to 72	0.000a*	37.00 ± 23.617 3 to 84	22.00 ± 18.267 3 to 73	0.005 ^a
Mean ± SD to resolution of SRF (months) Range	2.07 ± 1.492 1 to 6	1.99 ± 1.664 1 to 12	0.785 ^b	2.05 ± 1.817 1 to 12	1.89 ± 1.155 1 to 5	0.670 ^a
Recurrence Yes: No%				13:44 22.8%: 77.2%	1:26 3.7%: 96.3%	0.031 ^c
Chronicity Signals Yes: No%	13: 1 92.9%: 7.1%	44:26 62.9%: 37.1%	0.031 ^c			
Mean ± SD baseline BCVA (letters)	70.57 ± 10.775	69.51 ± 11.629	0.732 ^b	68.67 ± 11.437	71.85 ± 11.340	0.869 ^b
Mean ± SD baseline CMT (μm)	249.30 ± 104.934	346.93 ± 138.455	0.017 ^b *	308.75 ± 124.668 (n=44)	374.00 ± 151.516 (n=26)	0.041 ^b *
Mean ± SD baseline RS 4° (dB)	12.660 ± 4.9201 (n=5)	12.716 ± 3.7960 (n=29)	0.814 ^b	11.809 ± 4.2120 (n=22)	13.050 ± 3.2587 (n=12)	0.557 ^b
Mean ± SD baseline RS 12° (dB)	14.400 ± 3.7336 (n=5)	14.317 ± 3.4817 (n=29)	0.925 ^b	13.752 ± 3.6466 (n=22)	14.883 ± 2.8390 (n=12)	0.471 ^b

Mean ± SD baseline RS 20° (dB)	16.360 ± 1.7329 (n=5)	16.007 ± 2.6333 (n=29)	0962 ^b	15.814 ± 2.7315 (n=22)	16.508 ± 2.0509 (n=12)	0.488
--------------------------------	-----------------------	------------------------	-------------------	------------------------	------------------------	-------

SD: Standard Deviation; SRF: Subretinal Fluid; BCVA: Snellen Best Corrected Visual Acuity; CMT: Central Macular thickness; RS: Retinal Sensitivity.
^aP values<0.05 are considered to be statistically significant
^aIndependent sample t test
^bMann-Whitney U test
^cFisher's exact test

Table 2: Baseline demographic characteristics of 84 eyes.

Patients with no chronicity signals, in their turn, presented a baseline mean BCVA of 71.9 ± 11.3 letters and a CMT of 374.0 ± 151.5 μm, presenting both a significant improvement in BCVA and a decrease in CMT after PDT in every visit until 36 months and 24 months, respectively (p<0.05, Wilcoxon signed-rank test). Conversely, the gain in mean central RS was not so consistent, proving to be significant only at 6 months in both central 4° and 20° and at 12 months over central 12° (p<0.05, Wilcoxon signed-rank test).

Comparing the post-treatment outcomes between both groups, the chronicity one evolved with lower BCVA scores, presenting significantly lower at the 3, 6, 1, 18, 24 and 60 months follow-up assessments (p<0.05, Mann-Whitney U test). While mean CMT evolved in a similar mode between groups, mean RS progressed in a parallel way except at 36 months after PDT when the mean RS within the central 12° and 20° were statistically different (p=0.021 and p=0.047, respectively, Mann-Whitney U test) (Figure 1).

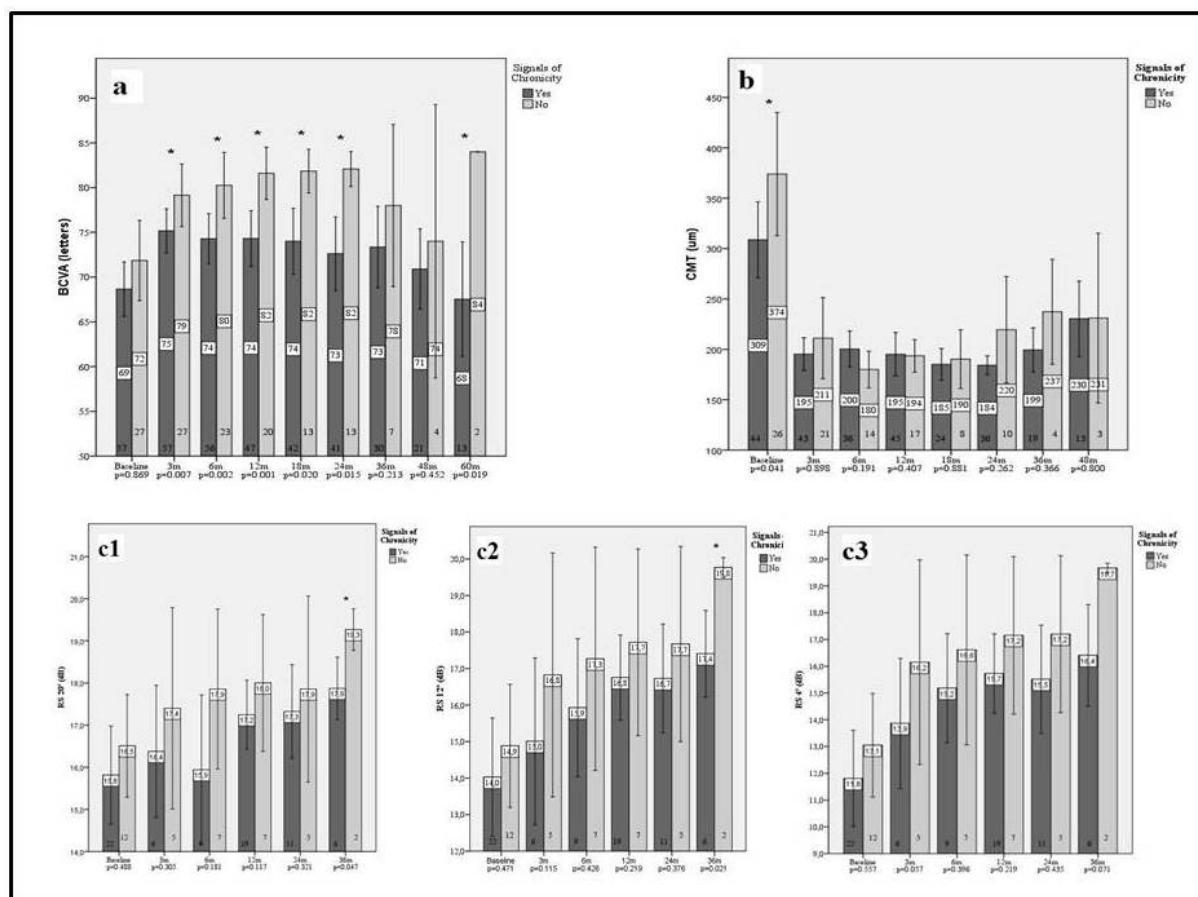


Figure 1: Comparison of best-corrected visual acuity (BCVA) (a), central macular thickness (CMT) (b), retinal sensitivity (RS) at 20 (c1), 12 (c2) and 4 (c3) central degrees between chronicity and no-chronicity groups. Error bars represent 95% Confidence Interval (CI). Numbers at bottom of the bars represent the number of patients included in the analyses at a specific time point. *marks statistically significant values (P<0.05, Mann – Whitney U test).

The number of post-treatment recurrences was significantly higher among the pre-treatment chronicity group (13 vs 1) (p=0.03, Fisher's exact test).

Recurrence versus no-recurrence

The baseline demographic and clinical characteristics of these 2 groups are summarized in Table 1 and Table 2. There were no significant differences between groups considering age and sex. Baseline mean BCVA and RS over central 4°, 12° and 20° was also similar. The recurrent group presented thinner baseline CMT (249.3 ± 104.9 μm) compared to non-recurrent patients (346.9 ± 138.5 μm) (p=0.017, Mann-Whitney U test). Among the 14 patients with one or more relapses, 13 presented signs of chronicity. Conversely, a total of 44 patients without relapse presented these same signals (p=0.03, Fisher's exact test). The follow up period was significantly longer in the recurrent group (p<0.05, t Test). Mean time to SRF resolution was similar in recurring and non-recurring patients. The mean number of recurrences was 1.43 (range 1 to 3). While a total of 9 eyes (64.3%) had

only one recurrence, 4 eyes (28.6%) had 2 and 1 eye (7.1%) had 3. The mean lapse of time since half-dose PDT to the first relapse was 20.3 ± 13.8 months (range 7 to 50). The gap since first PDT to the second relapse was 41.0 ± 21.0 months (range 16 to 71), while the third relapse occurred after 69 months. The only eye with relapse and no chronicity signals had a unique recurrent episode, presenting spontaneous resolution. Most of the relapses were treated with PDT; however, 3 eyes in the first relapse and 4 eyes in the second relapse were treated with focal laser photocoagulation since they presented unique leaking spots distant from the fovea.

In the recurrent group the baseline mean BCVA was 70.6 ± 10.8 letters (range 50 to 84 letters) and a significant improvement to 75.5 ± 8.3 letters was registered 3 months after PDT (p=0.009, Wilcoxon signed-rank test), whereas no significant differences were seen in any other time point (Figure 2). Mean CMT and mean RS remained stable along the time (Figure 2). There were no significant differences after the relapse treatment. No relevant differences were detected in BCVA, CMT and RS between patients with one or more recurrences.

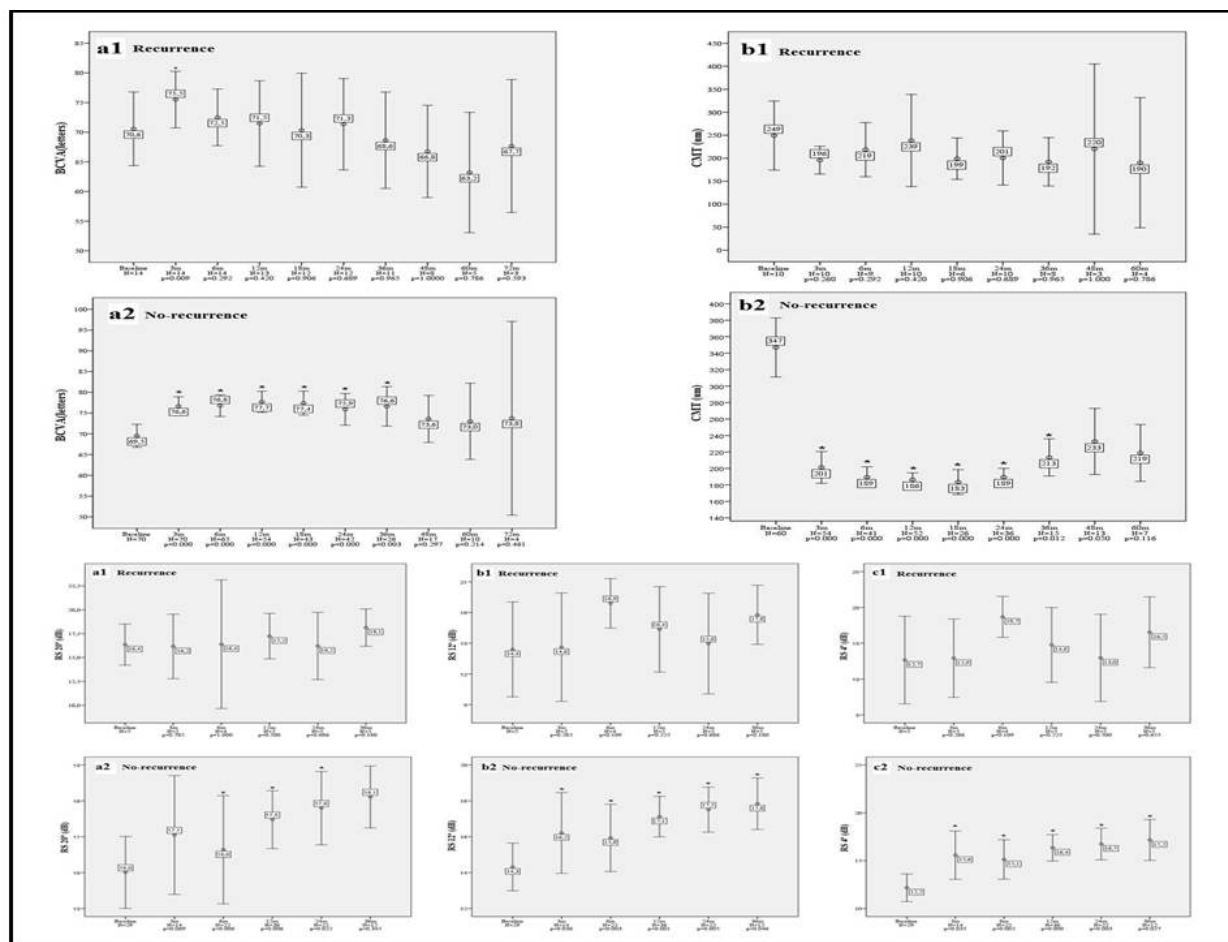


Figure 2: Upper-right-Best-corrected visual acuity (BCVA) outcomes compared to baseline in recurrent (a1) and no-recurrent patients (a2). Upper-left - Central macular thickness (CMT) outcomes compared to baseline in the recurrent (b1) and non-recurrent group (b2). Bottom - Retinal sensitivity (RS) at 20 (a), 12 (b) and 4 (c) central-degrees compared to the baseline value in patients with recurrent (a, b, c1) and without recurrent episodes (a, b, c2). Error bars represent 95% Confidence Interval (CI). N represent the number of patients included in the analyses at a specific time point. *marks statistically significantly values (P<0.05, Wilcoxon signed rank test).

In the non-recurrent group mean baseline BCVA was 69.5 ± 11.6 letters (range 35 to 85 letters) and mean CMT was $346.9 \pm 138.5 \mu\text{m}$. A significant improvement in BCVA and a decrease in CMT at months 3, 6, 1, 18, 24 and 36 after PDT were registered ($p < 0.05$, Wilcoxon signed-rank test), losing its significance beyond that period (Figure 2). RS over the central 4° and 12° also a significant increase at 3, 6, 1, 24 and 36 months ($p < 0.05$ for all time points, Wilcoxon signed-rank test). When analyzing the RS in a 20° central area, a significant increase was only detected at 6, 12 and 24 months ($p < 0.05$ for all time points, Wilcoxon signed-rank test) (Figure 2).

Comparing the post-treatment outcomes between both groups, recurrent patients evolved with lower BCVA in all the visits, however significant differences were only found at 6 and 36 months ($p = 0.039$ and $p = 0.043$, respectively, Mann-Whitney U test). Mean CMT and RS were similar between both groups along the follow-up period (Figure 3).

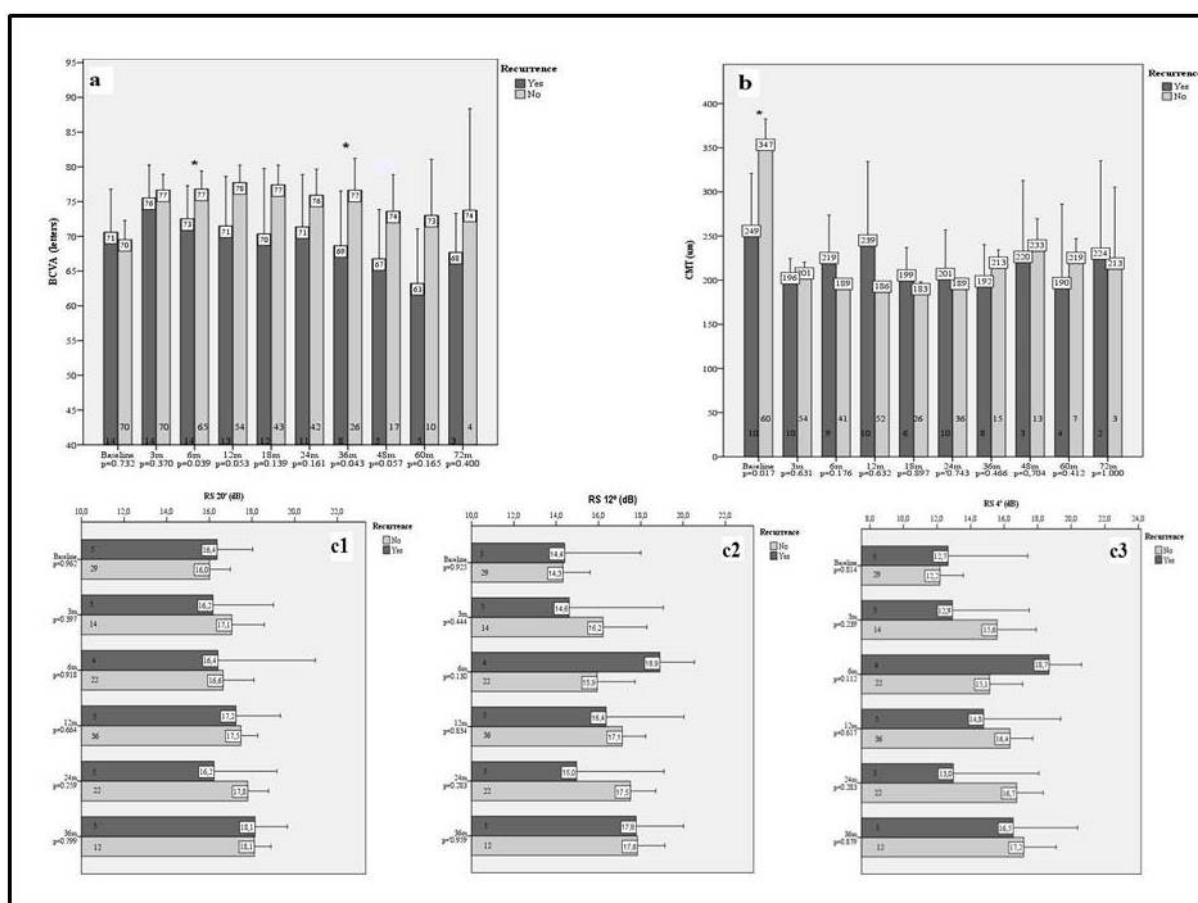


Figure 3: Comparison of best-corrected visual acuity (BCVA) (a), central macular thickness (CMT) (b), retinal sensitivity (RS) at 20 (c1), 12 (c2) and 4 (c3) central-degrees between recurrent and non-recurrent groups. Error bars represent 95% confidence interval (CI). Numbers at bottom of the bars represent the number of patients included in the analyses at a specific time point. *marks statistically significantly values ($P < 0.05$, Mann-Whitney U test).

Discussion

In the current study we evaluated the short and long-term functional and anatomical changes after half-dose PDT in CSC patients, comparing the outcomes considering the presence of pre-treatment chronicity signals and post-treatment relapse. We preferred not to categorize CSC patients into acute or chronic forms, since this classification is frequently ambiguous and misused. Patients frequently don't recall the beginning of their symptoms, making it difficult to establish a precise time point for the start of their condition. Even when they do, they are usually complaining of the visual disturbances caused by a macular detachment. It is not unusual to see other multiple

extrafoveal, and therefore asymptomatic, areas of RPE decompensation, revealing a more prolonged condition. Instead, we opted to classified them as having or not unequivocal chronicity signals, that suggested a more prolonged disease duration, in order to see if the outcomes were somehow different. Although performed by an experienced retinal specialist, this classification is somehow subjective as dependent on the observer. We somehow agree with the authors that recently proposed the terminology of "non-resolving" or "persistent" CSC for these ambiguous situations [2].

Recurrent and persistent forms of CSC can be a debilitating condition with significant visual impairment [1,2,6-10]. PDT has been

reported as a useful technique in the treatment of this condition, inducing a choroidal vascular remodeling, and ultimately a decrease in choroidal hyperpermeability [1,2,14-20]. However, the short-term choriocapillaris hypoperfusion has been associated with pigmentary changes, choroidal ischemia, RPE atrophy and secondary choroidal neovascularization (CNV) [14,15,17,33]. To avoid these complications, new treatment modalities using half-dose, half-fluence or half-time PDT regimens have been used with similar efficacy and a better safety profile [25-32]. Although, we have been assisting to a rising number of publications on the efficacy of PDT in CSC, there is still no consensus over the optimal timing for treatment or dose regimens. We showed that half dose PDT proved to be a safe procedure for CSC patients, either with or without chronicity signals. Patients with recurrence also presented a favorable evolution, even when multiple treatments were performed, enhancing the safety of this procedure. No serious ocular or systemic adverse events were reported, even with multiple treatments. In our practice we prefer half-dose regimens that allow the treatment of two regular-weight patients, sharing one verteporfin vial, thus minimizing the wastage of medication and conferring an economical advantage. Nicolo et al. have recently concluded that half-dose exceeds the half-fluence modality resulting in a more rapid resolution of sub-retinal fluid, with a more lasting effect, encouraging our choice [29].

Patients with chronicity signals were significantly older than patients with no-chronicity signals, (49.5 ± 9.2 vs. 43.0 ± 10.9 years respectively ($p=0.009$). Our results were concordant to some studies that showed that the peak prevalence is around 45 years, and in patients with chronic CSC, the peak tends to be higher. This is easily explained because the onset of the disease occurred years before its presentation, and asymptomatic patients are usually diagnosed in more advanced stages of disease, therefore more prone to present with some retinal atrophy [1-3]. Although, both baseline BCVA and RS were similar between both groups, the chronicity group presented a thinner CMT, which was expectable, and no significant differences were seen along the time when compared to their counterparts. Baseline thinner CMT could be interpreted as the result of either pre-treatment thinner retinas, consequence of a chronic disorder, by the presence of shallower detachments or both. Nevertheless, we must highlight that CMT was calculated based on the OCT software automatic measurement, measuring the distance from the RPE to the internal retinal surface. Both retinal and sub-retinal fluid thickness was included in this measurement, and we did not discriminate both values. Regarding the functional outcomes, BCVA was better in patients with no chronicity signs, especially for the first 2 years after PDT. Conversely, the difference in RS was not that evident, except at month 36 when it was significantly better over the central 12° and 20° in patients with no chronicity signals. These results were in agreement with the fact that patients with chronic neurosensory retinal detachment develop neurosensory retinal changes and RPE atrophy, those results in loss of visual function [7-12].

Despite the worse results in patients with chronicity signs, both groups presented an improvement in anatomical and functional outcomes over the follow-up period. This is in agreement with some previously published studies that showed short and long-term effectiveness of half dose PDT [26-32]. The RS improvement, when compared to baseline, was higher over the 4° , eccentrically decreasing towards the 20° , and this tendency was observed in both groups. Previous studies reported that some patients did not recover to normal RS levels; despite some improvement was seen [21-24]. A complete

recovery to normal BCVA levels is not always paired with a complete RS recovery, proving that visual function surpasses visual acuity.

The proportion of patients that recurred was higher in the chronicity group (22.8 vs. 3.7%) ($p=0.031$). In fact, recurrence and chronicity are somehow intrinsically related. Patients with more recurrences present more signs of chronicity and vice-versa. Chronically affected eyes tend to have weaker grips between photoreceptors and RPE, easily breaking under increasing choroidal pressure, resulting in recurrent or persistent neurosensory detachments [8,11,12]. Lee et al. recently found a positive correlation between the number of baseline retinal microstructural changes found on OCT as hyperreflective foci and the rate of post-treatment recurrence, although they used laser photocoagulation and not PDT [36]. Recently, Lay et al. published their long-term outcomes with half dose PDT in chronic CSC patients, comparing 75 treated with 117 untreated eyes, with a mean follow up of 74.1 months. They reported a significantly better visual acuity (1.8 vs. 0.0) and lower recurrence rate (20% vs. 53.8%) compared to controls [32]. We reported an inferior recurrence rate accounting for 16.7% of the studied eyes. Nevertheless, our mean follow-up was also shorter and the risk of recurrence should be somehow time-related. Tseng et al followed 56 half dose PDT treated eyes for a mean of 55.5 months, reporting 4 recurrences and 3 complications including the enlargement of retinal pigment epithelial atrophy in one case and choroidal neovascularisation in another two cases at 12 and 14 months after treatment [33]. Ozkaya et al. reported a lower recurrence rate with half-dose PDT than with spontaneous resolution (25% vs. 5.2%) in a sample of 77 eyes [34].

Despite all, there is still a lack of studies comparing the post-PDT anatomical and functional results in CSC patients with and without recurrence. In our study, time elapsing since treatment and the first recurrence was 20.3 ± 13.8 months. Recurrent eyes had a significantly higher percentage of chronicity signals (92.9%) when compared to the other group (62.9%) ($p=0.031$). They also presented lower baseline CMT ($p=0.017$). As previously discussed, the degenerative outer retina changes caused by the persistent sub-retinal fluid weaken the anchorage between retina and RPE, favoring recurrences [8,11,12]. When comparing the functional and anatomical progress along the follow-up period, long term assessment proved to be better in the group without recurrence, presenting an improvement in BCVA and mean RS and a decrease in mean CMT, but only statistically significant until the 36 month. Probably, this happened because patients with longer follow up periods presented more degenerative retinal changes. On the contrary, in the recurrent group there were no statistically significant differences in BCVA mean CMT or mean RS before and after PDT, except at month 3 follow-up visits when BCVA improved. These results suggest that patients with recurrent episodes present a worst evolution, probably caused by the summation of retinal and RPE injuries.

According to some studies, RS is significantly decreased in areas of RPE irregularity or ellipsoid disruption, and also has correlated with worst visual acuity [21]. As this study was started when using the stratus OCT, the baseline evaluation of the integrity of the external limiting membrane (ELM) and the ellipsoid was not feasible. Once these patients are recently being evaluated using an SD-OCT, the photoreceptors' layer analysis may help to understand some discrepancies found between anatomical and functional outcomes.

It is also nowadays accepted that the underlying choroidal thickness may be directly related to the occurrence of relapse. Oh et al recently showed a similar significant improvement in visual acuity and central

retinal thickness in both full and half fluence groups. However, at 1 year after treatment, full fluence treated eyes presented thinner choroids than half fluence counterparts, and that these last ones still presented thicker choroids than their fellow eye, contrarily to full fluence submitted eyes [21]. The clinical implications of this finding in a long-term assessment still remain to be determined. Kim et al. reported that PDT treated eyes with an incomplete SRF absorption or SRF recurrence presented a lower sub-foveal choroidal thickness decline at 1 month and a higher choroidal thickness throughout follow-up compared to those eyes without recurrence. However, these authors mixed half fluence and half dose regimens in their sample, potentially biasing the results [35]. Unfortunately we have no data on baseline choroidal thickness in a significant percentage of our sample, since we did not have a spectral-domain OCT on the beginning timeline of this study, and this is the reason why we did not analyze the choroidal thickness in this report.

In our study a correlation was found between recurrent episodes and baseline mean CMT, suggesting that patients with thinner retinas are more prone to suffer from another CSC episode. Some studies report that foveal thickness at presentation and after resolution correlate with visual acuity outcomes, those with more foveal thinning and atrophy have worse vision [35]. We found no association between recurrence rate and age, time to SRF resolution, baseline BCVA or baseline RS. The occurrence of the first relapse at around 20 months after PDT, suggests that this treatment, besides effective, reduces the recurrence rate at least for the first year, when comparing to the natural history [1-3]. After a second PDT, the time elapsing from the first to the second relapse was also around 20 months, meaning that a second treatment does not diminish its efficacy. Opposed to what we expected, no differences in anatomical and functional outcomes were found between patients with one or more relapses, although we are analyzing a short sample of patients. This seems rather controversial since we were hoping that increasing recurrences might lead to worst prognosis, as occurring in natural history. This intriguing finding might be due to either an earlier diagnosis or treatment since relapse, since these patients were scheduled for frequent follow-up visits.

There are some limitations in our study including the retrospective design of the study, the small sample, the lack of a control group and some missing follow-up data. Although our results seem relevant for the understanding of the role of recurrence and chronicity in the evolution of CSC, randomized, prospective studies with larger samples are needed to determine precise predictors of recurrence in order to determinate guidelines for CSC treatment in patients with or without chronicity signs.

In conclusion, half-dose PDT is an effective and safe treatment for CSC. However patients with pre-treatment chronicity signals and post-treatment recurrence had worst functional and morphological results, which seem to be related to the cumulative degenerative injuries affecting the neurosensory retina and RPE. Most of the patients with post-treatment recurrent episodes had baseline chronicity signals, which suggest that these factors are intrinsically related. Patients with these characteristics should be treated earlier in order to avoid poorer anatomical and functional outcomes.

Financial Disclosure

AC (Angela Carneiro) has participated in advisory boards for Alcon, Bayer, Novartis, and Alimera Sciences. The other authors report no conflicts of interest in this work.

References

1. Nicholson B, Noble J, Forooghian F, Meyerle C (2013) Central serous chorioretinopathy: update on pathophysiology and treatment. *Surv Ophthalmol* 58: 103-126.
2. Daruich A, Matet A, Dirani A, Bousquet E, Zhao M, et al. (2015) Central serous chorioretinopathy: Recent findings and new physiopathology hypothesis. *Prog Retin Eye Res* 48: 82-118.
3. Ross A, Ross AH, Mohamed Q (2011) Review and update of central serous chorioretinopathy. *Curr Opin Ophthalmol* 22: 166-173.
4. Prunte C, Flammer J (1996) Choroidal capillary and venous congestion in central serous chorioretinopathy. *Am J Ophthalmol* 121: 26-34.
5. Warrow DJ, Hoang QV, Freund KB (2013) Pachychoroid pigment epitheliopathy. *Retina* 33: 1659-1672.
6. Castro-Correia J, Coutinho MF, Rosas V, Maia J (1992) Long-term follow-up of central serous retinopathy in 150 patients. *Doc Ophthalmol* 81: 379-386.
7. Loo RH, Scott IU, Flynn HW, Gass JD, Murray TG, et al. (2002) Factors associated with reduced visual acuity during long-term follow-up of patients with idiopathic central serous chorioretinopathy. *Retina* 22: 19-24.
8. Piccolino FC, de la Longrais RR, Ravera G, Eandi CM, Ventre L, et al. (2005) The foveal photoreceptor layer and visual acuity loss in central serous chorioretinopathy. *Am J Ophthalmol* 139: 87-99.
9. Baran NV, Gürlü VP, Egin H (2005) Long-term macular function in eyes with central serous chorioretinopathy. *Clin Exp Ophthalmol* 33: 369-372.
10. Folk JC, Thompson HS, Han DP, Brown CK (1984) Visual function abnormalities in central serous retinopathy. *Arch Ophthalmol* 102: 1299-1302.
11. Ooto S, Tsujikawa A, Mori S, Tamura H, Yamashiro K, et al. (2011) Retinal microstructural abnormalities in central serous chorioretinopathy and polypoidal choroidal vasculopathy. *Retina* 31: 527-534.
12. Ooto S, Hangai M, Sakamoto A, Tsujikawa A, Yamashiro K, et al. (2010) High-resolution imaging of resolved central serous chorioretinopathy using adaptive optics scanning laser ophthalmoscopy. *Ophthalmology* 117: 1800-1809.
13. Song IS, Shin YU, Lee BR (2012) Time-periodic characteristics in the morphology of idiopathic central serous chorioretinopathy evaluated by volume scan using spectral-domain optical coherence tomography. *Am J Ophthalmol* 154: 366-375.
14. Yannuzzi LA, Slakter JS, Gross NE, Spaide RF, Costa D, et al. (2003) Indocyanine green angiography-guided photodynamic therapy for treatment of chronic central serous chorioretinopathy: a pilot study. *Retina* 23: 288-298.
15. Chan WM, Lam DS, Lai TY, Tam BS, Liu DT, et al. (2003) Choroidal vascular remodelling in central serous chorioretinopathy after indocyanine green guided photodynamic therapy with verteporfin: a novel treatment at the primary disease level. *Br J Ophthalmol* 87: 1453-1458.
16. Ma J, Meng N, Xu X, Zhou F, Qu Y (2014) System review and meta-analysis on photodynamic therapy in central serous chorioretinopathy. *Acta Ophthalmol* 92: e594-601.
17. Hua R, Liu L, Li C, Chen L (2014) Evaluation of the effects of photodynamic therapy on chronic central serous chorioretinopathy based on the mean choroidal thickness and the lumen area of abnormal choroidal vessels. *Photodiagnosis Photodyn Ther* 11: 519- 525.
18. Oh BL, Yu HG (2015) Choroidal Thickness After Full-Fluence And Half-Fluence Photodynamic Therapy In Chronic Central Serous Chorioretinopathy. *Retina* 35: 1555-1560.
19. Inoue R, Sawa M, Tsujikawa M, Gomi F (2010) Association between the efficacy of photodynamic therapy and indocyanine green angiography findings for central serous chorioretinopathy. *Am J Ophthalmol* 149: 441-446.
20. Vasconcelos H, Marques I, Santos AR, Melo P, Pires I, et al. (2013) Long-term chorioretinal changes after photodynamic therapy for chronic

- central serous chorioretinopathy. *Graefes Arch Clin Exp Ophthalmol* 251: 1697-1705.
21. Kim SW, Oh J, Huh K (2012) Correlations among various functional and morphological tests in resolved central serous chorioretinopathy. *Br J Ophthalmol* 96: 350-355.
 22. Reibaldi M, Boscia F, Avitabile T, Uva MG, Russo A, et al. (2011) Functional retinal changes measured by microperimetry in standard-fluence vs low-fluence photodynamic therapy in chronic central serous chorioretinopathy. *Am J Ophthalmol* 151: 953-960.
 23. Fujita K, Yuzawa M, Mori R (2011) Retinal sensitivity after photodynamic therapy with half-dose verteporfin for chronic central serous chorioretinopathy: short-term results. *Retina* 31: 772-778.
 24. Senturk F, Karacorlu M, Ozdemir H, Karacorlu SA, Uysal O (2011) Microperimetric changes after photodynamic therapy for central serous chorioretinopathy. *Am J Ophthalmol* 151: 303-309.
 25. Reibaldi M, Cardascia N, Longo A, Furino C, Avitabile T, et al. (2010) Standard-fluence versus low-fluence photodynamic therapy in chronic central serous chorioretinopathy: a nonrandomized clinical trial. *Am J Ophthalmol* 149: 307-315.
 26. Chan WM, Lai TY, Lai RY, Liu DT, Lam DS (2008) Half-dose verteporfin photodynamic therapy for acute central serous chorioretinopathy: one-year results of a randomized controlled trial. *Ophthalmology* 115: 1756-1765.
 27. Karakus SH, Basarir B, Pinarci EY, Kirandi EU, Demirok A (2013) Long-term results of half-dose photodynamic therapy for chronic central serous chorioretinopathy with contrast sensitivity changes. *Eye (Lond)* 27: 612-620.
 28. Kim KS, Lee WK, Lee SB (2014) Half-dose photodynamic therapy targeting the leakage point on the fluorescein angiography in acute central serous chorioretinopathy: a pilot study. *Am J Ophthalmol* 157: 366-373.
 29. Nicoló M, Eandi CM, Alovici C, Grignolo FM, Traverso CE, et al. (2014) Half-fluence versus half-dose photodynamic therapy in chronic central serous chorioretinopathy. *Am J Ophthalmol* 157: 1033-1037.
 30. Zhao M, Zhang F, Chen Y, Dai H, Qu J, et al. (2015) A 50% vs 30% dose of verteporfin (photodynamic therapy) for acute central serous chorioretinopathy: one-year results of a randomized clinical trial. *JAMA Ophthalmol* 133: 333-340.
 31. Liu HY, Yang CH, Yang CM, Ho TC, Lin CP, et al. (2016) Half-dose Versus Half-time Photodynamic Therapy for Central Serous Chorioretinopathy. *Am J Ophthalmol* 167: 57-64.
 32. Lai TY, Wong RL, Chan WM (2015) Long-Term Outcome of Half-Dose Verteporfin Photodynamic Therapy for the Treatment of Central Serous Chorioretinopathy (An American Ophthalmological Society Thesis). *Trans Am Ophthalmol Soc* 113: T81-81T827.
 33. Tseng CC, Chen SN (2015) Long-term efficacy of half-dose photodynamic therapy on chronic central serous chorioretinopathy. *Br J Ophthalmol* 99: 1070-1077.
 34. Ozkaya A, Alkin Z, Ozveren M, Yazici AT, Taskapili M (2016) The time of resolution and the rate of recurrence in acute central serous chorioretinopathy following spontaneous resolution and low-fluence photodynamic therapy: a case-control study. *Eye*.
 35. Kim YK, Ryoo NK, Woo SJ, Park KH (2015) Choroidal Thickness Changes After Photodynamic Therapy and Recurrence of Chronic Central Serous Chorioretinopathy. *Am J Ophthalmol* 160: 72-84.
 36. Lee H, Lee J, Chung H, Kim HC (2015) Baseline spectral domain optical coherence tomography hyperreflective foci as predictor of visual outcome and recurrence for central serous chorioretinopathy. *Retina*.