

## Clinicopathological Significance of Fatty Acid Synthase Expression in Carcinoma of the Ampulla of Vater

Hiroshi Maekawa\*, Tomoaki Ito, Tomoyuki Kushida, Hajime Orita, Mutsumi Sakurada and Koichi Sato

Department of Surgery, Juntendo university school of medicine Shizuoka hospital, 1129, Nagaoka, Izu-no-kuni, Shizuoka, Japan

\*Corresponding author: Hiroshi Maekawa, Department of Surgery, Juntendo university school of medicine Shizuoka hospital, 1129, Nagaoka, Izu-no-kuni, Shizuoka, Japan, Tel: 81 559483111; Fax: 81 559460514; E-mail: [hmaekawa0201@gmail.com](mailto:hmaekawa0201@gmail.com)

Rec date: Jan 2, 2015, Acc date: Jan 19, 2015, Pub date: Jan 30, 2015

Copyright: © 2015 Maekawa H, et al. This is an open-access article distributed under the terms of the Creative Commons Attribution License, which permits unrestricted use, distribution, and reproduction in any medium, provided the original author and source are credited.

### Abstract

**Objective:** Increased fatty acid synthase (FAS) expression is detected in various cancers. It has been demonstrated that the intensity of FAS expression in cancer correlates with clinical outcome. Here, we investigated whether FAS expression in carcinoma of the ampulla of Vater has any relationship to clinical or pathological features.

**Methods:** We studied 32 patients surgically treated for carcinoma of the ampulla of Vater in our hospital. We compared FAS immunohistochemical staining with other pathological features, including Ki-67, p53, and MUC1, and 2 staining, and with clinical findings.

**Results:** Of these 32 cases, 16 were considered FAS-positive under our criteria. Pathologically, FAS positivity was correlated to Ki-67 positivity ( $p: 0.0045$ ), but there was no significant relationship between FAS expression and p53 staining ( $p: 0.6715$ ). FAS-positive cases showed a higher rate of lymph node metastases ( $p: 0.0373$ ). However, FAS expression was not related to tumor size, differentiation of adenocarcinoma, duodenal invasion, pancreatic invasion and MUC1 or MUC2 positivity. Clinically, the disease survival rate and the overall survival rate of FAS-positive cases was lower than that of FAS-negative ones ( $p: 0.0365, 0.0007$ ).

**Conclusion:** Histological FAS expression is related to aggressiveness of cancer of the ampulla of Vater and FAS expression can be considered to be a prognostic marker in cancer of the ampulla of Vater.

**Keywords:** Cancer; The ampulla of Vater; Fatty acid synthase; Immunohistochemistry; Prognosis

### Introduction

Fatty acid synthase (FAS) expression is normally regulated and inhibited by several hormones in normal tissues [1] and FAS is usually expressed in hormone-sensitive and high-lipid-metabolism cells in humans [2]. Overexpression of FAS was initially reported in breast cancer [3]. Subsequently, increased FAS expression was also reported in various other cancers [4-7]. FAS expression increases the de novo biosynthesis of fatty acids, which contributes to tumor cellular activities [8]; as well as metabolism for energy production, building cellular membranes, and intracellular secondary messengers [9,10]. It has been demonstrated that the intensity of FAS expression in cancer correlates with clinical outcome [4,11-16]. That is, cases with high FAS expression often show poor prognoses in various kinds of cancer [4,11-16].

Biliary tract cancer is regarded as one of the cancers with poor prognoses in clinical practice [17]. Carcinoma of the ampulla of Vater is one of the carcinomas that occur in the biliary tract. The prognosis of carcinoma of the ampulla of Vater is considered to be better than those of carcinomas derived from other parts of the biliary tract or pancreatic head [17-19]. However, recurrence of carcinoma of the ampulla of Vater occurs even though the curative resection has been performed [17-19].

However, FAS expression in cancer of the ampulla of Vater has not been reported. It is unclear whether FAS is also expressed in carcinoma of the ampulla of Vater, and whether FAS expression has any relationship to the clinical outcome of this type of carcinoma. The aim of this study is thus to investigate the relationship between the expression of FAS and clinicopathological features using immunohistochemistry in carcinoma of the ampulla of Vater. Then, we considered whether FAS could be regarded as a prognostic marker in this type of carcinoma.

### Materials and Methods

#### Samples

We studied 32 patients who underwent resection for carcinoma of the ampulla of Vater between January 2002 and January 2014 in our hospital. Pathological diagnoses were performed by hematoxylin and eosin staining. We investigated the expression of FAS, Ki-67, p53, and MUC1, and MUC2 on tissue sections cut from carcinoma specimens formalin-fixed and paraffin-embedded by immunohistochemical staining. Pathological aspects, tumor size, node metastases, tumor differentiation, duodenal invasion, pancreatic invasion, Ki-67, p53 staining, and MUC1, and MUC2 expression were also compared with FAS expression. We compared FAS expression with clinical information. Clinical data such as gender, age, preoperative serum CA19-9 level, diabetes mellitus complication and prognoses were obtained from the clinical records. The study protocol conformed to

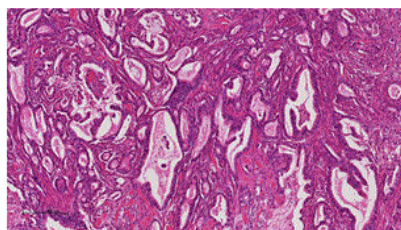
the ethical guidelines of the World Medical Association Declaration of Helsinki, and has been approved by the ethical committee of our hospital.

### Immunohistochemical studies

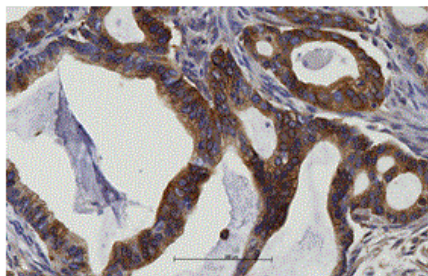
We used 4- $\mu$ m tissue sections cut from specimens that had been formalin-fixed and paraffin-embedded. Immunohistochemical staining was performed using an automated slide stainer (Bench-Mark XT; Ventana Medical Systems Inc., Tucson, AZ) [20,21]. Anti-human FAS rabbit IgG was obtained from Immuno-Biological Laboratories Co., Ltd. (Fujioka, Gunma, Japan). Monoclonal mouse anti-human Ki-67 and p53 antigens were obtained from Dako (Carpinteria, CA, USA). Monoclonal mouse anti-human MUC1 and MUC2 antigens were obtained from Dako (Carpinteria, CA, USA).

Staining intensity was measured according to the classification previously described [22,23], as 0, negative staining; 1+, low staining for up to 1/3 of cells stained; 2+, moderate staining for up to 2/3 of cells stained; and 3+, intense staining for more than 2/3 of cells stained. For statistical analysis we used a method that the results were dichotomized as high (3+ and 2+) or low (1+ and 0) expression (Figures 1-5).

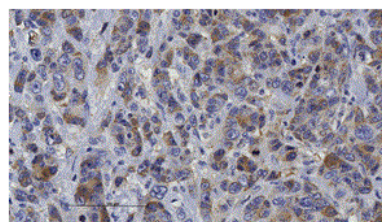
Cancer of the ampulla of Vater expressed MUC1 or MUC2. MUC1-positive cases were determined as those predominantly stained with MUC1 antibody. MUC2-positive cases were determined in the same fashion.



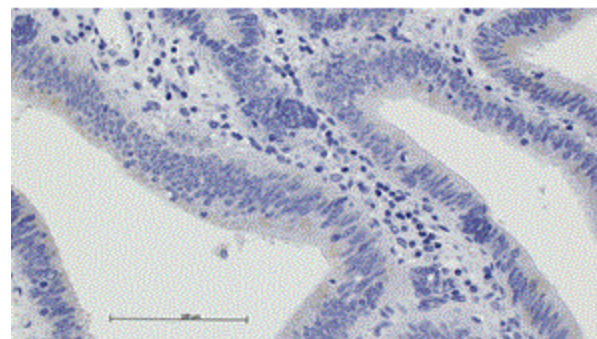
**Figure 1:** Histological findings of carcinoma of the ampulla of Vater. Tubular adenocarcinoma stained with hematoxylin-eosin. Scale bar: 200  $\mu$ m.



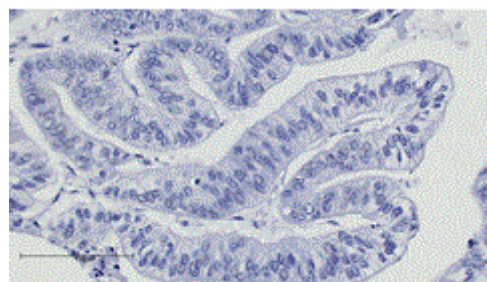
**Figure 2:** Immunohistochemical FAS staining of 3+ sample (Figure 1) – positively stained cells were more than 2/3 of cancer cells. Scale bar: 100  $\mu$ m.



**Figure 3:** Immunohistochemical FAS staining of 2+ sample – positively stained cells were more than 1/3 and less than 2/3 of cancer cells. Scale bar: 100  $\mu$ m.



**Figure 4:** Immunohistochemical FAS staining of 1+ sample – stained cells were in less than 1/3 of cancer cells.



**Figure 5:** Immunohistochemical FAS staining of 0 sample – stained cells were not seen. Scale bar: 100  $\mu$ m.

### Statistical analysis

Relationships of the scores of tissue FAS expression and those of tissue Ki-67 expression or those of tissue p53 expression were analyzed using Spearman's correlation coefficient by rank test. Cut-off end-points were determined according to positive and negative immunohistochemical tissue FAS expressions observed. FAS positivity was tested for association with clinicopathological features using Fisher's exact test or Mann-Whitney's test. Overall survival rate and disease-free survival rate were plotted using the Kaplan-Meier method.

These survival rates were analyzed using log-rank test. All analyses were conducted using the GraphPad Prism5® statistical software package (GraphPad Software Inc., La Jolla, CA, USA).

We estimated survival based on FAS expression patterns using the Kaplan-Meier analysis and compared survival between groups using log-rank tests. A p value less than 0.05 was considered significant.

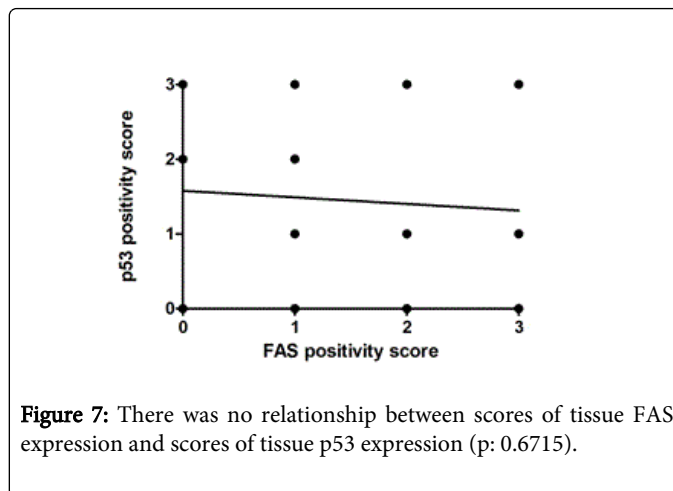
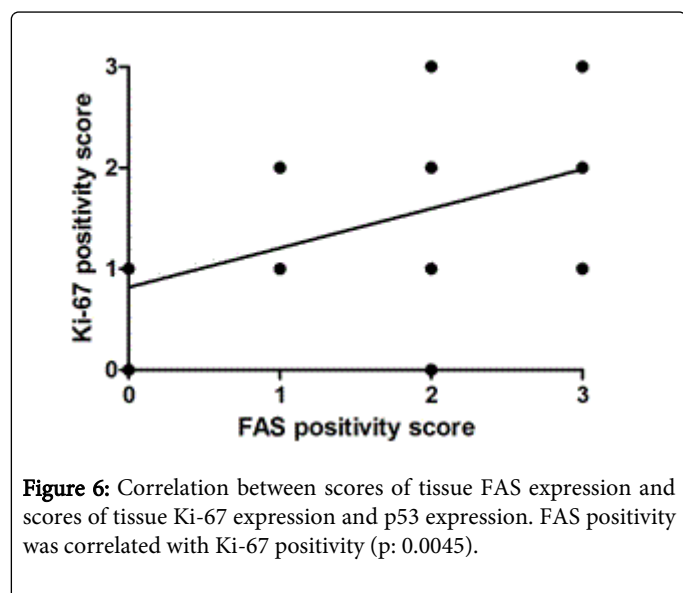
## Results

The clinical features of the 32 cases were listed (Table 1). All 32 cases had adenocarcinoma and recurrences were noted in 10 patients, and they died due to carcinoma of the ampulla of Vater. A total of 16 cases were positive for FAS staining and 16 were negative.

Gender (Male/Female)	16 / 16
Age (mean)	66.9
Clinical Stages (UICC 6th edition) (cases)	IA 7 / IB 12 / IIA 5 / IIB 5 / IV 3
Recurrence (cases)	10
Follow-up (month)	46.8 (2-166)
Number of cases with each score (FAS staining score 0/1/2/3)	9/7/10/6

**Table 1:** Clinical Features of 32 Carcinoma of the Ampulla of Vater Cases.

The correlation between scores of tissue FAS expression and scores of tissue Ki-67 expression was analyzed (Figures 6 and 7). FAS positivity was correlated with Ki-67 positivity (p: 0.0045). Next, we analyzed the correlation between scores of tissue FAS expression and scores of tissue p53 expression. There was no relationship between these two variables (p: 0.6715).



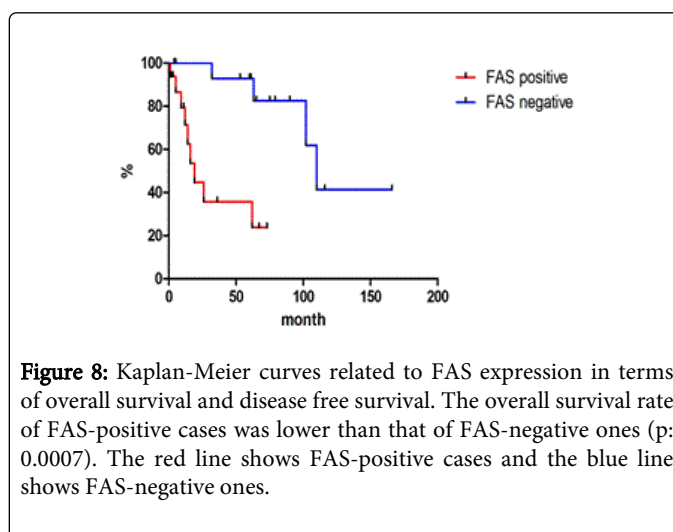
Pathological features of carcinoma of the ampulla of Vater according to FAS positivity were listed on Table 2. FAS-positive cases showed higher rates of lymph node metastases (p: 0.0373). However, FAS expression was not related to tumor size, differentiation of adenocarcinoma, duodenal invasion, pancreatic invasion.

There were no significant differences between the two groups in terms of Ki-67 positivity, p53 positivity. MUC1-positive cases were seventeen and MUC2-positive cases were fifteen. Ten cases (58.8 %) were FAS-positive in MUC1-positive cases.

6 cases (40%) were FAS-positive in MUC2-positive cases. There was no significant difference between FAS positivity and MUC1 or MUC2 positivity.

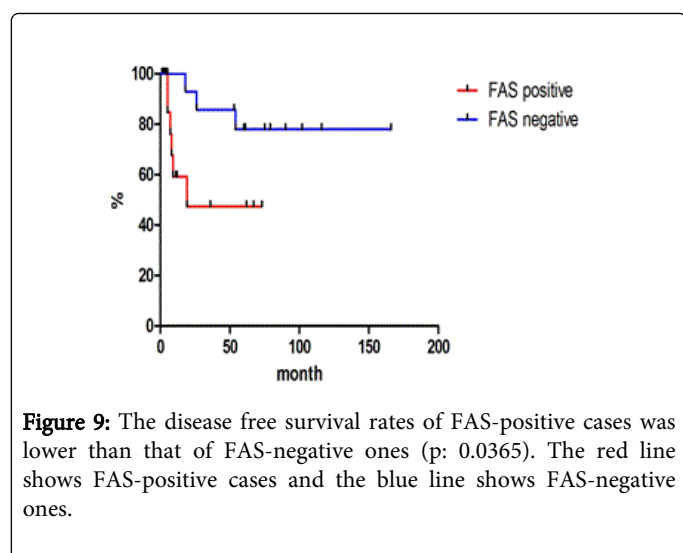
The clinical features of the two groups were also analyzed. There were no significant differences between the two groups in terms of gender, age, and preoperative level of CA19-9, diabetes mellitus complication. Recurrences were seen in both FAS-positive and FAS-negative groups.

Overall survival rate and disease-free survival are shown using the Kaplan-Meier method in Figures 8 and 9. The overall survival rate and the disease survival rate of FAS-positive cases were lower than that of FAS-negative ones (p: 0.0007, 0.0365).



Pathological features	FAS-positive 16 cases	FAS-negative 16 cases	p value
Tumor size (mm)	24.7	21.1	0.4672
Node metastasis (%)	43.8	6.3	0.0373
Differentiation (well/moderate/poor)	14/2/0	12/2/2002	0.3406
Ki-67 positivity (%)	62.5	43.8	0.4795
P53 positivity (%)	31.3	62.5	0.1556
Duodenal invasion	81.3	56.3	0.2524
Pancreatic invasion	37.5	18.8	0.4331
MUC 1 / MUC 2	6-Oct	9-Jul	0.4595

**Table 2:** Pathological features of carcinoma of the ampulla of Vater according to FAS immunohistochemical staining.



**Figure 9:** The disease free survival rates of FAS-positive cases was lower than that of FAS-negative ones (p: 0.0365). The red line shows FAS-positive cases and the blue line shows FAS-negative ones.

## Discussion

Pathological prognostic factors of carcinoma of the ampulla of Vater have been reported including lymph node metastases [24-28], ulceration form [25-27,29], tumor differentiation [27] and tumor size [25]. These factors are clinically convenient and useful for management of patients of carcinoma of the ampulla of Vater.

Furthermore, immunohistochemical researches to detect the prognostic factors of this type of cancer have been studied and reported. MIB-1 labeling index and p53 were investigated, same as in this study. Shyr et al. reported that MIB-1 index had prognostic value in resectable carcinoma of the ampulla of Vater, although they did not show the relationship between MIB-1 index and clinical stage and lymph node metastases [30]. The prognostic value of p53 expression has also been reported in several manuscripts. However, it was not clear whether p53 had a possible role in predicting survival [31-35].

Immunohistochemical analyses on the expression of keratin, apomucin subtypes for detecting prognostic factors of carcinoma of the ampulla of Vater have been performed, and those immunohistochemical features were related to the prognoses of carcinoma of the ampulla of Vater [28,29,36,37]. Kimura et al.

demonstrated that analysis using keratin7 and MUC2 was useful for the prediction of prognoses in cases of carcinoma of the ampulla of Vater [36,37]. They concluded that prognoses of keratin7-positive cases showed worse than those of MUC2-positive cases. That meant that pancreatobiliary-type adenocarcinoma was highly aggressive compared with the intestinal-type. They also reported pancreatobiliary-type carcinomas showed more frequent involvement of lymph nodes that was responsible for the shorter survival time. However, Catrer et al. reported that there was no significant difference in node metastases between pancreatobiliary-type and intestinal-type [28]. Relation node metastasis and pancreatobiliary- or intestinal-subtypes classification is considered to be still controversial.

In this study, we found that FAS expression is associated with tumor aggressiveness in carcinoma of the ampulla of Vater and had relation to lymph node metastases and their prognoses. That is, FAS expression in carcinoma of the ampulla of Vater is also useful for predicting prognosis, the same as in MIB-1 labeling index and keratin, apomucin subtypes [28,30,36,37]. Our result showed FAS expression had a significant relation to Ki-67 expression and node metastases. However, we could not find any significant relationship between MUC1 or MUC2 positivity and FAS positivity. Our study contains a small number of samples, so we need to accumulate more cases for further consideration in order to determine the relationship between pancreatobiliary- or intestinal- subtypes classification and FAS expression.

Recently, FAS has been said to play an important role not only in tumor growth, but also in drug resistance [38,39]. Both cellular proliferation and drug resistance can contribute cancer survival. These abilities are based of elevated FAS activity [40]. From previous reports and our results, it is suspected that FAS expression is related to cancer aggressiveness. FAS-positive expression can be considered to be a prognostic marker of cancer.

## Conclusion

FAS expression may be related to clinical behavior in carcinoma of the ampulla of Vater. Histologically, positive FAS expression related to high incidence of lymph node metastases and poor prognoses. Histological FAS expression can be a prognostic factor in carcinoma of the ampulla of Vater same as other types of carcinoma.



## References

1. Sul HS, Wang D (1998) Nutritional and hormonal regulation of enzymes in fat synthesis: studies of fatty acid synthase and mitochondrial glycerol-3-phosphate acyltransferase gene transcription. *Annu Rev Nutr* 18: 331-351.
2. Kusakabe T, Maeda M, Hoshi N, Sugino T, Watanabe K, et al. (2000) Fatty acid synthase is expressed mainly in adult hormone-sensitive cells or cells with high lipid metabolism and in proliferating fetal cells. *J Histochem Cytochem* 48: 613-622.
3. Kuhajda FP, Piantadosi S, Pasternack GR (1989) Haptoglobin-related protein (Hpr) epitopes in breast cancer as a predictor of recurrence of the disease. *N Engl J Med* 321: 636-641.
4. Alo' PL, Visca P, Marci A, Mangoni A, Botti C, et al. (1996) Expression of fatty acid synthase (FAS) as a predictor of recurrence in stage I breast carcinoma patients. *Cancer* 77: 474-482.
5. Wang YY, Kuhajda FP, Li J, Finch TT, Cheng P, et al. (2004) Fatty acid synthase as a tumor marker: its extracellular expression in human breast cancer. *J Exp Ther Oncol* 4: 101-110.
6. Van de Sande T, Roskams T, Lerut E, Joniau S, Van Poppel H, et al. (2005) High-level expression of fatty acid synthase in human prostate cancer tissues is linked to activation and nuclear localization of Akt/PKB. *J Pathol* 206: 214-219.
7. Shah US, Dhir R, Gollin SM, Chandran UR, Lewis D, et al. (2006) Fatty acid synthase gene overexpression and copy number gain in prostate adenocarcinoma. *Hum Pathol* 37: 401-409.
8. Kuhajda FP (2006) Fatty acid synthase and cancer: new application of an old pathway. *Cancer Res* 66: 5977-5980.
9. Liu H, Liu JY, Wu X, Zhang JT (2010) Biochemistry, molecular biology, and pharmacology of fatty acid synthase, an emerging therapeutic target and diagnosis/prognosis marker. *Int J Biochem Mol Biol* 1: 69-89.
10. Mashima T, Seimiya H, Tsuruo T (2009) De novo fatty-acid synthesis and related pathways as molecular targets for cancer therapy. *Br J Cancer* 100: 1369-1372.
11. Gansler TS, Hardman W 3rd, Hunt DA, Schaffel S, Hennigar RA (1997) Increased expression of fatty acid synthase (OA-519) in ovarian neoplasms predicts shorter survival. *Hum Pathol* 28: 686-692.
12. Shurbaji MS, Kalbfleisch JH, Thurmond TS (1996) Immunohistochemical detection of a fatty acid synthase (OA-519) as a predictor of progression of prostate cancer. *Hum Pathol* 27: 917-921.
13. Visca P, Sebastiani V, Botti C, Diodoro MG, Lasagni RP, et al. (2004) Fatty acid synthase (FAS) is a marker of increased risk of recurrence in lung carcinoma. *Anticancer Res* 24: 4169-4173.
14. Sebastiani V, Visca P, Botti C, Santeusano G, Galati GM, et al. (2004) Fatty acid synthase is a marker of increased risk of recurrence in endometrial carcinoma. *Gynecol Oncol* 92: 101-105.
15. Ogino S, Noshio K, Meyerhardt JA, Kirkner GJ, Chan AT, et al. (2008) Cohort study of fatty acid synthase expression and patient survival in colon cancer. *J Clin Oncol* 26: 5713-5720.
16. Alo PL, Amini M, Piro F, Pizzuti L, Sebastiani V, et al. (2007) Immunohistochemical expression and prognostic significance of fatty acid synthase in pancreatic carcinoma. *Anticancer Res* 27: 2523-2527.
17. Schmidt CM, Powell ES, Yiannoutsos CT, Howard TJ, Wiebke EA, et al. (2004) Pancreaticoduodenectomy: a 20-year experience in 516 patients. *Arch Surg* 139: 718-725.
18. Sommerville CA, Limongelli P, Pai M, Ahmad R, Stamp G, et al. (2009) Survival analysis after pancreatic resection for ampullary and pancreatic head carcinoma: an analysis of clinicopathological factors. *J Surg Oncol* 100: 651-656.
19. Howe JR, Klimstra DS, Moccia RD, Conlon KC, Brennan MF (1998) Factors predictive of survival in ampullary carcinoma. *Ann Surg* 228: 87-94.
20. Rosenbaum L, Fekrazad MH, Rabinowitz I, Vasef MA (2009) Epstein-Barr virus-associated inflammatory pseudotumor of the spleen: report of two cases and review of the literature. *J Hematop* 2: 127-131.
21. Kataoka Y, Okabe H, Yoshizawa A, Minamiguchi S, Yoshimura K, et al. (2013) HER2 expression and its clinicopathological features in resectable gastric cancer. *Gastric Cancer* 16: 84-93.
22. Ferreira SA, Vasconcelos JL, Silva RC, Cavalcanti CL, Bezerra CL, et al. (2013) Expression patterns of Î±2,3-sialyltransferase I and Î±2,6-sialyltransferase I in human cutaneous epithelial lesions. *Eur J Histochem* 57: e7.
23. Clark ATR, Guimaraes da Costa VML, Costa LB, Cavalcanti CLB, de Melo Rego MJB et al. (2014) Differential expression patterns of N-acetylglucosaminyl transferases and polyactosamines in uterine lesions. *Eur J Histochem* 58: 152-157.
24. de Castro SM, van Heek NT, Kuhlmann KF, Busch OR, Offerhaus GJ, et al. (2004) Surgical management of neoplasms of the ampulla of Vater: local resection or pancreaticoduodenectomy and prognostic factors for survival. *Surgery* 136: 994-1002.
25. Madjov R, Chervenkov P (2003) Carcinoma of the papilla of Vater. Diagnostic and surgical problems. *Hepatogastroenterology* 50: 621-624.
26. Moriya T, Kimura W, Hirai I, Mizutani M, Ma J, et al. (2006) Nodal involvement as an indicator of postoperative liver metastasis in carcinoma of the papilla of Vater. *J Hepatobiliary Pancreat Surg* 13: 549-555.
27. Park JS, Yoon DS, Kim KS, Choi JS, Lee WJ, et al. (2007) Factors influencing recurrence after curative resection for ampulla of Vater carcinoma. *J Surg Oncol* 95: 286-290.
28. Carter JT, Grenert JP, Rubenstein L, Stewart L, Way LW (2008) Tumors of the ampulla of vater: histopathologic classification and predictors of survival. *J Am Coll Surg* 207: 210-218.
29. Fischer HP, Zhou H (2004) Pathogenesis of carcinoma of the papilla of Vater. *J Hepatobiliary Pancreat Surg* 11: 301-309.
30. Shyr YM, Su CH, Wu LH, Li AF, Chiu JH, et al. (1999) Prognostic value of MIB-1 index and DNA ploidy in resectable ampulla of Vater carcinoma. *Ann Surg* 229: 523-527.
31. Santini D, Tonini G, Vecchio FM, Borzomati D, Vincenzi B, et al. (2005) Prognostic value of Bax, Bcl-2, p53, and TUNEL staining in patients with radically resected ampullary carcinoma. *J Clin Pathol* 58: 159-165.
32. Park SH, Kim YI, Park YH, Kim SW, Kim KW, et al. (2000) Clinicopathologic correlation of p53 protein overexpression in adenoma and carcinoma of the ampulla of Vater. *World J Surg* 24: 54-59.
33. Ajiki T, Kamigaki T, Hasegawa Y, Fujino Y, Suzuki Y, et al. (2001) Proliferating cell nuclear antigen, p53, and c-erbB-2 expression in relation to clinicopathological variables and prognosis in cancer of the ampulla of Vater. *Hepatogastroenterology* 48: 1266-1270.
34. Takashima M, Ueki T, Nagai E, Yao T, Yamaguchi K, et al. (2000) Carcinoma of the ampulla of Vater associated with or without adenoma: a clinicopathologic analysis of 198 cases with reference to p53 and ki-67 immunohistochemical expression. *Mod Pathol* 13: 1300-1307.
35. Guo R, Overman M, Chatterjee D, Rashid A, Shroff S, et al. (2014) Aberrant expression of p53, p21, cyclin D1, and bcl2 and their clinicopathological correlation in ampullary adenocarcinoma. *Human Pathol* 45: 1015-1023.
36. Kimura W, Futakawa N, Zhao B (2004) Neoplastic diseases of the papilla of Vater. *J Hepatobiliary Pancreat Surg* 11: 223-231.
37. Kimura W, Futakawa N, Yamagata S, Wada Y, Kuroda A, et al. (1994) Different clinicopathologic findings in two histologic types of carcinoma of papilla of Vater. *Jpn J Cancer Res* 85: 161-166.
38. Liu H, Liu Y, Zhang JT (2008) A new mechanism of drug resistance in breast cancer cells: fatty acid synthase overexpression-mediated palmitate overproduction. *Mol Cancer Ther* 7: 263-270.
39. Yang Y, Liu H, Li Z, Zhao Z, Yip-Schneider M, et al. (2011) Role of fatty acid synthase in gemcitabine and radiation resistance of pancreatic cancers. *Int J Biochem Mol Biol* 2: 89-98.
40. Mounier C, Bouraoui L, Rassart E (2014) Lipogenesis in cancer progression (review). *Int J Oncol* 45: 485-492.