

Comparative Clinical Results of Phacoemulsification Combined with CO₂ Laser-Assisted Sclerectomy vs. Phacoemulsification Combined with Trabeculectomy in Patients with Open-Angle Glaucoma

Juan Carlos Izquierdo Villavicencio*, Fabiola Patricia Quezada Baltodano, Imelda María Ramírez Jiménez, Ana Luisa González Méndez and María Corina Ponte-Dávila

Department of Ophthalmology, Research Department Oftalmosalud Eye Institute, Lima-Peru, Av. Javier Prado Este 1142, San Isidro, Lima, Perú

*Corresponding author: Juan Carlos Izquierdo Villavicencio, MD, Chief of Glaucoma, Department of Ophthalmology, Research Department Oftalmosalud Eye Institute, Lima-Peru, Av. Javier Prado Este 1142, San Isidro, Lima, Perú, Tel: +511-985-148-485; E-mail: jcizq@mac.com

Received date: August 21, 2018; Accepted date: September 12, 2018; Published date: September 19, 2018

Copyright: ©2018 Villavicencio JCI, et al. This is an open-access article distributed under the terms of the Creative Commons Attribution License, which permits unrestricted use, distribution, and reproduction in any medium, provided the original author and source are credited.

Abstract

Purpose: To compare outcomes of CO₂ laser-assisted sclerectomy surgery (CLASS) and trabeculectomy in patients with open-angle glaucoma, both combined with phacoemulsification.

Methods: A retrospective analytical study included 70 eyes. We compared the results of surgical procedures, phacoemulsification + trabeculectomy + Ologen implant performed in 2013 and 2014 and phacoemulsification + CLASS + Ologen implant performed in 2015 and 2016. Patients diagnosed with open-angle glaucoma were included. Intraocular pressure (IOP) was measured preoperatively and at 1, 3, 6, 9, and 12 months. Best-corrected visual acuity (BCVA) was measured preoperatively and at 1, 9, and 12 months. Medication use was measured preoperatively and at 9 and 12 months. Success rate was defined as IOP ≤ 18 mmHg with or without medication 1 year postoperatively.

Results: In total, 37 eyes were included in the trabeculectomy group and 33 eyes in the CLASS group. Both groups had a follow-up of 1 year. In the trabeculectomy group, mean ± SD preoperative IOP and that at 1-year follow-up were 17.03 ± 5.75 and 11.65 ± 1.34 mmHg (a reduction of 37.68%), BCVA increased from 0.196 ± 0.27 to 0.20 ± 0.32, and medications decreased from 2.97 ± 1.11 to 1.27 ± 1.07. The success rate was 86.4%. In the CLASS group, mean ± SD preoperative IOP and that at 1-year follow-up were 21.15 ± 7.2 and 12.42 ± 2.3 mmHg (a 45.19% reduction), BCVA declined from 0.20 ± 0.2 to 0.07 ± 0.1, and medications decreased from 3.51 ± 0.79 to 0.51 ± 0.66. The success rate was 97.2%.

Conclusion: Our findings demonstrate that CLASS is a technique that allows good reduction of IOP and medications and maintains better visual acuity with lower rates of postoperative complications than conventional trabeculectomy.

Keywords: CO₂ laser-assisted sclerectomy; Best-corrected visual acuity; Intraocular pressure; Trabeculo-Deemet's membrane

Introduction

Glaucoma is one of the most frequent causes of permanent blindness worldwide. To treat Glaucoma the trabeculectomy surgery has been the gold standard of filtration surgeries, demonstrating adequate control of intraocular pressure (IOP). However, considering postoperative complications, such as a shallow anterior chamber, hypotony, blister failure, cataract formation, endophthalmitis, choroidal hemorrhage or malignant glaucoma, [1-3] the number of surgeons who perform non-perforating filtration techniques, such as non-penetrating deep sclerectomy (NPDS), has increased despite its main disadvantage, the slow learning curve, because it is a precise surgical technique [4].

The main work conducted by Krasnov [5] in 1969 and various amendments developed the new filtration technique of NPDS, [6-9] which has a better safety profile than the conventional trabeculectomy [10]. NPDS enables the aqueous humor to be filtered from the anterior chamber through the Trabeculo-Deemet's Membrane (TDM), thus

avoiding entering the anterior chamber surgically. The technique requires dissection of two scleral flaps, one at a surface level and the other at a deeper level of the sclera, to dry out the deeper one. In this way, the outer wall of Schlemm's canal is removed, allowing percolation, that is, the passage of aqueous humor through the TDM [11,12].

A variation of this NPDS is the CO₂ laser-assisted sclerectomy surgery (CLASS) proposed by Assia et al. as a potential alternative to simplify this surgery. The CO₂ laser allows a safe sclerectomy because photoablation occurs only with dry tissues [13-15]. The infrared radiation (wavelength of 10600 nm) is absorbed by liquid, so it is ineffective with wet tissues; when unroofing Schlemm's canal and beginning percolation of the aqueous humor, the liquid prevents the laser from perforating the TDM, thus minimizing the likelihood of entering the anterior chamber [16]. CLASS offers a rapid learning curve for surgeons experienced in filtration surgeries, and it requires a shorter surgical time than conventional NPDS surgery [2,17,18].

The aim of this study was to analyze retrospectively the clinical results of both techniques trabeculectomy and phacoemulsification

versus CLASS and phacoemulsification, in patients with open-angle glaucoma.

Methods

An analytical retrospective study was conducted to review the medical records of 70 patients (total of 84 eyes) who underwent surgery at the Oftalmosalud Eye Institute, Lima, Peru. The study complied with the Declaration of Helsinki. The ethics committee and institutional review board of Oftalmosalud approved the study. Written informed consent was obtained from all patients. The results of two surgical procedures were compared: trabeculectomy + phacoemulsification conducted in 2013 and 2014 and CLASS + phacoemulsification conducted in 2015 and 2016. In both procedures, a subconjunctival Ologen collagen matrix implant was used.

The inclusion criteria were 18 years old or older patients diagnosed with progressive open-angle glaucoma in which the intraocular pressure (IOP) could not be controlled with maximum medical therapy and with moderate glaucoma between -6.00 y -12.00 dB in the Hopapp-Parrish-Anderson classification. All patients who had history of previous filtration surgeries, history of laser eye surgeries, previous critical ocular trauma or any intraocular pathology included macular degeneration age related were excluded.

IOP was measured with the Goldman applanation tonometer in the preoperative period and at 1, 3, 6, 9, and 12 months after surgery. The number of antiglaucoma medications used, as well as the best-corrected visual acuity (BCVA) measured according to the Snellen chart converted into the LOGMAR chart, were assessed in the preoperative period and at 1, 9, and 12 months after surgery. Postoperative complications were recorded at each visit during the first year. The decrease of IOP to ≤ 18 mmHg with or without medication was considered as a rate success.

Surgical Techniques

All surgeries were conducted by using intravenous sedation and subconjunctival anesthesia.

Trabeculectomy

Subconjunctival anesthesia with lidocaine was filtered with mitomycin C at 0.04 mg/ml. The trabeculectomy was conducted via a fornix-based peritomy, with a scleral flap of 1/3 thickness of 4 × 4 mm up to clear cornea. Phacoemulsification of the crystalline lens was done by making an incision through clear cornea, then the intraocular lens was implanted. The anterior chamber at cornea level was operated with a #15 surgical knife and then conducted a trabeculectomy of 1 mm with a Kelly punch; a peripheral iridectomy was done, and closed the scleral flap with 10.0 nylon. The Ologen subconjunctival implant was inserted, allowing a free space in the superior edge of the scleral flap, closed the peritomy with 10.0 nylon, and performed a Seidel test. Finally, intracameral antibiotic was applied (Figure 1).

CO₂ Laser-Assisted Sclerectomy Surgery (CLASS)

The AcuPulse CO₂ laser system (Lumenis, Yokneam, Israel) was used with an adapter (IOPTiMate, IOPTima, Tel Aviv, Israel).

Subconjunctival anesthesia with lidocaine was filtered with mitomycin C at 0.04 mg/ml. The surgeon created a fornix-based conjunctival flap, a scleral flap of 1/3 partial thickness of 5 × 5 mm

calculated with the CO₂ laser compass. Phacoemulsification of the crystalline lens was done by making a 2.2 mm incision through clear cornea, then an intraocular lens was implanted. The CO₂ laser beam was applied on the white zone of the scleral bed, where the scleral reservoir was conducted in an area of 2 × 3 mm.

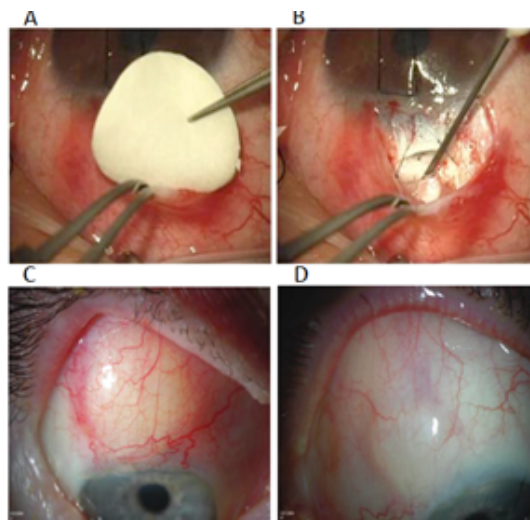


Figure 1: A-B After phacoemulsification and trabeculectomy or CLASS treatment, we introduced the Ologen implant behind the conjunctival flap. C Blister appearance 3 months Post Op. D Blister appearance 9 month Post Op.

Then the CO₂ laser was applied in the perilimbal grey area, which corresponds to the roof of Schlemm's canal. The area was subjected to ablation until exit of the aqueous humor, a process known as percolation. The ablation process occurred across the entire width of the grey area of the scleral flap until the surgeon observed sufficient percolation of the aqueous humor. The scleral flap was closed with two 10.0 nylon stitches, verifying any filtration. Then the Ologen subconjunctival implant was placed in the superior edge of the scleral flaps, the peritomy was closed with 10.0 nylon and a Seidel test was performed. Finally, intracameral antibiotic was applied (Figure 2).

In both groups, topical antibiotics (Moxifloxacin hydrochloride) were used in the postoperative period every 4 hours for 1 week. Corticoids (Prednisolone acetate) were given every 4 h for 2 weeks; then the dose was reduced to every 6 h until 1 month after the surgery, and every 8 h a day until 3 months, then twice a day for 2 months more, and finally once a day until 6 months. The CLASS group received pilocarpine during the first 15 days, to avoid imprisonment of the iris and maintain constant percolation and the trabeculectomy group received atropine during the first 15 days to prevent choroid detachment.

Statistical analysis

The statistical analysis was performed by using the SPSS program version 21. The data are presented as mean \pm SD or median (range) for continuous variables or as percentages for categorical variables. Student's t-test was used for independent samples in the case of IOP and various drugs. Regarding BCVA, the Mann-Whitney U-test and Kaplan-Meier curves were used to analyze the efficacy and demonstrate the success rate.

Chronic open-angle glaucoma	37 (100%)	33 (100%)
-----------------------------	-----------	-----------

Table 1: Patients' demographic and clinical characteristics

IOP

The IOP (mean ± SD) for the trabeculectomy group was 17.03 ± 5.75 mmHg in the preoperative period, 11.76 ± 3.97 mmHg at 1 month, 12.57 ± 3.53 mmHg at 3 months, 12.14 ± 1.87 mmHg at 6 months, 13.49 ± 3.77 mmHg at 9 months, and 11.65 ± 1.34 mmHg at 1 year, including 4 patients with a pre-operative IOP more than 25 mmhg (29.5±3.69); in the CLASS group, these values were 21.15 ± 7.2, 12.00 ± 4.1, 13.85 ± 5.5, 13.09 ± 3.7, 12.82 ± 2.2, and 12.42 ± 2.3 mmHg, respectively (Figure 3), including 6 patients with pre-operative IOP more than 25 mmhg (39.83 ± 10.12 mmhg).

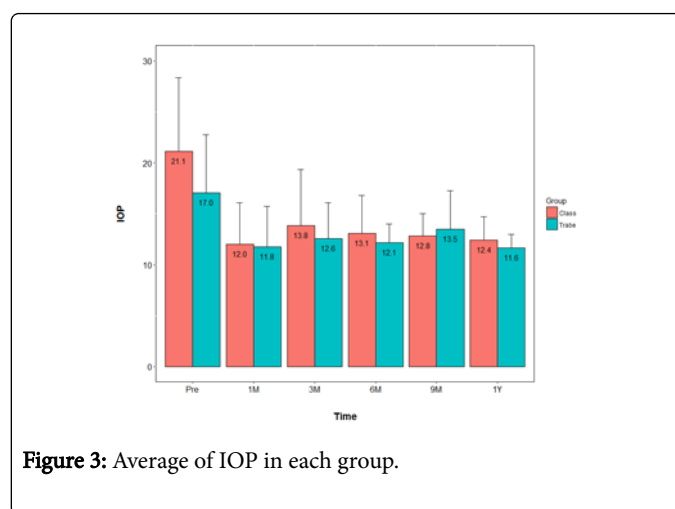


Figure 3: Average of IOP in each group.

In the trabeculectomy group, the success rate was 86.48% with a 37.68% reduction in IOP. In the CLASS group, the success rate was 97.2%, with a 45.19% reduction in IOP.

Medication

In the trabeculectomy group, medication (mean ± SD) was reduced from 2.97 ± 1.11 in the preoperative period to 1.27 ± 1.07 after 1 year. In the CLASS group, medication was reduced from 3.51 ± 0.79 in the preoperative period to 0.51 ± 0.667 at 1 year (Figure 4).

Complications

In the trabeculectomy group, postoperative complications were narrow camera in 2.7% of cases. Four patients required another surgery to reduce IOP. Two patients undergoing to endocyclophotocoagulation and the other two was made Baerveldt glaucoma drainage implant, which represents 11.2%.

In the CLASS group, the main early postoperative complications were temporary ocular hypertension in 8 cases (24.24%), which was treated with oral acetazolamide and solved in the first postoperative month in all cases; hypotony in 1 case (33%), which was treated with topical steroids and oral steroids; we did goniopuncture in 33.33%; and needling in 21.21% of eyes.

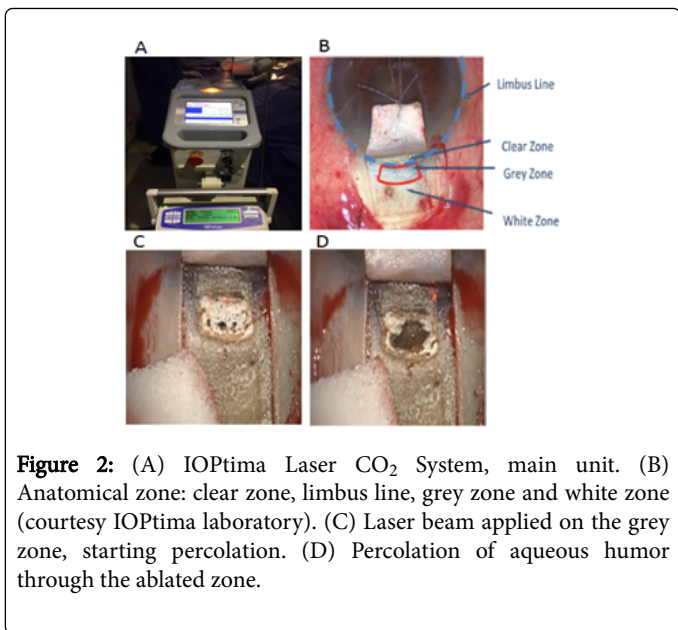


Figure 2: (A) IOPTima Laser CO₂ System, main unit. (B) Anatomical zone: clear zone, limbus line, grey zone and white zone (courtesy IOPTima laboratory). (C) Laser beam applied on the grey zone, starting percolation. (D) Percolation of aqueous humor through the ablated zone.

Results

A total of 70 eyes of 70 patients were analyzed. Regarding the trabeculectomy group, 37 eyes were analyzed, with a mean ± SD age of 68.3 ± 12.1 years and a frequency of 56.7% males and 43.3% females. Regarding the CLASS group, 33 eyes were analyzed, with a mean ± SD age of 67.9 ± 12.0 years and a frequency of 61.5% males and 38.5% females. The diagnoses included were chronic open-angle glaucoma in 70 (100%). Both surgical techniques had a follow-up of 1 year (Table 1).

BCVA

The BCVA (mean ± SD) in the trabeculectomy group was 0.19 ± 0.27 during the preoperative period, 0.21 ± 0.27 at 1 month, 0.20 ± 0.29 at 9 months, and 0.20 ± 0.32 at 1 year. That in the CLASS group was 0.20 ± 0.2 preoperatively, 0.22 ± 0.2 after 1 month, 0.08 ± 0.1 after 9 months, and 0.07 ± 0.1 after 1 year. Comparing the results, both groups showed statistically significant differences between preoperative values and those at 1-year follow-up.

	Trabeculectomy	CLASS
No. of patients	37 (100%)	33 (100%)
Sex		
Female	13 (43.3%)	10 (38.5%)
Male	17 (56.7%)	16 (61.5%)
Age of patients (years)		
Mean ± SD	68.3 ± 12.1	67.9 ± 12.0
No. of eyes	37 (100%)	33 (100%)
Right	24 (64.9%)	19 (57.6%)
Left	13 (35.1%)	14 (42.4%)
Diagnosis		

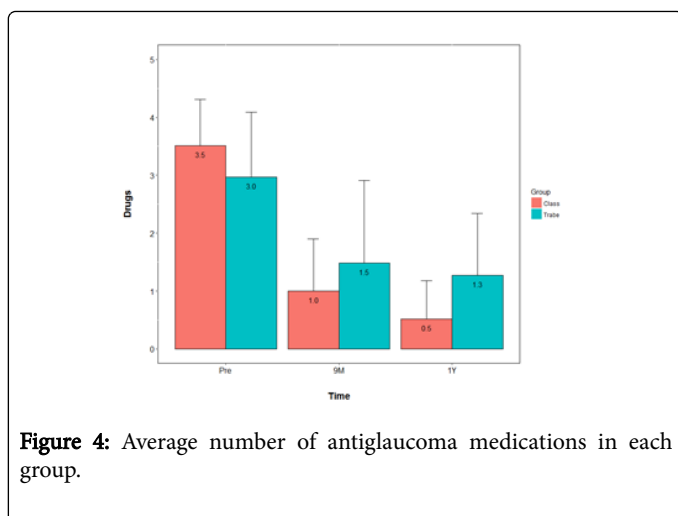


Figure 4: Average number of antiglaucoma medications in each group.

Discussion

The efficacy regarding the reduction of IOP with the CLASS procedure is comparable to the results registered in manual NPDS studies, but the CLASS procedure is easier and depends less on the surgeon [18]. Our success rate in the CLASS group was 97.2%. According to the database of Cochrane systematic revisions, the expected success rate for manual NPDS with no antimetabolites or collagen implants is 80% at 6 months. This improvement in the success rate of CLASS may reflect the accuracy of the laser obtaining the expected results [16].

Previous studies compare trabeculectomy or CLASS with conventional NPDS, but this seems to be the first study to compare trabeculectomy with CLASS. Eldaly et al. [19] demonstrated non-inferiority between conventional NPDS and trabeculectomy regarding the success rate (OR 0.98, 95% CI 0.51–1.88). This result is similar to the results obtained in our study, in which after 1 year of follow-up, both groups registered similar IOP and success rate.

In our study, significantly less medication was used in the CLASS group than in the trabeculectomy group. In a long-term study of NPDS with collagen implants, Shaarawy et al. [20] reported an absolute success rate of 57%, defined as IOP < 21 mmHg with medications and Cabarga-Nozal et al. [21] reported less use of medication during the postoperative period in patients with NPDS in comparison with conventional trabeculectomy.

In various studies, a lower complication rate has been demonstrated in NPDS versus conventional trabeculectomy [19,22]. In this study, the complication reported in the trabeculectomy group was narrow camera. In this group we did not find any choroidal detachment. However, it is widely known as reported in studies trabeculectomy complications including hyphema, hypotony, narrow anterior chamber, choroidal detachment, and Seidel failure [23].

Greifner et al. [2] compared CLASS versus conventional NPDS and reported the following complications for the CLASS group: microperforation (3%), macro-perforation (7%), hyphema (7%), hypotony (7%), narrow anterior chamber (3%), choroidal detachment (7%), Seidel failure (18%), iris incarceration (48%), macular edema (3%), and malignant glaucoma (3%).

In the CLASS group reported the following complications, temporary ocular hypertension, hypotony, iris incarceration, and plain blister. It was not reported macroperforations because if this occurred intraoperatively, it would turn into conventional trabeculectomy and the CLASS group would be excluded.

Because of the difficulty of evaluating a microperforation, it was considered that the cases with hypotony may have been caused by microperforations of TDM or the beginning of a choroidal detachment, which was rapidly solved by using high doses of corticoid. All hypotony cases were solved in the first month after the surgery with no complications.

The patients with iris incarceration had a goniopuncture. This procedure is usually performed during the postoperative period of NPDS to reduce spontaneous iris incarceration, which reduces the exit of aqueous humor through the TDM, thus reducing IOP. Greifner et al [2] noted performing goniopuncture in 85% of the CLASS group. According to the medium-term clinical results of CLASS, Geffen et al [18] performed goniopuncture in 6% of patients, and in their study of long-term results of NPDS Shaarawy et al. [21] performed 51% of goniopunctures with collagen implants. Despite the fact that goniopuncture turns deep sclerectomy into a penetrating procedure in a later stage, it is not considered as a failed treatment but a procedure that enables clinicians to have better control of IOP, offering a sustained success of the surgery. The same occurs with the revision of needling, which should not be considered as a surgical failure. Greifner et al. [2] reported performing needling in 44% of the CLASS group. Geffen et al. [18] performed needling in 26% of patients. Thus, the frequency of goniopuncture (33.33%) and needling (21.21%) in our study is within the expected range.

Previous studies did not report a significant difference in terms of BCVA between conventional NPDS and conventional trabeculectomy [4,22]. We did find differences in BCVA, registering better results in the CLASS group after 9 months and 1 year in comparison with the conventional trabeculectomy group. This difference may be caused by fewer complications during the postoperative period, because non-penetrating surgeries produce less inflammation of the anterior chamber.

This study had some limitations. It is a retrospective study with a short follow-up period (12 months). It provided a better follow-up to evaluate the efficacy of long-term CLASS.

In conclusion, conventional trabeculectomy and CLASS enable adequate control of IOP in patients with glaucoma who do not respond to pharmacological treatment. However, CLASS results in fewer postoperative complications which are characteristic of all filtration surgeries and the patients needed fewer drugs to control IOP. It also provides surgeons a rapid learning curve with a shorter surgical time than conventional NPDS.

References

1. Assia EI, Rotenstreich Y, Barequet IS, Apple DJ, Rosner M, et al. (2007) Experimental studies on nonpenetrating filtration surgery using the CO₂ laser. *Graefes Arch Clin Exp Ophthalmol Albrecht Von Graefes Arch Klin Exp Ophthalmol* 245: 847-854.
2. Greifner G, Roy S, Mermoud A (2016) Results of CO₂ Laser-assisted Deep Sclerectomy as Compared With Conventional Deep Sclerectomy. *J Glaucoma* 25: e630-638.

3. Edmunds B, Thompson JR, Salmon JF, Wormald RP (2002) The National Survey of Trabeculectomy. III. Early and late complications. *Eye Lond* 16: 297-303.
4. El Sayyad F, Helal M, El-Kholify H, Khalil M, El-Maghraby A (2000) Nonpenetrating deep sclerectomy versus trabeculectomy in bilateral primary open-angle glaucoma. *Ophthalmology* 107: 1671-1674.
5. Krasnov MM (1969) Microsurgery of glaucoma Indications and choice of techniques. *Am J Ophthalmol* 67: 857-864.
6. Zimmerman TJ, Kooner KS, Ford VJ, Olander KW, Mandlekorn RM, et al. (1984) Effectiveness of nonpenetrating trabeculectomy in aphakic patients with glaucoma. *Ophthalmic Surg* 15: 44-50.
7. Al-Obeidan SA, Mousa A, Naseem A, Abu-Amero KK, Osman EA (2013) Efficacy and safety of non-penetrating deep sclerectomy surgery in Saudi patients with uncontrolled open angle glaucoma. *Saudi Med J* 34: 54-61.
8. Stegmann R, Pienaar A, Miller D (1999) Viscocanalostomy for open-angle glaucoma in black African patients. *J Cataract Refract Surg* 25: 316-322.
9. Sourdille P, Santiago PY, Villain F, Yamamichi M, Tahi H, et al. (1999) Reticulated hyaluronic acid implant in nonperforating trabecular surgery. *J Cataract Refract Surg* 25: 332-339.
10. Sarodia U, Shaarawy T, Barton K (2005) Nonpenetrating glaucoma surgery: a critical evaluation. *Curr Opin Ophthalmol* 18: 152-158.
11. Guedes RAP, Guedes VMP. Nonpenetrating deep sclerectomy in Brazil: a 3-year retrospective study. *J Fr Ophtalmol* 28: 191-196.
12. Khaw PT, Siriwardena D (1999) New surgical treatments for glaucoma. *Br J Ophthalmol* 83: 1-2.
13. Mermoud A, Schnyder CC, Sickenberg M, Chiou AG, Hédiguer SE, et al. (1999) Comparison of deep sclerectomy with collagen implant and trabeculectomy in open-angle glaucoma. *J Cataract Refract Surg* 25: 323-331.
14. Rebolleda G, Muñoz-Negrete FJ (2004) Phacoemulsification-deep sclerotomy converted to phacotrabeculectomy. *J Cataract Refract Surg* 30: 1597-1598.
15. Sanchez E, Schnyder CC, Mermoud A (1997) Comparative results of deep sclerectomy transformed to trabeculectomy and classical trabeculectomy. *Klin Monatsbl Augenheilkd* 210: 261-264.
16. Skaat A, Goldenfeld M, Cotlear D, Melamed S (2014) CO₂ laser-assisted deep sclerectomy in glaucoma patients. *J Glaucoma* 23: 179-184.
17. Geffen N, Ton Y, Degani J, Assia EI (2012) CO₂ laser-assisted sclerectomy surgery, part II: multicenter clinical preliminary study. *J Glaucoma* 21: 193-198.
18. Geffen N, Mimouni M, Sherwood M, Assia EI (2016) Mid-term Clinical Results of CO₂ Laser-assisted Sclerectomy Surgery (CLASS) for Open-Angle Glaucoma Treatment. *J Glaucoma* 25: 946-951.
19. Eldaly MA, Bunce C, Elsheikha OZ, Wormald R (2014) Non-penetrating filtration surgery versus trabeculectomy for open-angle glaucoma. *Cochrane Database Syst Rev* 15: CD007059.
20. Shaarawy T, Mansouri K, Schnyder C, Ravinet E, Achache F, et al. (2004) Long-term results of deep sclerectomy with collagen implant. *J Cataract Refract Surg* 30: 1225-1231.
21. Cabarga-Nozal C, Arnalich-Montiel F, Fernández-Buenaga R, Hurtado-Ceña FJ, Muñoz-Negrete FJ (2010) Comparison between phaco-deep sclerectomy and phaco-deep sclerectomy reconverted into phaco-trabeculectomy: series of fellow eyes. *Graefes Arch Clin Exp Ophthalmol* 248: 703-708.
22. Gianoli F, Schnyder CC, Bovey E, Mermoud A (1999) Combined surgery for cataract and glaucoma: phacoemulsification and deep sclerectomy compared with phacoemulsification and trabeculectomy. *J Cataract Refract Surg* 25: 340-346.
23. Rosentreter A, Schild AM, Jordan JF, Krieglstein GK, Dietlein TS (2010) A prospective randomised trial of trabeculectomy using mitomycin C vs an ologen implant in open angle glaucoma. *Eye Lond* 24: 1449-1457.