

Comparing the Use of a Needle Guidance Device vs. Free-hand Technique in Performing Ultrasound-guided TAP Blocks: A Prospective Randomised Trial

Kim C¹, Ratnayake M², Lethbridge G¹ and Ng I^{1*}

¹Staff Anaesthetist, Department of Anaesthesia and Pain Management, The Royal Melbourne Hospital and University of Melbourne, Melbourne, VIC, Australia

²Medical Student, Monash University, Melbourne, VIC, Australia

Abstract

We compared the use of Infinity™ needle guide vs. free hand technique in performing ultrasound-guided Transversus Abdominis Plane (TAP) blocks in a clinical setting. Twenty patients having open abdominal surgery were recruited. The needle tip visibility was better with the use of needle guide than without, as demonstrated by the increased median (IQR) percentage of the time the needle tip was visualised: 34.2% (15.0-55.1) vs. 17.9% (8.2-28.3), $p < 0.05$. The total procedure time was less with the use of needle guide: 107.9s (76.6-120.2) vs. 123.8s (96.5-165.9), $p < 0.05$. The proceduralist satisfaction (score 0-10) was higher with the use of needle guide 8.0 (5.3-8.8) vs. 5.5 (4.0-7.8), $p < 0.05$. The use of needle guide improved the percentage of needle tip visibility, time to perform the block and proceduralist satisfaction when performing ultrasound-guided TAP block.

For abdominal surgery, there has been growing interest in Transversus Abdominis Plane (TAP) blocks with promising safety and efficacy data emerging [1-5]. A study by McDermott et al. has suggested that the traditional “blind” technique of using standard landmark-based approach to TAP block, was inaccurate (only 23.6% of the needle being in accurate plane) and the incidence of peritoneal placement was 18% [6]. The use of ultrasound has been gaining wide popularity with reassuring evidence in regional anaesthetic technique [7-11]. Hebbard et al. has provided detailed anatomical and technical description of the use of ultrasound in TAP block [12,13]. However, one of the difficulties with the use of ultrasound is the ability to continuously visualise the needle tip for procedural efficacy and safety. Multiple technological advances and approaches have been suggested [14-16], one of which is the use of a needle guide system. The needle guide is designed to apply onto the ultrasound probe. It restricts lateral movement of the needle and keeps the needle trajectory in-line with the long axis of the probe (Figure 1). Significant improvement in needle tip visibility has been shown in previous simulation and porcine phantom studies [17-19]. To date, there has been no human study on the use of needle guide in ultrasound-guided regional anaesthesia. This study was to determine

whether the use of a needle guide system, Infinity™, would improve needle tip visibility in performing ultrasound-guided TAP block in a clinical setting.

Method

Melbourne Health Human Research Ethics Committee approved this prospective randomised observer-blinded crossover study. We registered this trial with the Australian New Zealand Clinical Trials Registry, ACTRN12613000392763, prior to commencement of the study. Twenty adult patients undergoing open abdominal surgery under general anaesthesia, who were planned to receive bilateral, single shot, ultrasound guided in-plane TAP blocks, were recruited at the Royal Melbourne Hospital. We excluded patients who were not able to provide informed consent. After receiving written informed consent, patients were assigned using a computer-generated randomisation to one of the two groups. Randomization results were concealed in opaque sequentially numbered envelopes until after consent was obtained. Patients in group 1 received the block performed with the needle guide, Infinity™ (CIVCO Medical Solutions, Kalona, Iowa, USA) technique on the first side, followed by a free hand technique on the opposite side. Patients in group 2 received the block with a free hand technique first, followed by the needle guided technique on the opposite side. The free hand technique consisted of using the ultrasound probe on one hand and the needle on the other hand without the attachment of the needle guide system on the probe. The needle was inserted in the long-axis (or in-plane) approach. The needle guide technique was similar to the free hand technique, except the needle was inserted through the needle

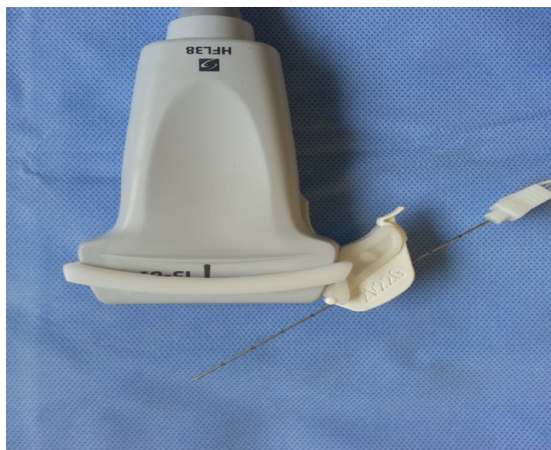


Figure 1: Infinity™ CIVCO needle guide attached to ultrasound probe with 21G Stimplex needle® BRAUN.

***Corresponding author:** Irene Ng, Department of Anaesthesia and Pain Management, The Royal Melbourne Hospital, Grattan St. Parkville, VIC, Australia, Tel: +61 3 9342 7540; E-mail: Irene.Ng@mh.org.au

Received May 06, 2014; **Accepted** August 02, 2014; **Published** August 12, 2014

Citation: Kim C, Ratnayake M, Lethbridge G, Ng I (2014) Comparing the Use of a Needle Guidance Device vs. Free-hand Technique in Performing Ultrasound-Guided TAP Blocks: A Prospective Randomised Trial. J Anesth Clin Res 5: 429. doi:10.4172/2155-6148.1000429

Copyright: © 2014 Kim C, et al. This is an open-access article distributed under the terms of the Creative Commons Attribution License, which permits unrestricted use, distribution, and reproduction in any medium, provided the original author and source are credited.

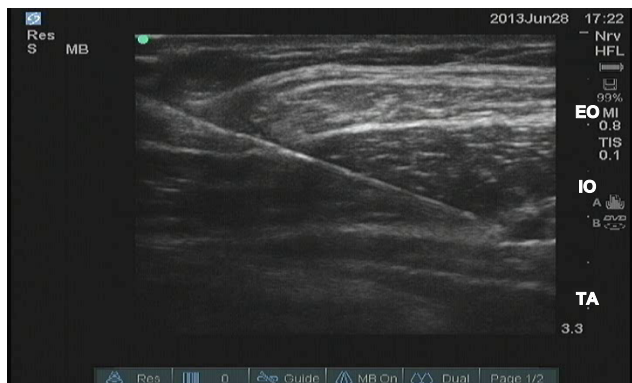

Figure 2: Ultrasonographic view of a 21-gauge 100 mm Stimuplex needle® advancing towards the transversus abdominis plane below the external oblique (EO) and between the internal oblique (IO) and transversus abdominis (TA) muscles.

Age; yrs	65.1 (13.5)
Height; cm	170.1 (10.7)
Weight; kg	87.1 (23.8)

Table 1: Patients' baseline characteristics. Values are mean (standard deviation).

Level of anaesthetic training	Trainee	6 (30%)
	Consultant	14 (70%)
Number of previous ultrasound-guided in-plane procedures performed	<50 procedures	9 (45%)
	≥50 procedures	11 (55%)

Table 2: Characteristics of proceduralists. Values are numbers (percentage).

	Free-hand	Needle guide	p-value
Needle visibility; %	17.9 (8.2-28.3)	34.2 (15.0-55.1)	0.022
Total procedural time; s	123.8 (96.5-165.9)	107.9 (76.6-120.2)	0.019
Proceduralist satisfaction; 0-10	5.5 (4.0-7.8)	8.0 (5.3-8.8)	0.016

Table 3: Outcome variables comparing free hand vs. needle guidance technique in performing ultrasound-guided TAP blocks. Numbers are median (IQR).

guide system, which was attached to the probe (Figure 1). This would prevent any lateral movement of the needle.

All TAP blocks were performed by either a specialist anaesthetist or an anaesthetic trainee. Proceduralists received a presentation explaining the use of the needle guide prior to performing the block. We allowed them to practice their needling technique on a gel phantom model with and without the needle guide before performing the TAP blocks. M-Turbo® ultrasound machine (SonoSite Inc, Bothell, Washington, USA) with a linear high frequency (13-6 MHz) transducer probe was used.

The TAP blocks were performed at the completion of the surgery, whilst the patient remained anaesthetized. The allocation of the group dictated whether the needle guide or the free hand technique was used first. The ultrasound probe was placed in a transverse plane on the lateral abdominal wall in the mid-axillary line, between the lower costal margin and iliac crest. A 21 gauge 100 mm Stimuplex needle® (B. Braun Melsungen AG, Germany) was then introduced in-plane of the ultrasound probe and advanced until the tip was observed within the transversus abdominis plane between the internal oblique and transversus abdominis muscles (Figure 2). At this point, 20 ml of ropivacaine solution (0.5% ropivacaine for patient's ≥ 70 kg and 0.35% ropivacaine for patients <70 kg) was injected in 5 ml aliquots after negative aspiration. The transversus abdominis plane was visualised

expanding with the injection. After the first block had been performed, the anaesthetist moved to the opposite side to perform the second block with the second technique as dictated by the group allocation and all relevant equipment was moved to be symmetrical to the setup for the first block.

Video clips of both procedures were recorded on a computer attached to the ultrasound machine and de-identified for later assessment. Two blinded investigators (CK and GL) experienced in ultrasound guided regional anaesthesia independently evaluated all of the recorded video clips. Value disparity between investigators of less than 10% was considered acceptable for individual measurements. Disagreements of greater than 10% were resolved by consensus. Unresolved disagreements were referred to a third investigator for evaluation. The primary outcome was the time the needle tip was visualised, expressed as a proportion of the overall procedural time. Secondary outcomes included total procedure time, which was defined as the time taken from needle insertion to successful injection of local anaesthetic in the transversus abdominis plane; and proceduralist's satisfaction score (numerical rating score of 0-10) for each technique.

Sample size was calculated based on previous study using phantom model [18]. Using the effect size (mean of differences / SD of differences in a paired sample design) of 1.37 for percentage time needle visualised and 0.74 for total procedural time, the study required the recruitment of 7 patients and 17 patients respectively, with α=0.05 and power=0.8. We decided to recruit 20 participants (double the absolute minimum sample size indicated and accounting for potential drop-outs). Values were expressed as mean (standard deviation), median (IQR), and number (percentages) as appropriate. Non-parametric test was used because of small sample size and non-normally distributed data. Comparison between the groups was performed with Wilcoxon's signed ranks test. Statistical analysis was performed using Stat Plus (AnalystSoft Inc, Vancouver, BC, Canada). We considered p<0.05 statistically significant.

Results

Twenty patients were randomised (Table 1) with ten patients receiving the block using the free-hand technique first and ten using the needle guided technique first. A total of twelve different proceduralists performed the TAP blocks for this study (Table 2). The proportion of time when the needle tip was visible was significantly better when using the needle guide compared to free-hand technique (Table 3). The total procedural time was reduced and the proceduralists were more satisfied with the use of the needle guide system compared to free-hand technique (Table 3).

Discussion

This is the first human study utilising Infinity™ needle guide to perform regional anaesthesia. We have demonstrated that the Infinity needle guide improves performance of ultrasound-guided TAP block, by improving needle tip visibility, reducing procedural time and increasing proceduralist's satisfaction.

Although needle tip visualisation improved by almost 50% with the use of the needle guide in our clinical study (from 18% to 34%), this finding was not as profound as the one shown in the phantom study [18], which showed an improvement from 23% to 67%. This could be partly explained by the fact that ultrasonographic appearance and behaviour of a living nerve and/or fascial plane is different from the one seen in a phantom model. The target plane was dynamic and its depth was variable in clinical setting, making it more challenging to maintain

needle tip visibility during the procedure. This shows the importance of carrying out a clinical study after a simulation study in clinical research.

The total procedure time (time from needle penetration of skin to successful injection of local anaesthetics in the correct plane) was reduced from 123.8 seconds to 107.9 seconds. Although statistically significant, the clinical significance of this was debatable. However, the combination of improved needle visibility and reduction of procedural time should improve patient comfort during the procedure.

The crossover nature of this study design constituted both the strengths and the weaknesses of our study. First of all, the participants acted as their own controls and hence minimised the variability and confounding factors. However, we could not compare between the two techniques, such as, patient's post-operative pain score or opioid use because the same patient received the blocks from both techniques, one on each side. Therefore, we could only use time to complete the task and needle tip visibility as surrogate outcomes, which may or may not be associated with patient's benefit and harm. Further studies specifically designed to investigate clinical outcomes in terms of safety and efficacy with the use of needle guide would be beneficial.

In conclusion, this clinical study supports earlier simulation study which shows increased needle visibility, shorter procedural time and greater proceduralist satisfaction when using needle guidance device compared to free hand technique in ultrasound-guided in-plane procedure. This suggests that Infinity needle guide may have a place in clinical ultrasound guided regional techniques. Further clinical studies are warranted whether this may translate into improved patient safety and efficacy.

Acknowledgement

We would like thank Dr Andrew Bjorksten for providing valuable assistance with the data analysis and Professor Kate Leslie for critically reviewing the proposal and the data analysis.

References

1. McDonnell JG, Donnell B, Curley G, Heffernan A, Power C, et al. (2007) The analgesic efficacy of transversus abdominis plane block after abdominal surgery: a prospective randomized controlled trial. *Anesth Analg* 104: 193-197.
2. Kadam RV, Field JB (2011) Ultrasound-guided continuous transverse abdominis plane block for abdominal surgery. *Journal of anaesthesiology, clinical pharmacology* 27: 333-336.
3. Charlton S, Cyna AM, Middleton P, Griffiths JD (2010) Perioperative transversus abdominis plane (TAP) blocks for analgesia after abdominal surgery. *Cochrane Database Syst Rev* : CD007705.
4. Siddiqui MR, Sajid MS, Uncles DR, Cheek L, Baig MK (2011) A meta-analysis on the clinical effectiveness of transversus abdominis plane block. *J Clin Anesth* 23: 7-14.
5. Johns N, O'Neill S, Ventham NT, Barron F, Brady RR, et al. (2012) Clinical effectiveness of transversus abdominis plane (TAP) block in abdominal surgery: a systematic review and meta-analysis. *Colorectal Dis* 14: e635-642.
6. McDermott G, Korba E, Mata U, Jaigirdar M, Narayanan N, et al. (2012) Should we stop doing blind transversus abdominis plane blocks? *Br J Anaesth* 108: 499-502.
7. Sites BD, Brull R (2006) Ultrasound guidance in peripheral regional anesthesia: philosophy, evidence-based medicine, and techniques. *Curr Opin Anaesthesiol* 19: 630-639.
8. Horlocker TT, Wedel DJ (2007) Ultrasound-guided regional anesthesia: in search of the holy grail. *Anesth Analg* 104: 1009-1011.
9. Gelfand HJ, Ouanes JP, Lesley MR, Ko PS, Murphy JD, et al. (2011) Analgesic efficacy of ultrasound-guided regional anesthesia: a meta-analysis. *J Clin Anesth* 23: 90-96.
10. Warman P, Nicholls B (2009) Ultrasound-guided nerve blocks: efficacy and safety. *Best Pract Res Clin Anaesthesiol* 23: 313-326.
11. Walker KJ, McGrattan K, Aas-Eng K, Smith AF (2009) Ultrasound guidance for peripheral nerve blockade. *Cochrane Database Syst Rev* : CD006459.
12. Hebbard P, Fujiwara Y, Shibata Y, Roysse C (2007) Ultrasound-guided transversus abdominis plane (TAP) block. *Anaesth Intensive Care* 35: 616-617.
13. Hebbard PD, Barrington MJ, Vasey C (2010) Ultrasound-guided continuous oblique subcostal transversus abdominis plane blockade: description of anatomy and clinical technique. *Reg Anesth Pain Med* 35: 436-441.
14. Tsui BC (2007) Facilitating needle alignment in-plane to an ultrasound beam using a portable laser unit. *Reg Anesth Pain Med* 32: 84-88.
15. Hebard S, Hocking G (2011) Echogenic technology can improve needle visibility during ultrasound-guided regional anesthesia. *Reg Anesth Pain Med* 36: 185-189.
16. Chin KJ, Perlas A, Chan VW, Brull R (2008) Needle visualization in ultrasound-guided regional anesthesia: challenges and solutions. *Reg Anesth Pain Med* 33: 532-544.
17. van Geffen GJ, Mulder J, Gielen M, van Egmond J, Scheffer GJ, et al. (2008) A needle guidance device compared to free hand technique in an ultrasound-guided interventional task using a phantom. *Anaesthesia* 63: 986-990.
18. Whittaker S, Lethbridge G, Kim C, Keon Cohen Z, Ng I (2013) An ultrasound needle insertion guide in a porcine phantom model. *Anaesthesia* 68: 826-829.
19. Ball RD, Scouras NE, Orebaugh S, Wilde J, Sakai T (2012) Randomized, prospective, observational simulation study comparing residents' needle-guided vs free-hand ultrasound techniques for central venous catheter access. *Br J Anaesth* 2012; 108: 72-79.