

# Completely Disappear of Giant Lung Metastases of Pancreatic Cancer Treated with Gemcitabine and Oxaliplatin Chemotherapy: A Case Report

Yu Yuan<sup>1</sup> and Ren Cheng Sun<sup>2\*</sup>

<sup>1</sup>Department of Internal Medicine-Oncology, People's Hospital of Wei Fang, Shan Dong province, P.R China

<sup>2</sup>Department of Surgical Oncology, Wei Fang Traditional Chinese Hospital, Shan Dong province, P.R China

## Abstract

Pancreatic cancer is one of the most lethal cancers, most patients (80%) were diagnosed as inoperable advanced pancreatic cancer at the first time, and over 60% patients received operation relapsed within 2 years. Chemotherapy remains the mainly treatment for inoperable advanced or recurrent pancreatic cancer. Even though, gemcitabine and oxaliplatin was approved as a first-line therapy for advanced pancreatic cancer, their effect is unsatisfactory, especially for cases with distant metastases. In this paper, we report a case of lung metastases of pancreatic cancer showed complete response (CR) after received gemcitabine and oxaliplatin chemotherapy. This patient has a 9.5 cm × 9 cm × 7.5 cm size mass in right lung, three years after whipple procedure for pancreatic cancer. Then, the lung metastases disappeared completely, after 6 cycles of GEMOX. The result of this case report hints us GEMOX was a better choice for metastatic pancreatic cancer than other combination chemotherapy, especially for patients with distant metastasis to lung.

**Keywords:** Pancreatic cancer; Gemcitabine; Oxaliplatin

## Introduction

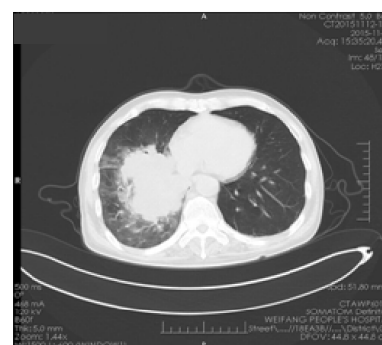Pancreatic cancer is one of the most lethal cancers, locally advanced cases have a median survival time range from 8 months to 12 months, only 3 months to 6 months [1] for cases with distant metastasis. Even though complete surgical resection is the most effective treatment, less than twenty percent of pancreatic cancers have surgical indication, again more than sixty percent of resected pancreatic cancers recurred within 2 years. To date, chemotherapy with or without radiotherapy is still the mainly therapy for these inoperable advanced or recurred cases.

As all know, recurrence of pancreatic cancer behaves as local recurrence and metastases. The metastases can arise in any organ site but mostly in abdominal sites. In an autopsy series, liver was founded to be the most common metastasis site, followed by peritoneum and lung. In the past, the incidence of recurrence in lung was considered to be 1% to 2%, however, the incidence was 13.6% in a more recent study, due to the more frequent use of CT scanning on chest. Pancreatic cancer with lung metastases are refractory to chemotherapy generally. Even patients who achieve remission through chemotherapy, the effect tends to be temporary, metastases are hard to eliminate completely, then the course becomes progressively fatal within a short period of time. Here, we report a case of lung metastases of pancreatic cancer that showed complete response (CR) to gemcitabine and oxaliplatin chemotherapy.

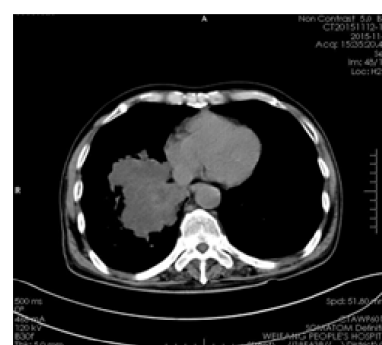## Case Report

A 62-year-old man received whipple procedure for pancreatic cancer in 2012 in Shandong University affiliated hospital. The histological type of pancreatic cancer is middle differentiated conducta denocarcinoma, and pathological staging is (T2a N0 M0/Stage 1B). After operation, the patient recovered successfully without any chemotherapy or radiotherapy for pancreatic cancer. Three years later, chest computed tomography (CT) scan on this patient showed a 9.5 cm × 9 cm × 7.5 cm size mass in the right lung (Figures 1 and 2). It was diagnosed as primary central lung cancer at the beginning, finally diagnosed as lung metastases of pancreatic cancer by fiberoptic bronchoscopy and biopsy.

Analysis the condition of the lung metastases and according to the guide line of 2015 NCCN, there was no opportunity to operate and the only effective therapy for this patient is chemotherapy or radiotherapy. Finally, we choose chemotherapy. To date, as we know, gemcitabine



**Figure 1:** Lung window 9.5 cm × 9 cm × 7.5 cm size mass in right lung.



**Figure 2:** Mediastinal window (9.5 cm × 9 cm × 7.5 cm size mass in right lung).

**\*Corresponding author:** Ren Cheng Sun, Department of Surgical Oncology, Wei Fang Traditional Chinese Hospital, Shan Dong province, P.R China, Tel: 0536-8236203; E-mail: [sunrencheng@126.com](mailto:sunrencheng@126.com)

**Received** May 08, 2017; **Accepted** June 15, 2017; **Published** June 22, 2017

**Citation:** Yuan Y, Sun RC (2017) Completely Disappear of Giant Lung Metastases of Pancreatic Cancer Treated with Gemcitabine and Oxaliplatin Chemotherapy: A Case Report. J Clin Case Rep 7: 984. doi: [10.4172/2165-7920.1000984](https://doi.org/10.4172/2165-7920.1000984)

**Copyright:** © 2017 Yuan Y, et al. This is an open-access article distributed under the terms of the Creative Commons Attribution License, which permits unrestricted use, distribution, and reproduction in any medium, provided the original author and source are credited.

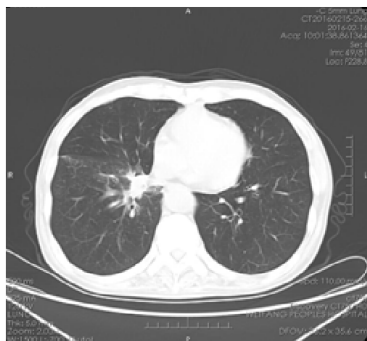

Figure 3: Complete disappear of pulmonary metastases (Lung window).

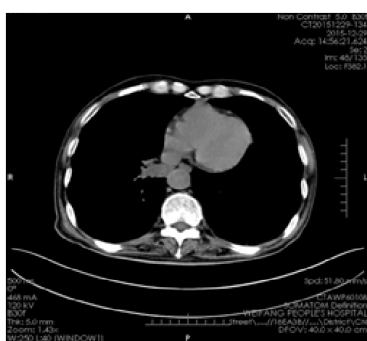


Figure 4: Complete disappear of pulmonary metastases (mediastinal window).

was approved as the first-line chemotherapy for advanced pancreatic cancer and gemcitabine plus oxaliplatin (GEMOX) regimen was better than GEM alone on terms of 6-month survival rate, 1-year survival rate, and objective remission rate [2], so we choose GEMOX regime for this patient.

Gemcitabine was commercially purchased (Heng Rui pharmaceutical factory, in China) as a lyophilized powder in 200 mg and 1000 mg vials and stored at room temperature. It was reconstituted with normal saline to yield a concentration of 40 mg/ml and administered as an i.v. infusion in 250 ml normal saline over 30 min. Oxaliplatin was commercially purchased (Qilu pharmaceutical factory, in China). Agreement with the NCI as a lyophilized powder in 50 mg and 100 mg vials and stored at room temperature in a light-protected package. It was reconstituted with 5% dextrose to yield a concentration of 5 mg/ml and administered as an i.v. infusion in 250 ml to 500 ml 5% dextrose water over 2 h. In an attempt to optimize the combination, Gemcitabine was administered on day 1 and Oxaliplatin was administered on day 2 after the observation that better activity was obtained *in vitro* with this schedule of administration and gemcitabine was given alone on day 8 of a planned 3-week cycle. Cycles of treatment were repeated every 3 weeks.

We started the first cycle in November 2015. After two and four cycles of GEMOX, Chest computed tomography CT revealed partial response. Then, after 6 cycles of GEMOX, Chest computed tomography CT revealed completely disappear of pulmonary metastases (Figures 3 and 4).

During five cycles ahead, there were no hematologic toxicity, the only side effects of chemotherapy is slight gastrointestinal toxicity, such as vomiting and constipation. In the sixth cycles, the patient occurred serious bone marrow suppression, with blood platelets was  $18 \times 10^9/l$ . Then, the blood platelets level of the patient recovery normal after received one therapeutical dose blood platelets and recombinant

human interleukin 11 for injection. Because of the serious bone marrow suppression during the sixth cycle, we change GEMOX to Gemcitabine single drug chemotherapy for the seventh and eighth cycle. At the end of eighth cycle, this patient occurred meningeal metastases in June 2, 2016 and died in July 2016 in short time received optimum supportive therapy.

## Discussion

Most patients (80%) present with inoperable advanced pancreatic cancer at the first time of diagnosis, and over 60% of patients received operation relapsed within 2 years. Chemotherapy remains the mainly treatment for these inoperable advanced and recurred pancreatic cancer.

In the past, single agent chemotherapy is the main treatment for advanced pancreatic cancer. However, no single agent can achieve a median survival time longer than 7 months, the response rate of single drug therapy was 0%, 5.4% and 9.5% for 5-FU, capecitabine and gemcitabine, respectively [3]. Even though gemcitabine was approved as a first-line therapy for advanced pancreatic cancer, combination chemotherapy was a necessary new alternative in patients with advanced pancreatic cancer, among of those combination chemotherapy, the response rate was 8.6%, 19.1%, 23.0%, 27% and 31.6% for Gemcitabine+erlotinib, Gemcitabine+apicitabine, Gemcitabine+nab-paclitaxel, FOLFIRINOX, GEMO [4] respectively. So FOLFIRINOX and GEMOX combination chemotherapy was a better choice for advanced and metastatic pancreatic cancer.

Generally, pancreatic cancer with distant metastasis is refractory to chemotherapy, and the complete response (CR) is a rare event. In the ACCORD 11 trial, there was only one complete response among the 171 patients with metastatic pancreatic cancer who received FOLFIRINOX (0.6%) [5], there was no complete response case in gemcitabine alone group. In Baize N [6] research, there were 4 complete response cases among 32 patients with metastatic or unresectable locally-advanced pancreatic cancer received GEMOX. In S.R. Alberts research, there were one complete response case among 18 patients with metastatic pancreatic cancer received GEMOX.

In this case report, with the maximum diameter of lung metastasis of pancreatic cancer 9.5 cm is rare, and the rarer is completely disappear of this metastasis, after six cycle GEMOX chemotherapy.

## Conclusion

In summary, the result of this case report and those researches hint us GEMOX was a better choice for metastatic pancreatic cancer than other combination chemotherapy, especially for patients with distant metastasis to lung.

## References

1. Ryan DP, Hong TS, Bardeesy N (2014) Pancreatic adenocarcinoma. N Engl J Med 371: 2140-2141.
2. Xie DR, Liang HL, Yang Q, Guo SS, Jiang ZM (2007) Meta-analysis on gemcitabine of fixed-dose rate infusion plus oxaliplatin as first-line therapy for advanced pancreatic cancer Ai Zheng 26: 895-899.
3. Lee HS, Park SW (2016) Systemic chemotherapy in advanced pancreatic cancer. Gut Liver 10: 340-347.
4. Louvet C, Labianca R, Hammel P (2005) Gemcitabine in combination with oxaliplatin compared with gemcitabine alone in locally advanced or metastatic pancreatic cancer: results of a GERCOR and GISCAD phase III trial. J Clin Oncol. 23: 3509-3516.
5. Conroy T, Desseigne F, Ychou M (2011) FOLFIRINOX versus gemcitabine for metastatic pancreatic cancer. N Engl J Med 364: 1817-1825.
6. Baize N, Abu SA, Berthier F (2005) Gemcitabine combined with oxaliplatin is safe and effective in patients with previously untreated advanced pancreatic adenocarcinoma. Gastroenterol Clin Biol. 29: 1006-1009.