

Convenient Evaluation of Magnitude of Glomerulonephritis in BXSB/Mp Lupus Mice

Emiko Takeuchi^{1*}, Misao Iizuka¹, Masaya Tamura¹ and Yasuo Takeuchi²

¹Department of Immunology, Kitasato University School of Medicine, Sagami-hara, Kanagawa 252-0374, Japan

²Department of Nephrology, Kitasato University School of Medicine, Sagami-hara, Kanagawa 252-0374, Japan

*Corresponding author: Emiko Takeuchi, Department of Immunology, Kitasato University School of Medicine, 1-15-1 Kitasato, Minamiku, Sagami-hara, Kanagawa 252-0374, Japan, Tel: 81 427 789266; Fax: 81 427 789266; E-mail: emichike@med.kitasato-u.ac.jp

Received date: Mar 03, 2014, Accepted date: Apr 15, 2014, Published date: Apr 22, 2014

Copyright: © 2014 Takeuchi E, et al. This is an open-access article distributed under the terms of the Creative Commons Attribution License, which permits unrestricted use, distribution, and reproduction in any medium, provided the original author and source are credited.

Abstract

Objective: Kidney involvement is one of the most important clinical features of systemic lupus erythematosus (SLE). Therefore, histopathological analysis of renal sections is necessary to evaluate the magnitude of lupus-like diseases. However, histopathological grading requires advanced pathological skills, otherwise the subjective views of the investigator can enter into evaluation. Here we show that in the case of a BXSB lupus mouse strain, the area and the long axis of glomeruli can be used as an objective index that can aid in the evaluation of the severity of lupus glomerulonephritis.

Methods: Previously, we investigated the effects of treatment that involved the induction of bone marrow chimerism to BXSB lupus mice. Based on the results of histopathological analysis and immunofluorescence staining, the progression grades of lupus glomerulonephritis of seven experimental groups were decided. Then, we re-evaluated the histopathological grade and the other elements of glomeruli in each experimental group. For the second examination, more than 30 glomeruli newly assessed on each section, and more than five sections from each group were analyzed. The area, long axis and short axis of all captured glomeruli were measured. The relationships between the histopathological score evaluated by two different pathologists, or between the mean histopathological scores and mean area and mean long/short axes of the glomeruli were analyzed using multiple linear regression.

Results: There was a direct correlation between two scores that were reported by two different pathologists. Glomeruli with severe inflammatory exudates were found to be easy to grade correctly, while it was more difficult to differentiate thickening of mesangial cells. In contrast, the mean area and the mean axis of glomeruli had a high correlation to histopathological grade even in the low-grade stages of the disease, when minimal thickening or proliferative mesangial changes have occurred.

Conclusion: The size of glomeruli correlates with the histopathological grade, especially the long axis of glomeruli, which is the easiest direction to measure. We thus conclude that this parameter can serve an auxiliary index of the severity of lupus glomerulonephritis in the BXSB lupus mouse strain.

Keywords: Lupus glomerulonephritis; Area of glomeruli; Long axis of glomeruli; Regression analysis; Regression line; BXSB; Histopathological grade

Introduction

Several strains of mice that express various symptoms similar to human systemic lupus erythematosus (SLE) are known as useful tools for studying human SLE.

Commonly, mouse strains that are used to study SLE model are characterized by spontaneous development of an immune complex-mediated nephropathy and production of a wide range of autoantibodies to nuclear components, including anti-nuclear antibodies, with accompanying splenomegaly and lymphadenopathy. These mice are usually die from lupus glomerulonephritis so that histopathological analysis is necessary to evaluate the development of autoimmune diseases in experiments using these SLE model mice. The magnitude of glomerulonephritis is graded according to the intensity

and extent of renal lesions. However, this grading requires advanced pathologic skills of more than two pathologists, otherwise the biases of the investigators can enter into evaluation. Moreover, the histopathological character of glomerulonephritis in SLE is occasionally that of cell proliferation dominance, or otherwise conspicuous immune deposits. These subtle distinctions sometimes cause pathologists to reach different conclusions regarding the condition involved. To avoid this problem, the severity of lupus glomerulonephritis in the mouse SLE model is usually evaluated by summing up or averaging immunofluorescent staining results with immunoglobulin or complement. However, frozen samples deteriorate if stored for a long time, causing problems when comparing present samples with previous samples. Thus, a constant and easily assessed histopathological parameter would serve as a very useful index of the severity of lupus glomerulonephritis.

Previously, we investigated the effects of treatments that involved the induction of bone marrow chimerism from major histocompatibility complex (MHC)-matched or MHC-mismatched

donors to BXSb lupus mice [1,2]. The BXSb mouse strain is one of the SLE mouse models that spontaneously develop a progressive lethal autoimmune disease, which is associated with positive serology to self-antigens (anti-double stranded [ds] DNA, single stranded [ss] DNA, erythrocytes, and platelet antibodies) and an immune complex-mediated nephropathy. Based on the assessment of the results of serological analysis, immunofluorescent study, histopathological grading and survival rate analysis, we concluded that the induction of allogeneic bone marrow chimerism ameliorates or reverses the autoimmune state, and MHC-matched bone marrow transplantation suppresses the development of autoimmune disease more effectively than fully MHC-mismatched bone marrow transplantation. Based on these previous data, we re-evaluated the histopathological elements of each experimental group. Here we show that in the BXSb lupus model the size of glomeruli correlates with the histopathologic grade, especially the long axis of glomeruli, which is the easiest direction to measure. We then conclude that this can serve as an auxiliary parameter of the severity of lupus glomerulonephritis.

Materials and Methods

Mice

Male BXSb (H-2^b) mice were purchased from Japan SLC, Inc. (Shizuoka, Japan). BALB/c (H-2^d) mice and C57BL/6 (H-2^b) mice were purchased from CLEA Japan, Inc. (Tokyo, Japan). BALB/c×C57BL6 F1 mice (H-2^{b/d}; referred to as F1 in this paper) were bred in our animal facility.

Histopathological analyses of renal tissues

Organs were fixed with 10% buffered formalin, and 3 μm sections were stained with Periodic Acid-Schiff (PAS) for histopathological examination under light microscopy. For semi-quantitative histological analysis, more than 30 glomeruli from each kidney section were examined. Glomerulonephritis was scored on a 0-4 scale modified from that described in a previous study [3], based on the intensity and extent of histopathological changes: 0, no glomerular lesions; 1, minimal thickening of the mesangium; 2, noticeable increase in both mesangial and glomerular capillary cellularity; 3, same as 2 with the addition of superimposed inflammatory exudates and capsular adhesions; 4, obliteration of the glomerular architecture (>70% of glomeruli). Kidneys were also snap-frozen at -80°C without prior fixation. Three-micron cryosections were transferred to Superfrost slides (Matsunami, Osaka, Japan). Sections were fixed with a mixture of methanol and acetone (1:1) at -20°C for 10min, washed with PBS three times, blocked with 1% BSA in PBS, and then stained with FITC-conjugated goat anti-mouse complement C3 (#55500, MP Biomedicals, Inc., Santa Ana, CA, USA). Complement-mediated glomerulonephritis was scored on a 0-3 scale, based on the staining pattern of the complement: 0, no complement fraction; 1, complement fraction confined to the mesangium, no clearly detectable deposits in the periphery of the capillary wall; 2, deposits mainly mesangial, but also along the capillary wall; 3, diffuse deposits in the mesangium but more abundant along the capillary wall [4,5]. Thirty glomeruli from each kidney section were scored from 0 to +3 independently by two investigators. Sections from at least three mice were analyzed in each group.

Measurement the size of glomeruli

More than 30 glomeruli on each PAS-stained kidney sections were captured by BZ-9000 microscope (Keyence Corp. Osaka Japan). The area, long axis and short axis of glomeruli were measured by a BZ-9000 Generation II Analyzer (Keyence Corp. Osaka Japan).

Statistical analysis

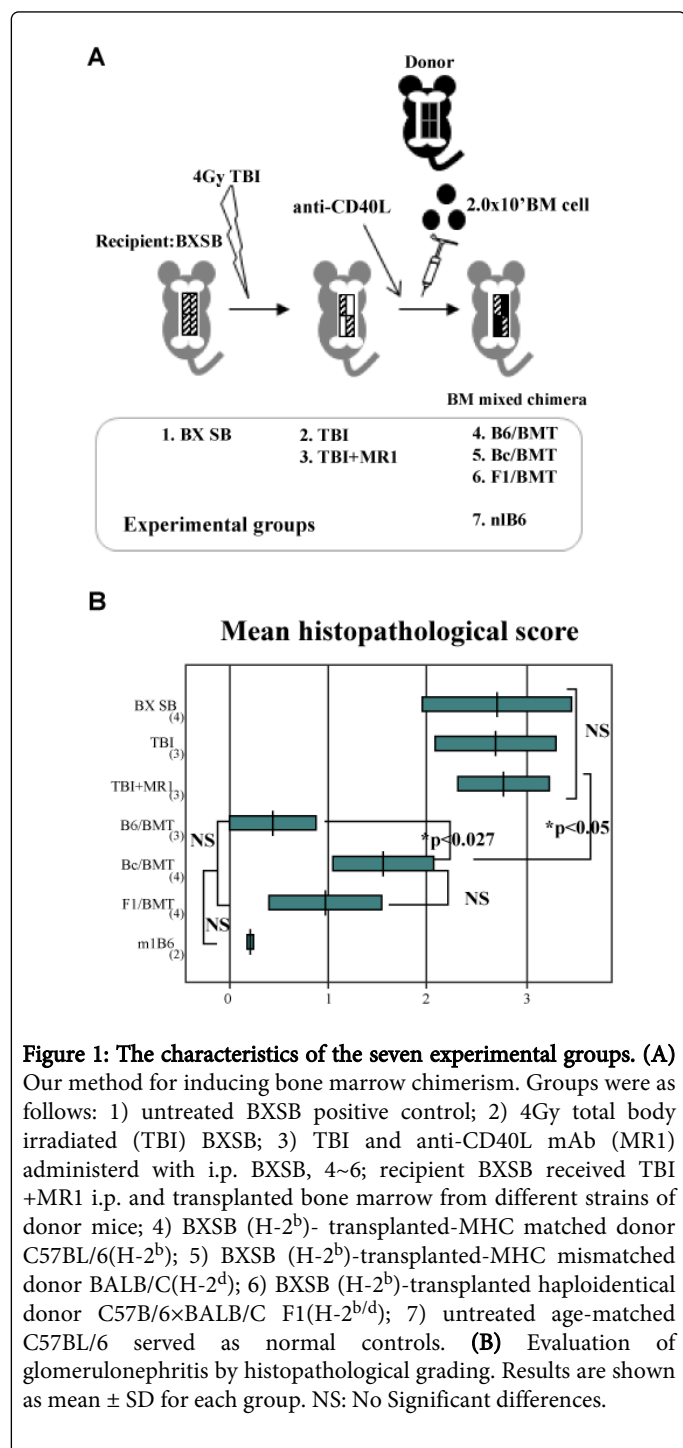
The relationships between the histopathological score evaluated by two different pathologists, or between the mean histopathological scores and mean area and mean long/short axes of glomeruli were analyzed using multiple linear regression. Results of histopathological score, the mean area of glomeruli and the mean long axis of glomeruli of each experimental group are expressed as means ± standard deviations (SD). Because the mean values calculated from each section in same experimental group follow as normal distribution, statistical analyses were performed with a paired t test between every two experimental groups. P values of <0.05 were considered to be significant. All descriptive statistical analyses were performed with the use of StatFlex statistical software (Ver.6, Artec Inc., Osaka, Japan).

Results

The magnitude of lupus-like glomerulonephritis could be graded according to several examinations in mouse experimental groups

The BXSb strain was one of the first SLE mouse models to be used for allogeneic bone marrow transplantation (BMT) [6]. Previously, we showed that cell transplantation of allogeneic non-lupus-prone bone marrow (BM) to BXSb lupus mice ameliorated lupus-like disease, especially complement-mediated glomerulonephritis. In that paper, we compared the lupus-like disease preventive effect in cases of induction-MHC-matched or haploidentical-donor BM with cases of induction-MHC-mismatched donor BM. Untreated BXSb mice were used as positive controls and C57BL/6 (B6) were used as healthy controls [1]. Because all recipient mice were treated with a nonmyeloablative dose of 4Gy total body irradiation (TBI) 1 day before BMT, and administered 2 mg of hamster anti-mouse CD40L monoclonal antibody (MR1) intraperitoneally, mice received TBI only and TBI+MR1 were used as conditional controls (Figure 1A). Histopathological examination of kidney sections stained with PAS was performed and immunofluorescence stained with complement C3 was performed to evaluate the magnitude of lupus-like glomerulonephritis in each experimental group. The results indicated that the progression magnitude of glomerulonephritis in the three experimental groups, which were untreated BXSb, TBI and TBI+MR1, were comparable. Allogeneic BM-transplanted chimeric mice groups showed different grades on histopathological examinations. The results of histopathological examination with PAS staining indicated that in chimeric BXSb mice that received fully MHC-matched BM (B6/BMT) or MHC haploidentical BM (F1/BMT), the development of lupus-like glomerulonephritis could almost be prevented by BM transplantation. However, the histopathological score of the mouse group that received fully MHC-mismatched BM (Bc/BMT) was higher than that of the other two BM chimeric groups (Figure 1B). The immunofluorescence samples stained with complement C3 appeared negative for C3 deposition in sections from all three chimeric groups. Further immunofluorescence analysis revealed that linear staining

patterns with IgM were more definitely observed than IgG on the glomeruli of kidney sections taken from fully MHC-mismatched chimeric mice (Table 1; part of the data based on our own findings) [7]. Neither IgG nor IgM staining patterns were observed on glomeruli taken from other two chimeric groups (data not shown). To summarize, the progression grades of lupus glomerulonephritis of each experimental groups were as follows: untreated BXSB = TBI = TBI+MR1 > Bc/BMT > B6/BMT = F1/BMT > normal B6 control.



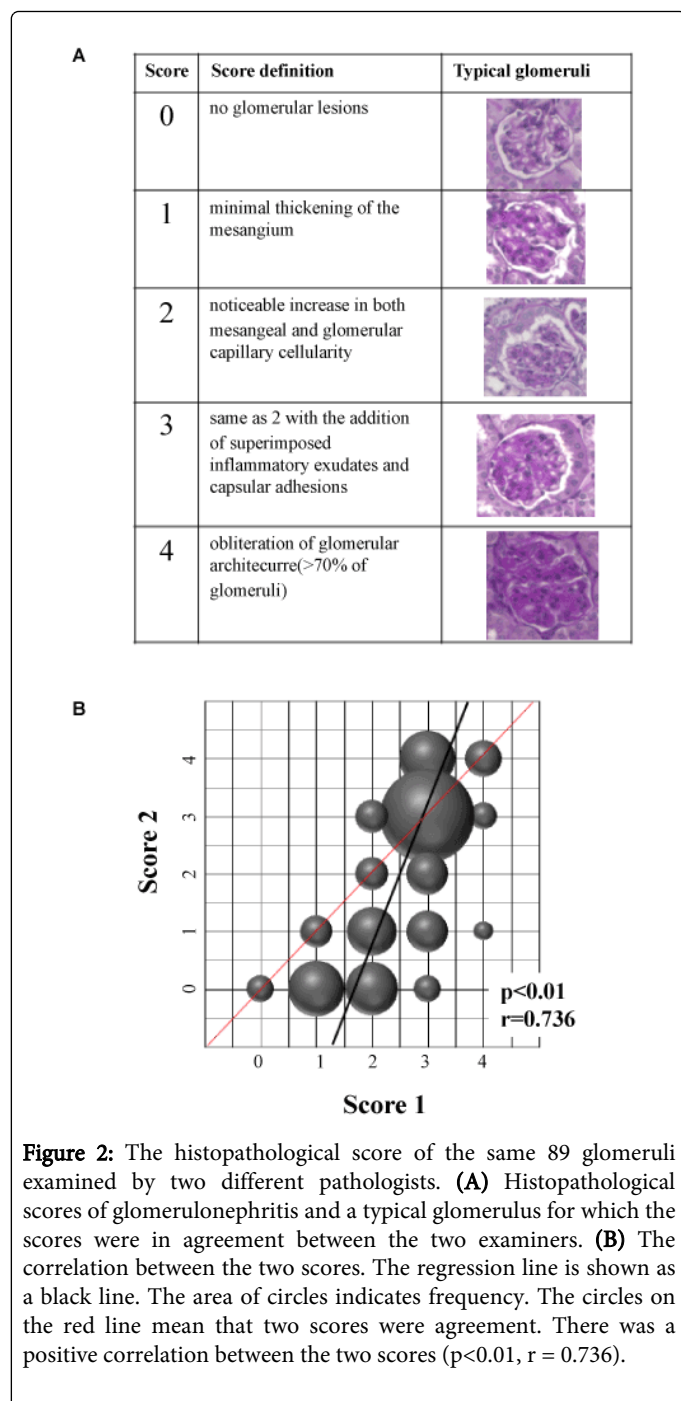
		C3	IgG	IgM
Treatment				
Untreated BXSB	1	+	-	-
	2	+	M	M
	3	+	M	M
	4	+	+	+
	5	+	+	+
Bc/BMT	1	M	+	+
	2	-	-	+
	3	-	-	+
	4	-	+	+
	5	-	-	+

+: Linear staining; -: Negative staining; M: Mesangial staining

Table 1: Immunofluorescence analysis.

The reliability of histopathological examinations by two different pathologists was confirmed by linear regression analysis

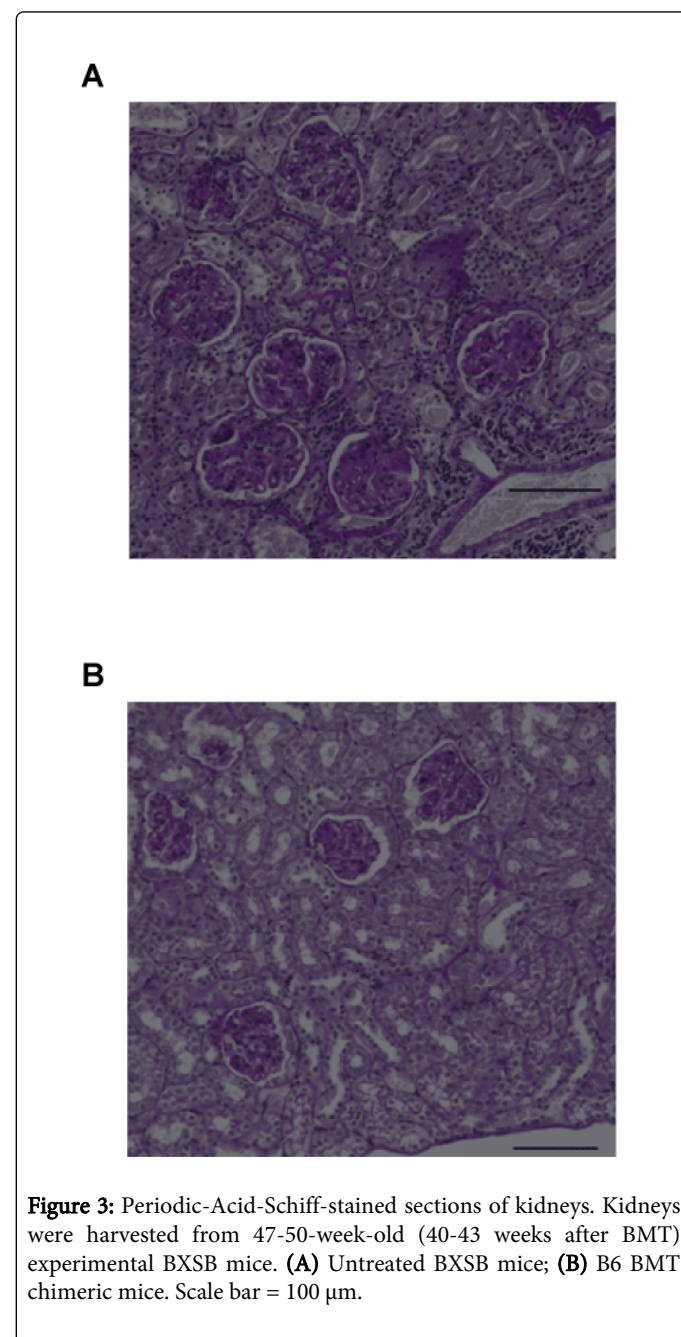
Consequently, histopathological examinations predicted heterogeneous deposition on the glomeruli taken from Bc/BMT chimeric mice. In order to exclude the possibility that biases of the pathologists could enter into histopathological examinations, we usually asked for the cooperation of more than two pathologists who did not know the expected results of the experiment. However, the criteria of judgment for histopathological scoring were ambiguous, as seen in the Materials and Methods section and Figure 2A. Therefore, first we compared the scores reported by two independent pathologists. Eighty-nine glomerulus pictures taken from one section in each of the seven experimental groups (untreated BXSB, TBI, TBI +MR1, Bc/BMT, B6/BMT, F1/BMT and B6) were shown to each examiner randomly, then two scores of the same glomeruli were compared. We next compared how their evaluations differed or agreed. Because the two examiners independently graded the glomeruli score from 0-4, (score1/score2=0/0~4/4). In Figure 2B, different size circles were plotted on coordinates, and the area of a circle indicates frequency. For example, the smallest circle (4, 1; score 1=4, score 2=1) means only one case, while the largest circle on (3, 3) means 26 cases. The black line is a regression line. There was a highly direct correlation ($r=0.736$, $p<0.01$) between score 1 and score 2 that were reported by the two different pathologists. The circles on the red line mean that the two scores were in agreement. One picture of a glomerulus for which the two scores were in agreement (on the red line in Figure 2B) is shown as a typical glomerulus in Figure 2A. These pictures and the high correlation coefficient indicate that the two pathologists recognized subtle differences in the glomerular lesions. In Figure 2B, the size of the circle on the red line has a tendency to increase as the line ascends to the upper right. In particular, the scores evaluated by two pathologists were in agreement on grade 3. This is because, for pathologists, glomeruli with severe inflammatory exudates are easy to grade correctly, while it is more difficult to differentiate differences in a color tone to evaluate thickening of mesangial cells. Therefore, it is thought that an objective auxiliary index would be useful to evaluate the magnitude especially in lower-grade glomeruli of lupus nephritis in the BXSB lupus mouse.



The size of glomeruli on sections taken from mice whose lupus-like disease was progressive was larger than that of mice in which the disease was in remission

The histopathologic character of glomerulonephritis in SLE model mouse is occasionally one of cell proliferation dominance, or otherwise conspicuous immune deposits. In either case, the size of glomeruli seemed generally larger in sections taken from mice that had progressive lupus-like disease than that in sections taken from mice in remission (Figure 3). In order to elucidate whether the grade of progressiveness of lupus-like disease was related with the size of

glomeruli, we analyzed the correlation between the mean histopathological score and the mean area of glomeruli. More than 30 glomeruli were analyzed on one section. Three mice were randomly selected from each of the seven experimental groups: untreated BXSB, TBI, TBI+MR1, B6/BMT, Bc/BMT, F1/BMT and normal B6. As shown in Figure 4A, there was a high direct correlation ($r = 0.774$, $p = 0.01$) between the mean score and the mean area of glomeruli. Moreover, there was a direct correlation between the mean score and the mean long axis of glomeruli ($r = 0.797$, $p = 0.01$) or the mean short axis ($r = 0.759$, $p = 0.01$) (Figure 4B and 4C). These levels of correlation are comparable to those between the means of the area and the histopathological scores.



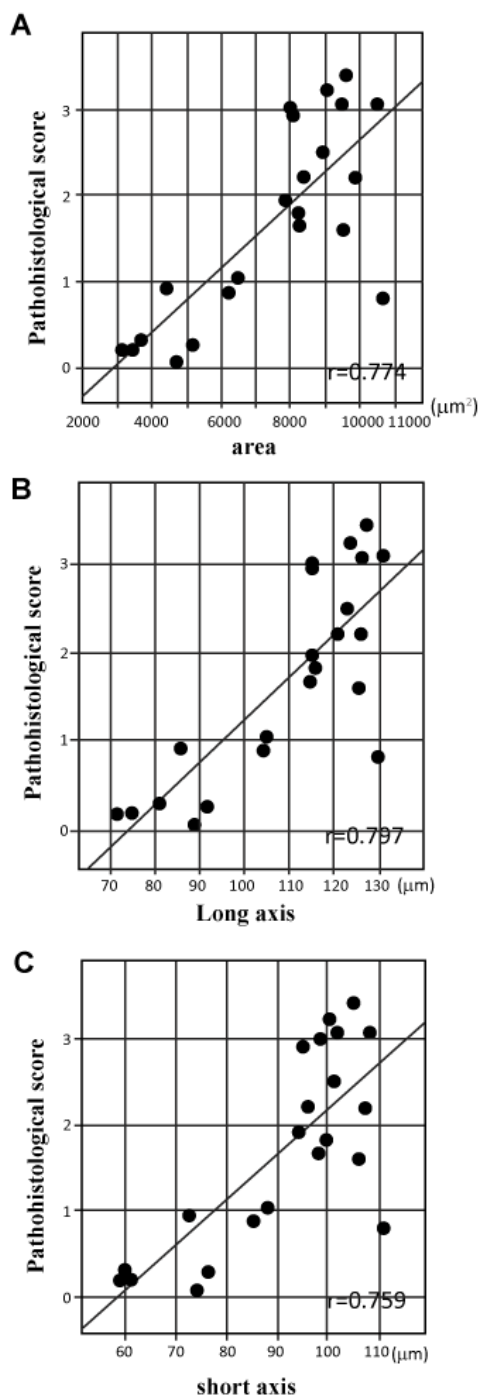


Figure 4: Relationship between the mean of the histopathological score of one section and the mean value of the size of glomeruli of same section. (A) There was a positive correlation between the mean of the histopathological score and the mean of area of glomeruli ($r = 0.774$). (B) Positive correlation between the mean of score and the mean of the long axis ($r = 0.797$). (C) Positive correlation between the mean of the score and the mean of the long axis ($r = 0.759$). Regression lines are shown as black lines. $p < 0.01$.

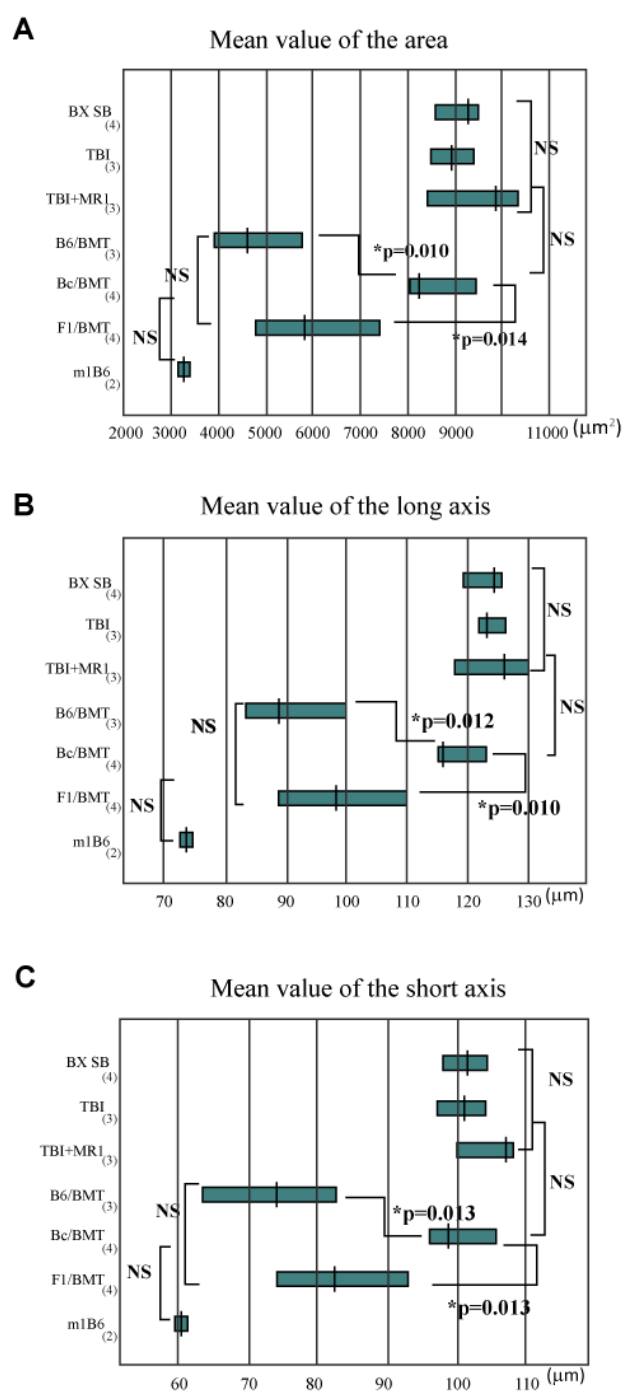


Figure 5: Comparison of size of glomeruli between the seven experimental groups. (A) The mean value of the area of the glomeruli, (B) the long-axis of the glomeruli, (C) and the short-axis of the glomeruli. Results are shown as mean \pm SD for each group. NS: No Significant difference.

Measurements of area or long/short axis can be substituted for histopathological scoring

As shown in Figure 4, the mean area or long/short axes of glomeruli has a high correlation to the histopathological score. In order to confirm that the mean area or axis were comparable in each experimental group, the magnitude of lupus-like glomerulonephritis between each experimental group can be graded in the same manner as the histopathological score. As shown in Figure 5, there were no significant differences between the groups of untreated BXSb, TBI, TBI+MR1, or the groups of nl B6, B6/BMT, F1/BMT mice with regard to mean area and mean long/short axes in mice classified with the same histopathological score. However, the grade of glomerulonephritis in Bc/BMT was evaluated differently from histopathological scoring. As mentioned above, the magnitude of lupus-like glomerulonephritis in Bc/BMT was more severe than that of B6/BMT or F1/BMT, though the development of this disease was found to be prevented in sections of Bc/BMT mice, while it had developed in the untreated or irradiation control groups. One possible reason for this is that in the Bc/BMT group, glomeruli were mainly expanded by mesangial cell proliferation. We observed few or no sclerotic glomeruli that were obliterated by immunodepositions. Although in the untreated or irradiated control groups, several large glomeruli were obliterated of their glomerular architecture by superimposed inflammatory exudates. Therefore, the histopathological scores in the Bc/BMT group were lower than those in the untreated or irradiated control groups even if the size of glomeruli were comparable. However, as shown in Figure 2B, the grading of the thickening and the proliferation of the mesangium was quite different between two examiners, despite the fact that the evaluations of glomeruli with remarkable adhesions were not in marked disagreement. Thus, the measurement of the area or length of glomeruli might serve as a helpful index to distinguish small changes in the mesangium.

Discussion

Several mouse models of SLE are useful for investigating the mechanism(s) how human SLE develops. They are also useful for evaluating the potential for human testing and eventual clinical application. In experiments using animal models, it is necessary to examine many individual animals and to compare the severity of several experimental groups within that species, which necessitates analyzing several samples at one time. To evaluate the development of SLE, serological analysis, especially autoantibodies to nuclear components, is one useful quantitative index. Usually, but not always, the titer of autoantibodies in serum stored at -80°C will change little, which allows for retrospective serological analysis. On the other hand, frozen kidney samples deteriorate if stored for a long time, even if stored at -80°C. Therefore, a constant histopathological element is necessary for retrospective analysis. There is some correlation between the presence or absence of certain anti-nuclear antibodies and clinical manifestations. In particular, high titers of dsDNA antibodies are usually associated with active renal disease in clinical situations. In human SLE, it is thought that the pathogenesis of glomerulonephritis involves the deposition of DNA-anti-DNA antibody complexes within the glomeruli. However, in our experimental model, even if certain histopathological changes of glomeruli were observed, the linear staining pattern of IgG and/or C3 was not always observed.

It is well known that the Y chromosome-linked autoimmune acceleration (Yaa) gene of BXSb mice was identified as one of the

genes responsible for the development of the disease. It has recently been demonstrated that the translocation of a cluster of X-linked genes onto the Y chromosome is the genetic lesion underlying Yaa. In male mice carrying Yaa, the transcription of several genes within the translocated segment is increased roughly twofold. Although the X chromosome segment that is located in Yaa may contain 16 genes, the major candidate gene for the causation of the Yaa-associated autoimmune phenotype is the Toll-like receptor (TLR) 7 [8]. It was reported that up-regulation of TLR7 was responsible for splenomegaly, glomerulonephritis, and the infiltration and activation of leukocytes in the kidney. However, the resolution of TLR7 up-regulation did not eliminate the enhanced humoral autoimmunity [9]. The DNA-anti-DNA antibody complexes may trigger lupus glomerulonephritis via TLR, but they may not be required for the development of glomerulonephritis. To investigate how autoreactive antibodies induce renal disease, the levels of lupus glomerulonephritis must be evaluated independently via serological analysis.

Kidney involvement is one of the most important clinical features of SLE, with renal failure being the most common cause of death both in humans and in mice. In a clinical situation, however, pathological examination is generally the final diagnostic method to confirm the disease. This involves assessing all clinical symptoms and laboratory data, and therefore, a qualitative evaluation may be more important than a quantitative evaluation. Thus, an objective histopathological index is required to grade the magnitude of glomerulonephritis in animal experiments. In experiments using lupus-like animal models, pathologists have to examine many samples at once. For example, in our experimental model, more than 30 glomeruli on one section, and more than five sections from each group were examined. In total, more than 1000 glomeruli had to be examined by two independent pathologists. It is hardly possible that 1000 glomeruli can be examined with consistent objectivity. Despite the possibility of observer bias, evidence from pathological examinations by pathologists is still necessary for an accurate diagnosis. Thus, we believe that an objective index that is easy to score is useful for the diagnosis lupus glomerulonephritis. In this paper, we revealed that the size of glomeruli correlates with the severity of lupus-like glomerulonephritis in BXSb. In particular, the mean area of glomeruli, and the mean axis of glomeruli correlated directly with the mean histopathological scores. This positive correlation does not automatically imply a direct causal relationship. However, we speculate that on developing lupus-like glomerulonephritis, mesangial cell proliferation and deposition of immune-complexes may lead to glomeruli expansion. Whatever the cases, more data based on the study of additional mouse strains is needed to draw firm conclusions.

It is thought that measurement of the area of a glomerulus is more suitable than measurement of its axis for evaluating the size of a glomerulus. However, our statistical analysis showed that the correlation of the pathological score with both area and long/short axes were comparable. If so, the measurement of the long axis of a glomerulus is easier than that of area. This is because in order to measure the area of a glomerulus, which tend to be irregular in shape, some special approaches or tools are needed, while measuring the long axis only requires a type of ruler.

The mean value of the long axis of a glomerulus of a section taken from one individual animal can be applicable as an objective index to evaluate the magnitude of lupus-like glomerulonephritis in BXSb lupus mice, especially during the low-grade stages of the disease, when minimal thickening or proliferative mesangial changes have occurred.

Acknowledgements

This work was supported in part by a JSPS KAKENHI Grant-in Aid for Scientific Research (C) 24591469.

Conflict of interest

The authors declare no conflicts of interest. The authors alone are responsible for the content and writing of the paper.

References

1. Takeuchi E, Shinohara N, Takeuchi Y (2011) Cognate interaction plays a key role in the surveillance of autoreactive B cells in induced mixed bone marrow chimerism in BXSb lupus mice. *Autoimmunity* 44: 363-372.
2. Takeuchi E, Takeuchi Y (2007) Allogeneic mixed chimerism induced by nonlymphoablative regimen including donor BMT with low-dose TBI and anti-CD40L cured proliferative glomerulonephritis in lupus mice. *Ann NY Acad Sci* 1110: 362-367.
3. Wang B, Yamamoto Y, El-Badri NS, Good RA (1999) Effective treatment of autoimmune disease and progressive renal disease by mixed bone-marrow transplantation that establishes a stable mixed chimerism in BXSb recipient mice. *Proc Natl Acad Sci U S A* 96: 3012-3016.
4. Banfi G, Mazzucco G, Barbiano di Belgiojoso G, Bestetti Bosisio M, Stratta P, et al. (1985) Morphological parameters in lupus nephritis: their relevance for classification and relationship with clinical and histological findings and outcome. *Q J Med* 55: 153-168.
5. Nossent H, Berden J, Swaak T (2000) Renal immunofluorescence and the prediction of renal outcome in patients with proliferative lupus nephritis. *Lupus* 9: 504-510.
6. Jones OY, Steele A, Jones JM, Marikar Y, Chang Y, et al. (2004) Nonmyeloablative bone marrow transplantation of BXSb lupus mice using fully matched allogeneic donor cells from green fluorescent protein transgenic mice. *J Immunol* 172: 5415-5419.
7. Takeuchi E (2011) Mixed Hematopoietic Chimerism Allows Cure of Autoimmune Glomerulonephritis: Its Potential and Risks. In: Prabhakar SS (Ed) *An Update on Glomerulopathies - Clinical and Treatment Aspects*. INTECK, Rijeka, Croatia, pp: 277-290.
8. Pisitkun P, Deane JA, Difilippantonio MJ, Tarasenko T, Satterthwaite AB, et al. (2006) Autoreactive B cell responses to RNA-related antigens due to TLR7 gene duplication. *Science* 312: 1669-1672.
9. Fairhurst AM, Hwang SH, Wang A, Tian XH, Boudreaux C, et al. (2008) Yaa autoimmune phenotypes are conferred by overexpression of TLR7. *Eur J Immunol* 38: 1971-1978.

This article was originally published in a special issue, entitled: "**Systemic Lupus Erythematosus**", Edited by Dr. Kaihong Su, University of Nebraska Medical Center, USA