

Coronary Computed Tomography: Identification of a Novel Type of Dual Left Anterior Descending Coronary Artery Circulation

Kinan Carlos El-Tallawi¹, Charbel Saade², Wael AlJaroudi¹ and Antoine Abchee^{1*}

¹Department of Internal Medicine, American University of Beirut Medical Center, Beirut, Lebanon

²Department of Diagnostic Radiology, American University of Beirut Medical Center, Beirut, Lebanon

*Corresponding author: Antoine Abchee, Department of Internal Medicine (Cardiology Division/Cardiac Imaging Section), American University of Beirut Medical Center, Beirut-11-0236, Lebanon, Tel: +9611350000; E-mail: aa14@aub.edu.lb

Received date: June 16, 2015; Accepted date: July 20, 2015; Published date: July 28, 2015

Copyright: ©2015 El-Tallawi KC, et al. This is an open-access article distributed under the terms of the Creative Commons Attribution License, which permits unrestricted use, distribution, and reproduction in any medium, provided the original author and source are credited.

Abstract

Coronary computed tomography angiography (CCTA) has many advantages over invasive coronary angiography. It allows the detection of anomalous vessels and their relationship to heart structures. Dual left anterior descending coronary artery (LAD) anomaly is defined by the presence of two LADs. It is categorized on the basis of a long and short LAD. We present a novel type in which one long LAD branches from the right coronary artery (RCA) and the other LAD, a long vessel as well, branches from the left main coronary artery (LMCA). They course in parallel to terminate at the apex. This pattern defies the current short-long classification. We suggest it to be a novel pattern.

Keywords: Coronary artery anomalies; Dual LAD; Coronary CT angiography

Abbreviations:

A: Ascending Aorta; P: Pulmonary Artery; LM: Left Main Coronary Artery; RCA: Right Coronary Artery; LCX: Left Circumflex Artery; SLAD: Short Left Anterior Descending Artery; LLAD: Long Left Anterior Descending Artery; D: Diagonal Coronary Artery; S: Septal Coronary Artery.

Introduction

In the vast majority of people, the LAD coronary artery branches out of the left main coronary artery (LMCA) shaft and courses along the anterior inter-ventricular groove (AIVG) all the way toward the apex of the heart. The presence of two LAD coronary arteries, referred to as the dual LAD anomaly, is a very uncommon occurrence in which there are two LAD arteries. Spindola-Franco et al. have initially described and characterized the first four types of this anomaly based on the origin and course of both a short and a long branch of the LAD [1] (Figure 1). Since then, with the increase in the number of performed invasive coronary angiographies, and more importantly with the advent of CCTA, new types were described mainly through case reports. A recent large series reviewing CCTA's was able to identify a total of nine types that fit under the umbrella of the dual LAD anomaly [2].

Case Presentation

We present a case of a 51-year-old male patient who presented with atypical chest pain. As part of his work-up and coronary artery disease (CAD) risk stratification, he underwent a CCTA scan at our institution. The "short" LAD (left long LAD) was not actually short since it branched out of the LMCA and coursed along the epicardial surface of the left ventricular anterior wall all the way to the apex of the heart. It gave rise to proximal septal perforators (S), along with two

diagonal branches that supply the antero-lateral wall of the left ventricle. The other long LAD (right long LAD) branched out of the RCA and coursed along the epicardial surface of the right ventricle (RV) and into and along the distal half of the AIVG. Both LAD arteries were similar in length (Figures 2 and 3). This pattern carries striking similarity to the type IV subtype in that the right-sided LAD branches out of the proximal RCA and the left sided LAD branches out of the LMCA. However, the difference lies in the left long LAD's length, course, and termination.

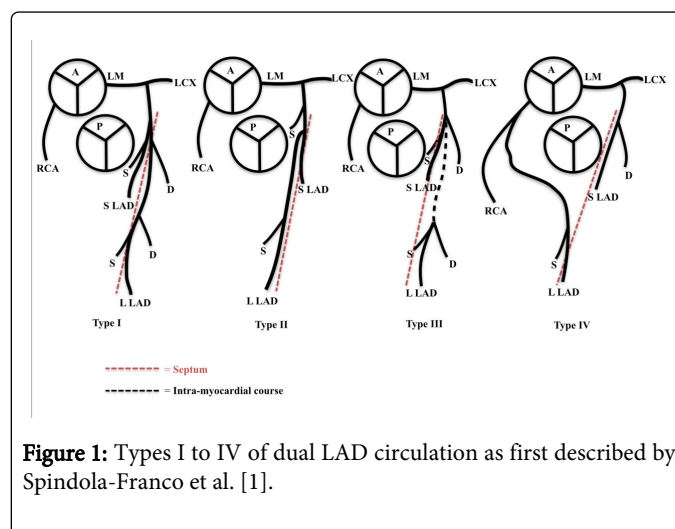


Figure 1: Types I to IV of dual LAD circulation as first described by Spindola-Franco et al. [1].

Discussion

Dual LAD circulation has been reported to occur with an incidence of around 1% on invasive coronary angiography [1]. Type I is the most prevalent and is characterized by one short and one long LAD which both branch off the LMCA and supply the proximal and distal AIVG, respectively (Figure 1); It constituted more than 85% of the cases in one of the series that reviewed a large number of CCTAs [2]. The

other types are relatively rare and have been mostly described in case reports.

As previously mentioned, our case does not fit any of the 9 types described thus far. The origin of the vessels is similar to type IV in that the left LAD branches off the LMCA and the right LAD branches off the proximal RCA (Figures 1 and 2). However, the left long LAD course clearly differs and does not follow the pattern of any of the other types. What is even more interesting is that our case even defies the classification system proposed by Spindola-Franco et al., which constitutes the basis for this categorization, and relies on the fact that there is one short and one long LAD. In our case we depict a left long and a right long LAD, a pattern which to our knowledge has not been previously described in the medical literature.

The dual LAD anatomy was noticed to have more frequent associations with other coronary anatomic variants. Coronary artery bridging was more prevalent in people with this anomaly even after taking into account the fact that CCTA uncovers more bridged segments as compared to invasive angiography. The existence of a ramus intermedius branch was also found more frequently [2]. Dual LAD circulation may also be associated with congenital heart disease such as tetralogy of Fallot and transposition of the great arteries [3]. Awareness of this aberrant circulation is essential when surgery is to be considered for these congenital anomalies.

Identifying specific coronary artery anomalies and characterizing their respective anatomy is usually difficult with catheter coronary angiography alone due to the unavailability of spatial information regarding the origin and course of the coronary arteries in relation to the different heart structures. This becomes a critical issue whenever an anomalous artery courses in between the aorta and the right ventricular outflow tract as in type VI. In this type there is similarity to the previously described type IV with respect to both the vessels origin and the short LAD course.

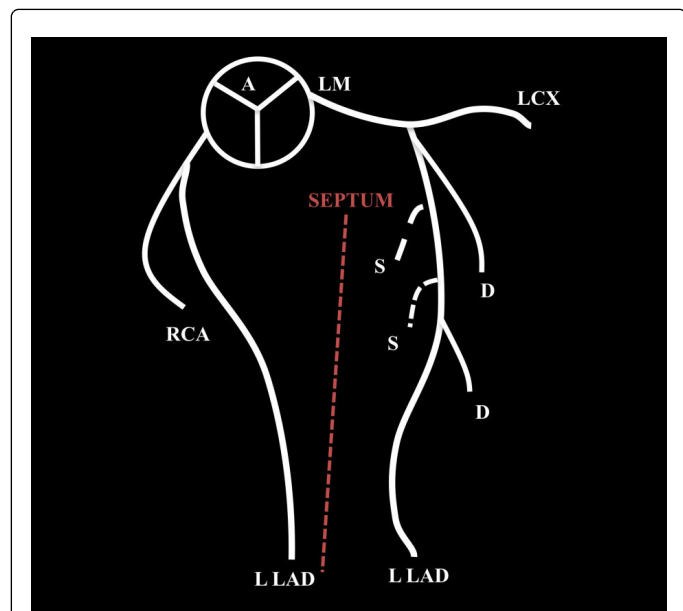


Figure 2: Schematic illustration of our novel dual LAD pattern depicting the relationship of the two long LADs to the interventricular septum.

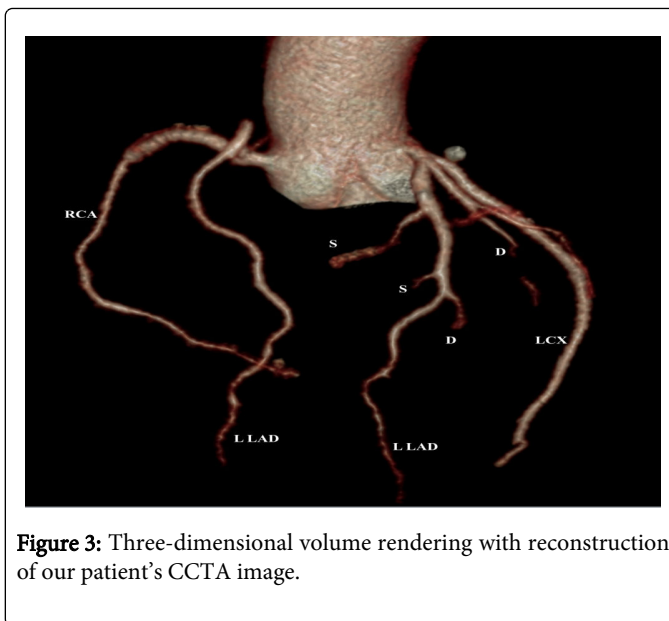


Figure 3: Three-dimensional volume rendering with reconstruction of our patient's CCTA image.

However, the long LAD, instead of coursing on the epicardial surface of the RV as in type IV, takes a course in between the right ventricular outflow tract and the aortic root [4]. This course taken by the long LAD in the type VI will put the vessel at risk of compression with blood flow compromise and resultant sudden cardiac death in situations of increased pulmonary blood flow [5]. Therefore, CCTA is essential whenever dual LAD anomaly is discovered on invasive coronary angiography since it confers adequate comprehension of the relationship of the coronary artery tree to other heart structures and thus allows prompt identification of higher risk types.

In general, it is thought that dual LAD circulation carries a benign course. However, recognizing this anomaly is of utter importance in the context of accompanying coronary artery disease since it is sometimes difficult to differentiate it from a total LAD occlusion on catheter angiography [6]. This can be the case when one of the LADs branches off the right coronary sinus like in our patient. In this situation, if a patient with chest pain undergoes catheter coronary angiography the operator might falsely interpret the angiogram as a total LAD occlusion. Within this same context, being both aware and familiar with this anomaly is extremely essential for the adequate planning and management of associated coronary artery disease, whether it was through percutaneous coronary interventions or coronary artery bypass grafting.

Conclusion

Evaluation of complex coronary architecture in patients with congenital coronary anomalies has been significantly improved with coronary computed tomography angiography. Of these anomalies, dual LAD circulation is considered a rare entity that encompasses up to nine described subtypes that have all been categorized based on the presence of a long and a short LAD. We report in this case a novel subtype which bears some similarity to Type IV but does not fit this historical classification scheme in that both LADs are long vessels running in parallel to supply the antero-septal portion of the left ventricle and terminating at the apex of the heart.

References

1. Spindola-Franco H, Grose R, Solomon N (1983) Dual left anterior descending coronary artery: angiographic description of important variants and surgical implications. *Am Heart J* 105: 445-455.
2. Bozlar U, Ugurel MS, Sari S, Akgun V, Ors F, et al. (2015) Prevalence of dual left anterior descending artery variations in CT angiography. *Diagn Interv Radiol* 21: 34-41.
3. Sajja LR, Farooqi A, Shaik MS, Yarlagadda RB, Baruah DK, et al. (2000) Dual left anterior descending coronary artery: surgical revascularization in 4 patients. *Tex Heart Inst J* 27: 292-296.
4. Maroney J, Klein LW (2012) Report of a new anomaly of the left anterior descending artery: type VI dual LAD. *Catheter Cardiovasc Interv* 80: 626-629.
5. Patel S (2008) Normal and anomalous anatomy of the coronary arteries. *Semin Roentgenol* 43: 100-112.
6. Agarwal PP, Kazerooni EA (2008) Dual left anterior descending coronary artery: CT findings. *AJR Am J Roentgenol* 191: 1698-1701.