

# Coronary Stent Infection: A Rare but Severe Complication of Percutaneous Coronary Intervention

Deepa Lalwala<sup>1\*</sup>, Manoj Deshmukh<sup>1</sup>, Shruti Mehta<sup>2</sup> and Vasant Nagvekar<sup>2</sup>

<sup>1</sup>Department of Radiology, Lilavati Hospital and Research Centre, Mumbai, Maharashtra, India

<sup>2</sup>Department of Medicine, Lilavati Hospital and Research Centre, Mumbai, Maharashtra, India

## Abstract

Although rare, coronary artery stent infections are associated with a high mortality rate. Since the introduction of coronary stents in 1987, only few cases of infection have been reported. We report a new case in a 57-year-old man who had undergone a difficult percutaneous coronary intervention procedure, during which four stents were placed in dominant main right coronary artery and left anterior descending, left circumflex-obtuse marginal artery. Within two months of procedure, patient presented four-five episodes of fever, was treated and discharged as all investigation were normal. After 2-month post-procedure patient was readmitted with fever. Only WBC count and CRP were raised, rest investigations were normal. As suspicious of infective endocarditis, CT coronary angiography was advised. CT showed pseudo aneurysm arising from right coronary artery just distal to its origin adjacent to stent with evidence of surrounding extensive fat stranding and soft tissue thickening. PET scan was done to find out cause of pyrexia of unknown origin, showed low to moderate grade metabolic activity along the root of aorta and adjacent to stent in right RCA. Patient started on IV antibiotic and angiography was planned. CAG showed proximal RCA pseudo aneurysm with patent distal artery. Aneurysmectomy was done along with RCA stent removal and CABG. Coronary stent cultures show growth of *Pseudomonas* and *Staphylococcus hominis*. We conducted a review of the literature on coronary artery stent infections. Data suggest that early-onset infections (<10 days after stent implantation) are potentially amenable to medical therapy alone, but late-onset infections (≥ 10 days after implantation) or major complications necessitate combined surgical and medical therapy. Medical therapy consists of broad-spectrum antibiotics. Surgical intervention includes stent removal if possible, and abscess drainage or perforation repair when indicated.

**Keywords:** Blood vessel prosthesis implantation effects; *Pseudomonas*; *Staphylococcus*; Coronary stent infections; Prosthesis-related infections/complications/diagnosis/therapy; Stents/adverse effects

## Introduction

During the last two decades, Percutaneous Transluminal Coronary Angioplasty (PTCA) with metal stent placement has become a well-developed treatment modality for coronary stenotic lesions. Although infection involving implanted stent is rare, it can, however, occur with high morbidity and mortality. Foreign body implantation predisposes to the development of infections by damaging or invading epithelial or mucosal barriers, by supporting growth of micro-organisms and by impairing host defense mechanisms. Indeed, implantation of medical devices represents one of the most important risk factors for nosocomial infections, accounting for an estimated 45% of all nosocomial infections [1,2]. We describe an inserted coronary stent that was infected and complicated with pseudo aneurysm formation and severe sepsis. In an effort to raise awareness of the possible fatal outcome of this situation, we herein report our experience.

## Case Report

A 57-year-old male, known case of diabetes and hypertension, presented with chest pain. 2D echo shows, ejection fraction was 35%. Coronary angioplasty advised, shows main right coronary artery, left anterior descending, left circumflex-obtuse marginal artery disease. Percutaneous coronary intervention has been done with four stent placements (Figures 1 and 2). 7<sup>th</sup> days post-procedure, patient presented with high grade fever with chills, treated and discharged. He was admitted multiple times with complaint of fever within two months and treated. All investigations were normal. Patient got readmitted after 2-months with complaints of Fever with chills for 2 days associated with malaise [3]. As a history of recurrent episodes of

fever after percutaneous coronary intervention, WBC count and CRP were raised, other investigations were normal, suspicion of infective endocarditis has been made. Patient was referred to MRI department for CT coronary angiography. It showed 2.8 × 2.3 × 1.8 cm pseudo aneurysm arising from proximal RCA just adjacent to Ostial origin, few wall calcifications are seen in Figures 3-7. There is extensive fat stranding noted adjacent to pseudo aneurysm and RCA stent (Figure 2). PET scan was advised as to find out cause of pyrexia of unknown origin, showed low to moderate grade metabolic activity along the root of aorta and along proximal RCA adjacent to stent (Figures 5 and 6), diagnosis has been given as inflammatory infective etiology.

Based on above mentioned investigation, suspicion of infective endocarditis with its complication pseudo aneurysm was made. Patient kept on IV antibiotics Meropenem and IV Tobramycin. WBC counts were still increasing. Conventional angiography was planned as suspicion of stent infection, CAG showed proximal RCA pseudo aneurysm with patent distal stents (Figure 8).

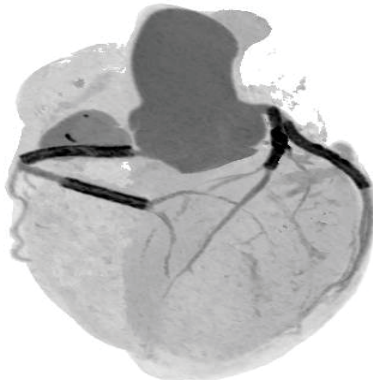Surgical exploration was done, Aneurysmectomy along with RCA stent removal and CABG were done and coronary stent cultures sent. Stent culture showed growth of *Pseudomonas* and *Staphylococcus*

**\*Corresponding author:** Deepa Lalwala, DNB Trainee, Department of Radiology, Lilavati Hospital and Research Centre, A-791, Bandra Reclamation Bandra West Mumbai, Maharashtra 400050, India, Tel: 91 9979792147; E-mail: [deepalalwala@gmail.com](mailto:deepalalwala@gmail.com)

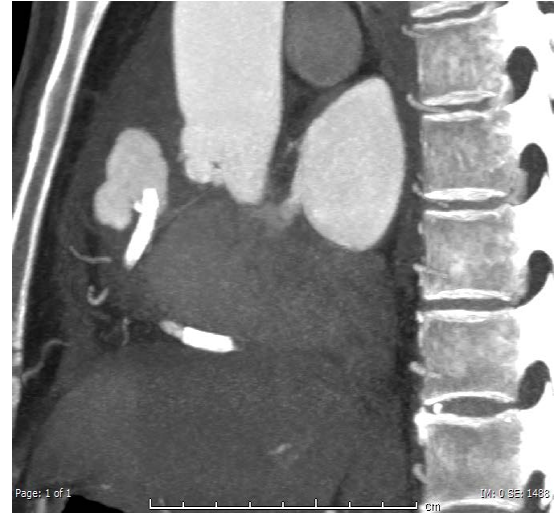Received July 07, 2018; Accepted July 30, 2018; Published August 05, 2018

**Citation:** Lalwala D, Deshmukh M, Mehta S, Nagvekar V (2018) Coronary Stent Infection: A Rare but Severe Complication of Percutaneous Coronary Intervention. J Cardiovasc Dis Diagn 6: 334. doi: [10.4172/2329-9517.1000334](https://doi.org/10.4172/2329-9517.1000334)

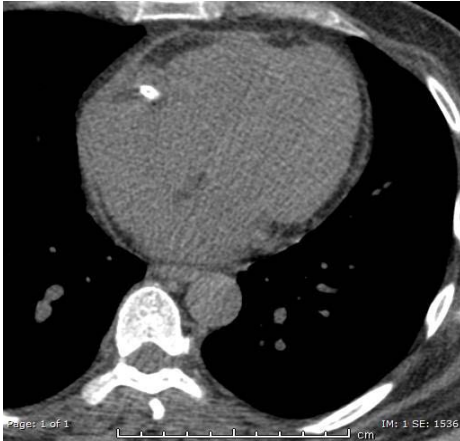
**Copyright:** © 2018 Lalwala D, et al. This is an open-access article distributed under the terms of the Creative Commons Attribution License, which permits unrestricted use, distribution, and reproduction in any medium, provided the original author and source are credited.



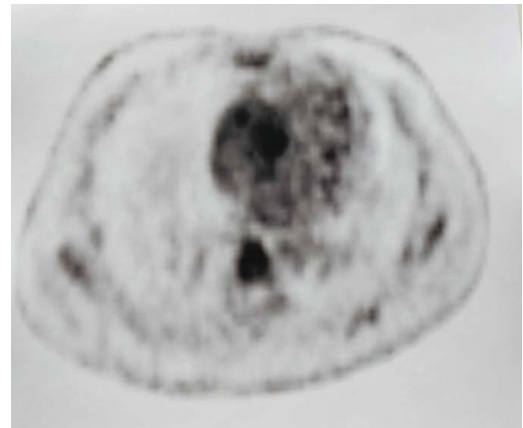
**Figure 1:** CT coronary angiography: Image 1-VRT image of coronary angiography shows four stents in proximal and distal RCA, proximal LAD and circumflex artery.



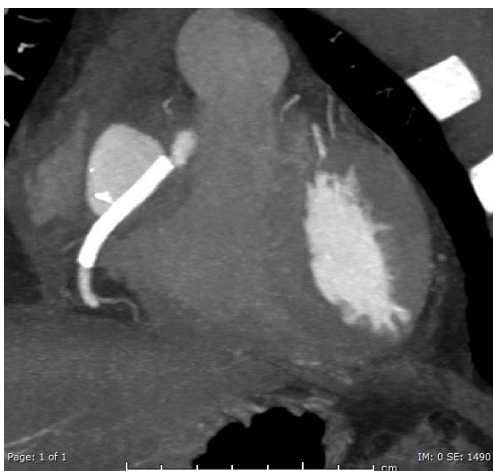**Figure 4:** CT coronary angiography-contrast study: Post contrast axial and sagittal section shows pseudo aneurysm arising from proximal RCA Adjacent to coronary stent.



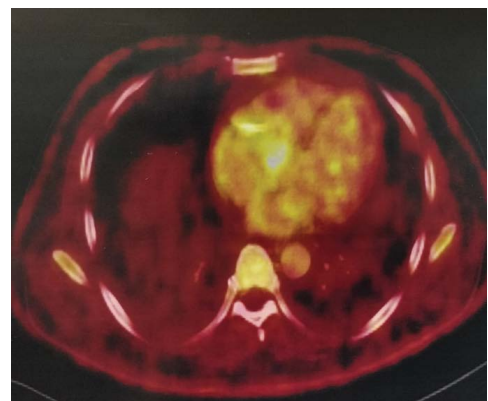
**Figure 2:** CT coronary angiography: Image 2-non-contrast axial section shows extensive fat stranding with effacement of fat plane adjacent to proximal right RCA stent.



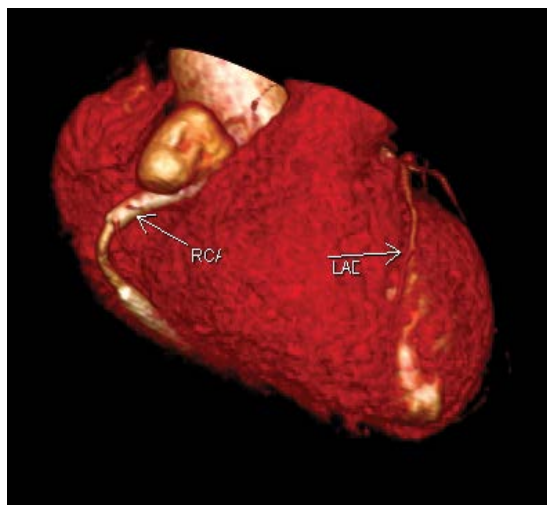
**Figure 5:** FDG PET CT study: Axial section shows mild to moderate uptake adjacent to root of aorta and proximal RCA pseudo aneurysm adjacent to stent.



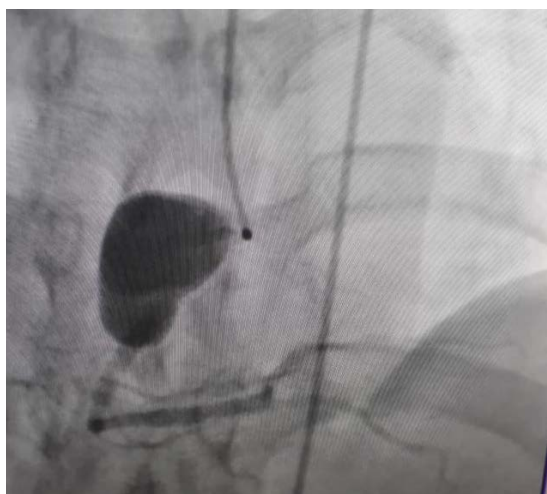**Figure 3:** CT coronary angiography-contrast study: Post contrast axial and sagittal section shows pseudo aneurysm arising from proximal RCA Adjacent to coronary stent.



**Figure 6:** FDG PET CT study: Axial section shows mild to moderate uptake adjacent to root of aorta and proximal RCA pseudo aneurysm adjacent to stent.



**Figure 7:** VRT image of coronary angiography showing pseudo aneurysm arising from proximal right RCA adjacent to stent.



**Figure 8:** Coronary angiography shows pseudo aneurysm arising from proximal RCA adjacent to stent.

*hominis*. Patient continued on IV antibiotics and discharged. Serial blood investigations showed improvement in WBC counts and CRP with no growth in repeat blood cultures.

## Discussion and Conclusion

Coronary stent infection is a very rare post percutaneous coronary intervention complication. Other complications include coronary abscess, pericarditis, mycotic aneurysms, and valvular endocarditis.

That is often fatal and associated with high morbidity and mortality. Coronary stent infection can present days to weeks after intervention. Exact mechanism of stent infections remains unclear. Possible mechanisms result of infection at the time of stent placement, Subsequent in stent balloon angioplasty, Hematogenous spread from another source of bacteremia.

Most common presentation within First four weeks after stent placement is fever and chest pain (In 50% of the affected individuals). Blood culture is uniformly positive. In the background of above enlisted findings Stent infection should be suspected and blood cultures should be withdrawn in all patients presenting with fever within the first weeks after coronary stent placement even in the absence of chest pain, ECG abnormalities or elevation of cardiac enzymes [4-7]. Risk factors-patient's age >60 years, Presence of congestive heart failure, multiple skin punctures, difficult vascular access, extended duration of the procedure, use of multiple PTCA-balloons, deferred removal of the arterial sheath, repeated catheterizations by the same vascular access site.

Preventive measures of this rare condition include:

- Removal of hair from the puncture site,
- Application of antiseptic to the skin,
- Use of sterile drapes, Appropriate hand washing,
- Prophylactic antibiotics in patients with immunodeficiency,
- Difficult procedures, prolonged indwelling catheter,
- Stenting of difficult to reach areas, known colonization of patient and
- Wearing a sterile gown and sterile gloves and a generally sterile environment should be maintained during the procedure.

Intravenous antibiotics are the mainstay of treatment. It may need removal of infected stent by surgery and drainage of pus. Despite of antibiotics and surgery, mortality rate in these patients is around 40%.

## References

1. Schierholz JM, Beuth J (2001) Implant infections: A haven for opportunistic bacteria. J Hosp Infect 49: 87-93.
2. Sigwart U, Puel J, Mirkovitch V, Joffre F, Kappenberger L (1987) Intravascular stents to prevent occlusion and restenosis after transluminal angioplasty. N Engl J Med 316: 701-706.
3. Marso SP, Ellis SG, Raymond R (1999) Intracoronary stenting: An overview for the clinician. Clev Clin J Med 66: 434-442.
4. Haase KK, Baumbach A, Karsch KR (1998) Stents are used too often. Heurf 79: 541-542.
5. Dieter RS (1998) Vascular adhesion molecules. Contemp Surg 52: 374.
6. Leroy O, Martin E, Prat A, Decoulx E, Georges H, et al. (1996) Fatal infection of coronary artery stent implantation. Cuthet Cardiovasc Diagn 39: 168-170.
7. McCready RA, Siderys H, Pittman JN, Herod GT, Halbrook HG, et al. (1991) Septic complications after cardiac catheterization and percutaneous transluminal coronary angioplasty. J Vasc Surg 14: 170-174.