

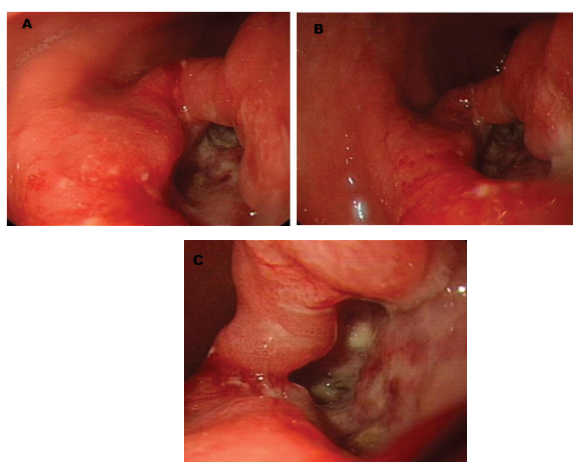
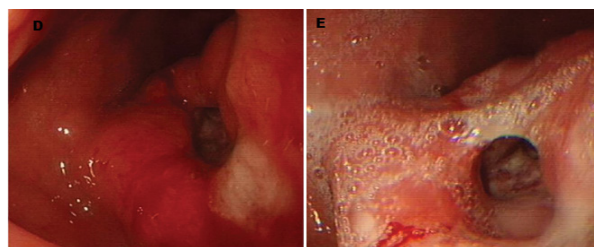
Deep Gastric Ulcer with Formation of Fistula along the Stomach Wall

Abu Taiub Mohammed Mohiuddin Chowdhury*, Du Jing Feng, Liu Min and Cuiying

Department Of Digestive Disease-II, The First Affiliated Hospital of Jiamusi University, Heilongjiang, P.R. China

Case Summary

A deep Gastric ulcer with formation of fistula buried in the posterior stomach wall, at the lower half of the body of the stomach along the lesser curvature in a 65 years old male patient was evaluated while undergoing “Esophagogastroduodenoscopy” for clinical features resembled to simple mild gastritis not responding to Proton Pump Inhibitor therapy. The channel was about 3 cm long, buried in to the posterior wall of the stomach close to the lesser curvature with superior wide and sliding opening of about 1.8 cm and a lower comparatively constricted opening of 0.8 cm, approximately 4.5 cm above the pyloric sphincter. The patient was overweight, hypertensive, non-diabetic, non-smoker with irregular alcohol consumption and no regular history of NSAID. His C13 Urea breath test was found negative and histopathological examination of biopsy specimens confirmed diagnosis of Carcinoma.



*Corresponding author: Abu Taiub Mohammed Mohiuddin Chowdhury, Department of Digestive Disease II, The first Affiliated Hospital of Jiamusi University, Heilongjiang, P.R. China, E-mail: dr_mohiuddinchy@yahoo.com

Received October 19, 2014; Accepted October 27, 2015; Published November 08, 2015

Citation: Chowdhury ATMM, Feng DJ, Min L, Cuiying (2015) Deep Gastric Ulcer with Formation of Fistula along the Stomach Wall. J Hepatol Gastroint Dis 1: i102. doi: 10.4172/2475-3181.1000i102

Copyright: © 2015 Chowdhury ATMM, et al. This is an open-access article distributed under the terms of the Creative Commons Attribution License, which permits unrestricted use, distribution, and reproduction in any medium, provided the original author and source are credited.