

## Delayed Haematuria after Percutaneous Nephrolithotripsy and its Management

Naresh Kumar Valecha<sup>1\*</sup>, Fariborz Bagheri<sup>2</sup>, Salam Al Hassani<sup>3</sup>, Abdulmunem Al Sadi<sup>4</sup>, Rafe souliman<sup>5</sup>

<sup>1</sup>Specialist Urologist, Dubai hospital, Albaraha, Opposite Abuhail post office, Dubai

<sup>2</sup>Consultant and head of department urology, Dubai hospital, Dubai

<sup>3</sup>Consultant department of urology, Dubai hospital, Dubai

<sup>4</sup>Senior specialist urology, Dubai hospital, Dubai

<sup>5</sup>Specialist urology, Dubai hospital, Dubai

\*Corresponding author: Naresh Kumar Valecha, Specialist Urologist, Dubai hospital, Albaraha, Opposite Abuhail post office, Dubai, Tel: 923332081001; E-mail: drnaresh\_valecha@yahoo.co.in

Received date: July 01, 2017; Accepted date: August 21, 2017; Published date: August 29, 2017

Copyright: © 2017 Valecha NK, et al. This is an open-access article distributed under the terms of the creative commons attribution license, which permits unrestricted use, distribution, and reproduction in any medium, provided the original author and source are credited.

### Abstract

**Objective:** To evaluate the risk factors and management of patients developed delayed haematuria after Percutaneous nephrolithotripsy (PCNL).

**Methods:** Data taken from 75 patients, who underwent PCNL procedures between January 2013 to June 2017. Among them 53 were male, 22 were female. Five patients presented with delayed haematuria. They were hospitalized and initially managed conservatively by bed rest and conservative treatment. Diagnostic imaging with ultrasound and non-contrast abdominal CT and serial follow up with blood tests were carried on. Angiography was performed, if indicated, to evaluate and treat possible vascular injury. All affected patients had risk factors for haematuria. Out of five, four patient had angiography, in two patients it confirm vascular injury and treated accordingly, while two were normal and one refuse for angiography.

**Conclusion:** Delayed hematuria is one of rare and serious outcome of PCNL, but can be safely managed without serious consequences. Mostly it is secondary to vascular complication e.g., pseudo aneurysms. Presence of risk factors increases chance of haematuria. Conservative treatment is effective. In responders angiography; and embolization can be done, whenever indicated.

**Keywords:** Delayed haematuria; Percutaneous nephrolithotripsy; Pseudo aneurysm; vascular injury

### Introduction

As the appraisal of open stone surgery began to reach its peak, advancement continued in the development of less invasive techniques for accessing renal stones. While the first PCN was performed by Thomas Hillier in 1865, Willard Goodwin in 1955 published his work on PCN for hydronephrosis, that it gained acceptance. More than 20 years later [1-3] this example led to the recognition that the same access could also be used as a working channel, resulting in the percutaneous removal of a kidney stone. Over the past 30 years, PCNL has largely replaced open renal surgery for the management of large kidney stone [4].

It has since evolved and been refined with the development of purposely designed instruments, endoscopes and accessories, and has remained a standard treatment for different varieties of renal stones since the eighties [5]. Compared to open renal surgery, PCNL is associated with shorter hospital stays and allows the patient an earlier return to work and activities of daily living. Furthermore, as PCNL is both less invasive and less expensive to perform than open procedures, it has become the treatment method of choice for large renal calculi [6]. Acute hemorrhage is the most common significant complication of percutaneous access into the upper urinary tract collecting system.

PCN alone results in haemorrhage requiring transfusion in 0.5% to 4% of procedures [7-9] With the addition of percutaneous nephrolithotripsy, likely owing to the larger caliber of the percutaneous tract and increased intrarenal manipulation, the incidence of hemorrhage to the point of transfusion rises to 6% to 20% [10-14].

Postoperative haemorrhage can occur with the nephrostomy tube in place, at time of tube removal, or after discharge from the hospital. About 1% of patients having percutaneous renal surgery are complicated by delayed haemorrhage requiring treatment [15-17] Delayed haemorrhage is usually due to vascular complication, e.g.: arteriovenous fistulas or arterial pseudo aneurysms, with the latter being more common. Arterial pseudoaneurysm arises from a transected or punctured artery that leaks in to a contained Hematoma cavity.

This complication is likely to happen because of an artery transected partially or end on during percutaneous nephrolithotomy puncture, which could subsequently bleed in to contained space. This transected arterial branch may be either partially thrombosed or in spasm initially, leading to its non-recognition in the operating room, as the patient increases his /her activity, the occluding clot may possible get dislodged, accounting for the delayed occurrence of haematuria [18].

## Methods

Data from 75 patients, who underwent PCNL procedures between January 2013 to June 2017 and developed delayed hematuria, were retrospectively reviewed and included in our study. Selection criteria for PCNL was stone size  $\geq 2$  cm in adult patients. Children, patients with active infection and bleeding disorders were not included in study.

Preoperative patient evaluation included history, clinical examination, serum creatinine level, complete blood count, coagulation profile. All patients who have urinary tract infections were treated according to their culture sensitivity. Patients who were taking aspirin or other anticoagulants were stopped a week before.

All patients were evaluated with contrast enhanced computed tomography (CT) before the procedure. All procedures were performed in prone position after insertion of ureteric catheter. Percutaneous renal access was established under C-arm fluoroscopic guidance through the poster lateral plane of the kidney by Urologist.

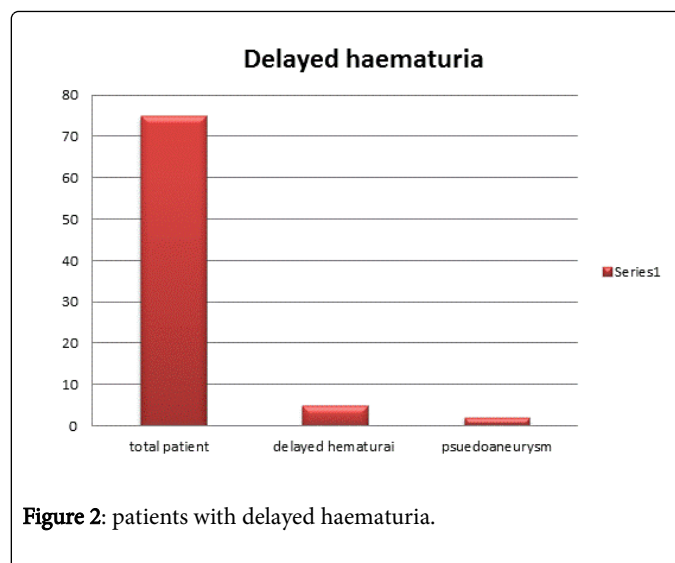
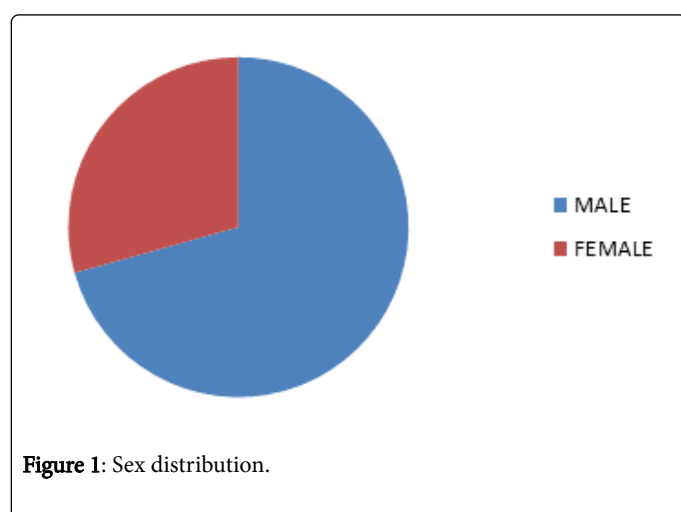
Dilatation of tract was performed by serial Aalken dilators technique. Stones were removed following fragmentation with an ultrasonic lithotripter and a nephrostomy tube was placed at the end of the procedure. After 48 hours antegrade pyelography was done and nephrostomy tube removed after confirming patency and absence of significant residual stone.

The patients were discharged next day of nephrostomy removal, if there were no complications.

Overall, a total of five patients presented and were admitted in our department with delayed intermittent haematuria following PCNL procedures. Initially, patients were managed conservatively by bed rest, bladder clots removal and irrigation, IV Fluid, antibiotics with diagnostic imaging ultrasound and non-contrast abdomen CT and serial follow up with blood tests.

Angiography was performed in selected cases to evaluate and treat possible AV malformation. All patients characteristics, including age, sex, stone size, operation time, number of renal accesses, access site (subcostal or supracostal), calyx punctures, and number of blood transfusions were recorded.

See Table 1 for patient demographic (Figures 1 and 2).



## Results

Among all, 53 were male and 22 were female. Five patients (6.6%), out of 75 patients, had delayed haematuria, and only in two patients (2.66%) vascular injury was confirmed. All five patients were male and one patient had malrotated kidney. All patients, who developed this complication, had comorbidities. Mean age of patient was 47.8 years. Average stone size in longest diameter was 2.95(2-5 cm). Out of five patients; four were known hypertensive, controlled by medicines.

Average time for onset of hematuria was 13.2 days.

Four patients, those who have angiography, in two patients it was unremarkable and in one patient it showed pseudo aneurysm, therefore super selective angio embolization was done. He did well initially, hematuria was settled but after two days, gradually it started again. It leads to clots formation in renal pelvis followed by renal impairment. His other kidney was also relatively small, therefore we did ureteroscopic clots removal and stenting, but unfortunately he developed big renal hematoma and severe sepsis that necessitated nephrectomy as life saving measure. Another patient, angiography confirm vascular injury and leak, it was treated by balloon angioplasty.

Another patient that has extensive urolithiasis with CKD and Hypertension and solitary functioning kidney. His angiography was normal. We did for him cystoscopy and stenting earlier on admission due to renal impairment. During course of conservative management he develops sepsis. We replace stent and continue supportive treatment, including hemodialysis, so he recovered well and discharged. One patient who present on 5th post op day, he also bleed during primary surgery for PCNL, so procedure was abandoned. Bleeding was controlled by nephrostomy insertion. He didn't require transfusion either during or in peri- operative period. His angiography was also normal. He had Hypertension, hyperuricemia and .treated for lymphoma about 10yrs before. One patient was admitted for delayed hematuria on 8th post op day, He had Diabetes Mellitus, Hypertension, HBsAG +VE, Glaucoma, and refuse for angiography. He was managed with conservative treatment. Only two patients whose angiography was positive needs blood transfusion, rest were treated conservatively without significant drop in hemoglobin.

## Discussion

In era of endourology and minimally invasive surgery PCNL is standard treatment of large renal stones, as it is safe and efficient. However minor to major complications can occurs during and after surgery [19-22].

Bleeding is one of most common complications. Fortunately majority of these are minor and self-limiting and managed conservatively but some time it necessitate the intervention. Haemorrhage related to PCNL has reported incidence varies from 0.8% to 7.6% [23-26]. In our study we observe delayed haematuria in five patients that is about 6.6% and only two patients prove vascular injury that is only 2.66%.

As kidney has got very high blood flow, 25% of cardiac output. Some bleeding is natural with the procedure. While it requires transfusion in 3% to 25% of cases PCNL [27-29]. Venous bleeding can usually be controlled with nephrostomy insertion, while severe arterial bleeding requires angiography and selective angioembolization. Reported incidence is 0.3-1.4% [30,31] that is slight higher in our study, and result may vary in larger scale study with increased number of patients. Excessive bleeding usually arises from injury of segmental arteries, which are surrounded by dense renal parenchyma, thus easier to temponade with nephrostomy sheath or tube [32].

Patients number	Age (years)	Sex	Stone burden	Co-morbids	Access site and number	Urinary anomaly	Operation Time (minutes)	Occurrence of post op hematuria	Angiography	Management
1.	68 yrs	M	Right Staghorn 2.5 -2 cm	1.Hypertension 2.hyperuricemeia 3.treated for lymphoma 2006	Middle calyx	nil	95min/ procedure abandoned due to bleeding	5th post op day	Normal	Conservative
2.	31 yrs	M	Right Forgotten stent +staghorn stone 5 × 4 cm	1.Hypertensive 2.CKD 3.Bilateral renal stone, left small kidney	Lower pole	Nil	120 min	01 month Restart after a week	Normal	Initially conservative Cystoscopy +stenting due to sepsis and clots removal
3.	43	M	Left renal stone 2.6 × 1.4 cm	DM,HTN HBsAg +VE Glaucoma	Middle calyx	Left mal rotated kidney +partial duplex system	100 min	08 days	Not done (patient refuse)	Conservatively
4	27	M	Right renal stone +forgoten stent +ureteric stones (multiple calculi)	Recurrent stone former, left kidney relatively small, CKD	Lower calyx	Nil	150 min	16 days	angiography reveal lower pole pseudo aneurysm so embolization performed	Cystoscopy+clots Evacuation and stenting due to elevated critinine. Blood transfusion.
5	70	M	Bilateral renal stone. 1.2 cm in right kidney 2.5 cm left kidney	Hypertensive,IH D	Middle calyx	Nil	160min	7 days	Angiography reveal vascular injury,treated by baloom angioplasty	Conservative / supportive with blood transfusion.

**Table 1:** Patients Demographic.

The Bleeding can occur during renal puncture, tract dilatation, and manipulation of nephroscope or in post-operative period [33]. Patients with arteriosclerosis of renal artery branches accelerated by aging, hypertension, or diabetes mellitus are presumably are at higher risk of bleeding. Arteriosclerosis may impair the ability of self-healing properties of arterial wall because of loss of normal muscle and elastic layers. Bleeding tendency is frequently noted in patients with uremia and liver cirrhosis and those under anti-coagulant agent treatment. Kidneys those have had retroperitoneal inflammation from renal infection and fixed in the retro peritoneum are specially at higher risks

of parenchymal trauma during percutaneous intrarenal surgery [34]. Published data suggests that patient age, ASA grade, stone burden and operation duration are associated with increased risk of vascular complications [35]. Kessarris .et al reported in his study of 2200 PCNL, that age, gender, medical illness, stone burden, number of renal punctures, and procedure duration were not risk factors [36]. In our study, all patients has some risk factors. In one patent hematuria couldn't settled with angioembolization, leads to severe sepsis and nephrectomy.

Nephrectomy related to PCNL is rare but reported in literature. Kernohan et al reported a case of complete embolization of renal artery which resulted in loss of kidney. Selective embolization was not successful due to abnormal arteries which made it impossible to embolize the feeding artery selectively [37] Stephen R, et al [38] reported nephrectomy due to cardiovascular instability secondary to haemorrhage [35]. Another study from Pakistan reported nephrectomy due to massive delayed bleeding after PCNL, due to unavailability of interventional radiology facilities [38].

Transfusion requirement influenced by many factors, including operative techniques, surgeons experience, stone complexity, and patient status. Lam et al reported that improved skills and the presence of flexible nephroscope decreased rate of blood transfusions.

In some studies it was reported that multiple parenchyma punctures were associated with vascular injuries and increased blood transfusions.

El-Nahas et al. [28] observed that stag horn stones and upper calyx punctures were significant risk factor for severe bleeding. All patients, who presented with delayed haematuria have complex stone disease along with co morbid risk factors. Mean operation time was 116.25 minutes, all patients were approached by lower calyx.

In our study we did angiography in 4 patients, two have normal angiography and one patient showed Pseudoaneurysm ,therefor embolization was done ,but that didn't works, and he start hematuria in 48hrs in same admission and end up with nephrectomy due sepsis and hemodynamic instability. El-Nahas et al. [28] reported that success rate of controlling the bleeding after PCNL was 92.3% and 72.3% of patients were successfully treated with single session without any complication. This study suggest that about 28% failure of angioembolization, this may be similar to our study ,where one patient re start bleeding that end up with lifesaving nephrectomy. This is similar to literature. Limitations of our study were low number of patients and retrospective study. Probably, a multicentric prospective study can result in a more precise outcome.

## Conclusions

Delayed haematuria is one of rare and serious outcome of PCNL, mostly It is secondary to vascular complication e.g., pseudo aneurysms. Presence of risk factors increases chances of haematuria. Conservative treatment is effective and still the treatment option. Angiography can be an option for non-responder with possible embolization if indicated.

## References

1. Wen CC, Nakada SY (2007) Treatment selection and outcomes: renal calculi. *Clin North Am* 34: 409-419.
2. Bloom DA, Morgan RJ, Scardino PL (1989) Thomas Hillier and percutaneous nephrostomy. *Urology* 33: 346-350.
3. Goodwin WE, Casey WC, Woolf W (1955) Percutaneous trocar (needle) nephrostomy in hydronephrosis. *J Am Med Assoc* 157: 891-894.
4. Deane LA, Clayman RV (2007) Advances in percutaneous nephrostolithotomy. *Urol Clin North Am* 34: 383-395.
5. Bill T (2009) Percutaneous Nephrolithotomy. *Medical Bulletin* 10:14-17.
6. Chao D, Abdulla AN, Kim S, Hoogenes J, Matsumoto ED (2014) A Novel Endoscopic Treatment for renal arteriopelvic fistula post-percutaneous nephrolithotomy (PCNL). *Int Braz J Urol* 40: 568-573.
7. Radecka E, Magnusson A (2004) Complications associated with percutaneous nephrostomies. A retrospective study. *Acta Radiol* 45: 184-188.
8. Wah TM, Weston MJ, Irving HC (2004) Percutaneous Nephrostomy Insertion: outcome data from prospective multi-operator study at a UK training center. *Clin Radiol* 59: 255-261.
9. ACR (2007) Practice guidelines for the performance of percutaneous nephrostomy in ACR practice guide lines and technical standards Reston(VA) American College Of Radiology 705-715.
10. Kukreja R, Desai M, Patel S, et al. (2004) Factors affecting blood loss during percutaneous lithotomy: prospective study . *J Endourol* 18: 715-722.
11. Netto NR Jr, Ikonomidis J, Ikari O, Claro JA (2005) Comparative study of percutaneous access for staghorn calculi. *Urology* 65: 659-662.
12. Preminger GM, Assimos DG, Lingeman JE, Nakada SY, Pearle MS, et al. (2005) AUA guideline on management of staghorn calculi: diagnosis and treatment recommendations. *J Urol* 173: 1991-2000.
13. Muslumanoglu AY, Tefekli A, Karadag MA, Tok A, Sari E, et al. (2006) Impact of percutaneous access point number and location on complication and success rates in percutaneous nephrolithotomy. *Urol Int* 77: 340-346.
14. Chew BH, Chiu RY, Hamidzadeh R, Wright I, Chan SH, et al. (2009) Success and complication rate in 729 percutaneous nephrolithotomies at single center. *J Urol* 181: 493-494.
15. Kessaris DN, Bellman GC, Pardalidis NP, Smith AG (1995) Management of hemorrhage after percutaneous renal surgery. *J Urol* 153: 604-608.
16. Martin X, Murat FJ, Feitosa LC, Rouvière O, et al. severe bleeding after nephrolithotomy: results of hyperselective embolization. *Eur Urol* 37:136-139.
17. Richstone L, Reggio E, Ost MC, Seideman C, Fossett LK, et al. (2008) Hemorrhage following percutaneous renal surgery: Characterization of angiographic findings. *J Endourol* 22:1129-1135.
18. Vijay MK, Vijay P, Das RK, Kundu AK (2011) Renal artery pseudoaneurysm following percutaneous nephrolithotomy. *Saudi J Kidney Dis Transpl* 22: 347-348.
19. Jinga VB, Youssef S, Radavoi GD, Braticевичi B, Filipoiu M (2013) Balgradean. Transarterial Embolization of Renal Vascular Lesions after Percutaneous Nephrolithotomy. *Chirurgia* 108: 521-529.
20. Ritter M, Krombach P, Michel M (2011) Percutaneous Stone Removal. *Eur Urol* 10: 433-439.
21. Geavlete P, Mulaescu R, Geavlete B (2012) Endoscopic surgery for urolithiasis: what does "stone free" mean in 2012. *Chirurgia (Bucur)* 107: 693-696.
22. Geavlete P, Mulaescu R, Jecu M, Georgescu D, Geavlete BP (2009) Percutaneous approach in the treatment of matrix lithiasis. Experience of the urological department of "Saint John" Emergency Clinical Hospital. *Chirurgia (Bucur)* 104: 447-451.
23. Skolarikos A, Alivizatos G, de la Rosette JJ (2005) Percutaneous nephrolithotomy and its legacy. *Eur Urol* 47: 22-28.
24. Kim SC, Kuo RL, Lingeman JE (2003) Percutaneous nephrolithotomy: an update. *urr Opin Urol* 13: 235-241.
25. Srivastava A, Singh KJ, Suri A, Dubey D, Kumar A, et al. (2005) Vascular complications after percutaneous nephrolithotomy: are there any predictive factors? *Urology* 66: 38-40.
26. El-Nahas AR, Shokeir AA, El-Assmy AM, Mohsen T, Shoma AM, et al. (2007) Post-percutaneous nephrolithotomy extensive hemorrhage: a study of risk factors. *J Urol* 177: 576-579.
27. Srivastava A, Singh KJ, Suri A, Dubey D, Kumar A, et al. (2005) Vascular complications after percutaneous nephrolithotomy: are there any predictive factors? *Urology* 66: 38-40.
28. El-Nahas AR, Shokeir AA, Mohsen T, Gad H, El-Assmy AM, et al. (2008) Functional and morphological effects of post percutaneous nephrolithotomy super selective renal angiographic embolization. *Urology* 71: 408-412.

29. Poulakis V, Ferakis N, Becht E, Deliveliotis C, Duex M (2006) Treatment of renal-vascular injury by transcatheter embolization: immediate and long-term effects on renal function. *J Endourol* 20: 405-409.
30. Sacha K, Szewczyk W, Bar K (1996) Massive haemorrhage presenting as a complication after percutaneous nephrolithotomy (PCNL). *Int Urol Nephrol* 28: 315-318.
31. Kessaris DN, Bellman GC, Pardalidis NP, Smith AG (1995) Management of hemorrhage after percutaneous renal surgery. *J Urol* 153: 604-608.
32. Cope C, Zeit RM (1982) Pseudoaneurysms after nephrostomy. *AJR Am J Roentgenol* 139: 255-261.
33. Wen-Hong Huang, et al. (2003) Risk Factors of Massive Bleeding After Percutaneous Nephrolithotomy and its Management. *JTUA* 14: 65-70.
34. Keoghane SR, Cetti RJ, Rogers AN, Walmsley BH, (2012) Blood transfusion, embolization and nephrectomy after percutaneous nephrolithotomy (PCNL). *BJU International* 111: 628-632.
35. Kessaris DN, Bellman GC, Pardalidis NP, Smith AG (1995) Management of hemorrhage after percutaneous renal surgery. *J Urol* 153: 604-608.
36. Kernohan RM, Johnston LC, Donaldson RA (1990) Bleeding following percutaneous nephrolithotomy resulting in loss of the kidney. *Br J Urol* 65: 657-658.
37. Shahzad Ali, Naresh Kumar and Umer Baloch (2014) Outcome of Percutaneous Nephrolithotomy. *Journal of the College of Physicians and Surgeons Pakistan* 24: 261-264.
38. Patterson DE, Segura JW, Leroy AJ, Benson RC, May G, et al. (1985) The etiology and treatment of delayed bleeding following percutaneous lithotripsy. *J Urol* 133: 447-451.