

Diagnosis and Treatment of Paragangliomas of the Filum Terminale, an Extremely Rare Entity: Personal Experience and Literature Review

Landi A^{1*}, Mancarella C¹, Marotta N¹, Tarantino R¹, Lenzi J¹, Anichini G¹, Santoro A² and Delfini R¹

¹Department of Neurology and Psychiatry, Division of Neurosurgery "A", University of Rome "Sapienza", Italy

²Department of Neurology and Psychiatry, Division of Neurosurgery "B", University of Rome "Sapienza", Italy

Abstract

Background: Paragangliomas of the filum terminale are very rare tumors. Those are benign lesions and do not produce catecholamines, show male predominance and rarely metastasize. Total surgical resection is usually curative. We reviewed available literature in this respect and show our experience.

Methods: Studies on paragangliomas of the filum terminale reported in the English literature were analyzed to date. The references of each article were analyzed and classified according to the following criteria: age, sex, first symptoms, treatment, and outcome.

Results: Paragangliomas of the filum terminale are rare benign tumors. To the best of our knowledge, in the English-language literature, only 36 previous cases of paraganglioma of the filum terminale have been reported to date. Reports of familiar occurrence and association with leiomyosarcomas, chordomas or pituitary adenomas suggest a genetic basis for the tumor. As we can see in the literature the reported mean age at presentation is 49.8 years. The most common presenting symptoms are low back pain associated occasionally with sciatic pain.

Conclusion: The aim of surgery is total resection that is usually curative. In cases of incomplete removal long-term follow-up is essential.

Keywords: Paraganglioma; Filum terminale; Surgery; RXT

Introduction

Paragangliomas are tumors arising from neuroepithelial cell groups called paraganglia, first reported by Alfred Kohn in 1903 [1]. They are benign tumors. The paraganglia are subdivided into two groups: one formed by the adrenal medulla and the other by the extraadrenal paraganglia. From the first one arises, the typical pheocromocytoma. The most common site for extra-adrenal paragangliomas is the carotid body. These tumours may also occur in the spinal canal – usually arising in the cauda equina and very rarely in the filum terminale. Low back pain is the main presenting symptom with often sciatica as well. Magnetic resonance imaging is the sturdy of choice and treatment consists of total excision when it can be possible. Definitive diagnosis can only be made after histological and immunohistochemical investigation. We report the literature review and our experience about paragangliomas of the filum terminale, paying attention on the diagnosis and the principle of treatment.

Materials and Methods

The authors analyzed studies on paragangliomas of the filum terminale reported in the English literature using database as pubmed and utilizing the following keywords: paraganglioma, filum terminale, cauda equina. The references of each article were analyzed and classified according to the age, sex, first symptom, treatment, and outcome.

Moreover, the authors describe 3 patients treated in our institution: the first case, published in December 2009 by Landi et al. [2] of a 49-year-old man with a three months history of increasing weakness of his left leg, increasing low back pain and a radiating pain in left leg, aggravated by movements, cough and abdominal torch manoeuvres. The second case was a 64-year-old woman with a month history of low back pain and a radiating pain in right limb. The third case was a 29 year-old man complaining a 3 months history of low back pain (Figure 1) (Table 2).

Results

All the patients we studied were treated with a standard

laminectomy and total en bloc excision of the intradural lesion of the filum terminale through a standard durotomy. The lesions appeared elastic, vascular, well-encapsulated and attached to the filum terminale but not to other structures (Figure 2). None of these patients underwent postoperative radiotherapy thanking to the en block removal of the lesion. The patients had rapid and good recovery. And no recurrence was seen after total resection in these 3 patients (Figure 3).

Global literature review showed that paraganglioma of the spine most commonly occur in the region of the cauda equina. Paragangliomas of the filum terminale are rarer [2-12]. To the best of our knowledge, in the English-language literature, only 36 previous cases of paraganglioma of the filum terminale have been reported to date as we summarize in the table 1. As we observed in the literature, we can say that:

- The biological behaviour of these lesions is most commonly benign.
- Reports of familiar occurrence and association with leiomyosarcomas, chordomas or pituitary adenomas suggest a genetic basis for the tumor.
- The reported mean age at presentation is 49.8 years.

***Corresponding author:** Dr. Alessandro Landi, Department of Neurology and Psychiatry, Division of Neurosurgery "A", University of Rome Viale del Policlinico 15500181, Rome, Italy, Tel: +39-329-0641772; Fax: +39-06-49979113; E-mail: dott.alessandro.landi@gmail.com

Received February 01, 2013; **Accepted** March 18, 2013; **Published** March 20, 2013

Citation: Landi A, Mancarella C, Marotta N, Tarantino R, Lenzi J, et al. (2013) Diagnosis and Treatment of Paragangliomas of the Filum Terminale, an Extremely Rare Entity: Personal Experience and Literature Review. J Spine S3: 001. doi:10.4172/2165-7939.S3-001

Copyright: © 2013 Landi A, et al. This is an open-access article distributed under the terms of the Creative Commons Attribution License, which permits unrestricted use, distribution, and reproduction in any medium, provided the original author and source are credited.

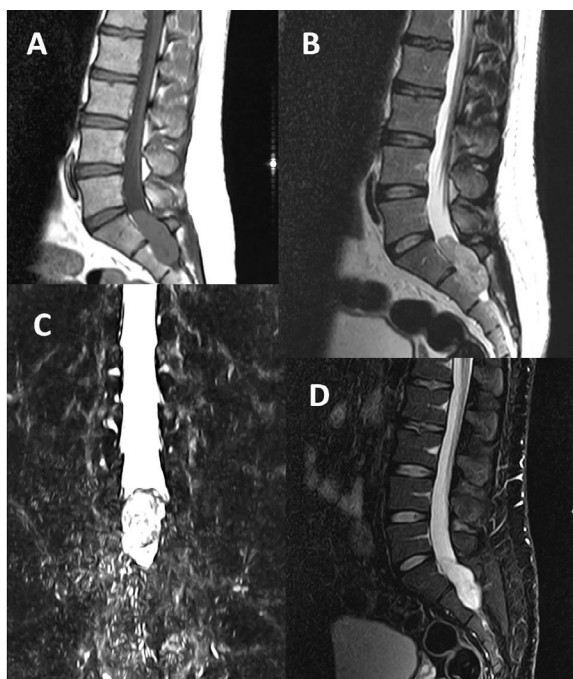


Figure 1: Preoperative MRI.

- A) Sagittal T1 weighted image showing intradural isointense lesion.
B) Sagittal T2 weighted image showing hypointense lesions.
C) Myelo-3D showing serpiginous flow voids.
D) STIR sequences.

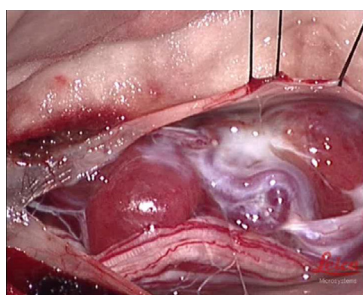


Figure 2: Intraoperative picture of the lesion, after durotomy. The lesions appear red-black in color, vascular, well-encapsulated and attached to the filum terminale but not to other structures.

- The most common presenting symptoms are low back pain in 50-87% [12] of the cases associated occasionally with radicular pain (20-50% of the cases). Urinary or fecal incontinence is rare; sensory or motor deficits are less common; symptoms secondary to hormonal manifestations are uncommon. The duration of symptoms may vary from one day to 17 years (range 1-204 days).

Discussion

Paragangliomas arise approximately for the 85-90% of cases in the adrenal gland. Extra-adrenal paragangliomas are rare neuroendocrine tumours, which can occur throughout the body.

Within the central nervous system reported locations include the pineal region, petrous ridge, sella turcica and spinal canal [13]. Most

reported spinal paraganglioma are intradural tumours involving the cauda equina approximately 3 to 4%, although lesions involving the thoracic cord have been reported; paragangliomas of the filum terminale are very rare. The first case was described in the 1972 by Lerman et al. [9], although Miller and Torack's 1970 report of a "secretory ependymoma of the filum terminale" proved in retrospect to be the first case described [14]. These tumors remain a rare entity with more than 200 cases described to date, located in the cauda equina, and only 36 cases in the filum terminale. Extra-spinal paragangliomas may be multiple with a higher incidence when there is a family history (association with Von Hippel Lindau disease and MEN II). The most frequent extra-spinal locations include the petrous ridge, pineal gland and sella turcica [13,15-17]. Spinal paragangliomas are uncommon, and their incidence has been estimated to be 0.07 per 100.000 of the population. Although tumors of the carotid body and glomus region are usually of the parasympathetic type, spinal tumors are typically sympathetic.

Although paraganglioma of the cauda equina is well documented, paraganglioma of the filum terminale is very rare. The biological behaviour of these lesions is most commonly benign. Reports of familial occurrence and association with leiomyosarcomas, chordomas or pituitary adenomas suggest a genetic basis for the tumor [18]. As we can see in the table 1 a wide range of age at presentation of between 22-71 years with a mean age of 49.8 years has been reported with a slight male predominance. The initial symptom is low back pain or/and sciatica; urinary or fecal incontinence is rare; sensory or motor deficits are less common; symptoms secondary to hormonal manifestations are uncommon [19,20].

Although MRI can identify the intradural extramedullary lesions, it is not diagnostic and the differential diagnosis includes schwannoma, ependymoma, meningioma or solitary metastasis [21,22]. However, some findings are helpful in diagnosing a paraganglioma. Spinal paragangliomas include low/intermediate signal intensity on T1-weighted sequences and intermediate/high signal intensity on T2-weighted sequences in comparison with neighbouring paravertebral tissues (Figures 1a,1b and 1d). After Gd injection, there is marked enhancement; in some cases a "serpiginous flow voids" is observed, which suggests vessels capping the tumor. Araki et al. [3] suggested that this sign is a major clue to the diagnosis of a highly vascular lesion. Hypointense tumor margins on T2-weighted MR and proton-

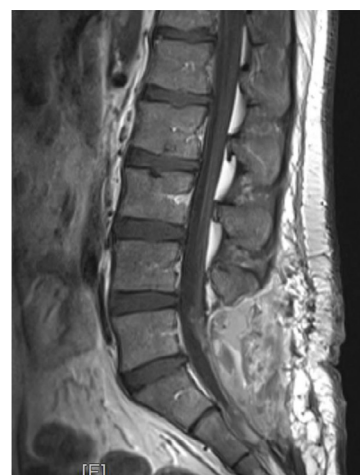

Figure 3: Postoperative MRI showing complete removal of the lesion.

Authors	Age and Sex	Symptoms	Duration	Treatment	Recurrence
Ilgren et al. [31]	58 F	LBP + sciatica	17 yrs	GTR	No
Sonneland et al. [23]	32 M	LBP	7 mos	GTR	No
	62 M	LBP + sciatica	6 wks	GTR	No
	52 M	LBP	3 yrs	STR + RXT	Recurrence after 9 yrs
	57 M	LBP + sciatica	7 yrs	STR	No
	67 F	LBP + sciatica	1 yrs	GTR	No
	49 M	LBP + sciatica	6 yrs	GTR + RXT	No
	61 M	LBP + sciatica	14 mos	GTR	No
	47 F	LBP + sciatica	1 yrs	STR + RXT	Recurrence after 1 yr
	30 M	LBP + sciatica	3 wks	GTR	No
	71 F	LBP + sciatica	7 yrs	GTR	No
	56 M	Paraparesys	1 yrs	GTR	No
	52 F	LBP + sciatica	3 mos	GTR + RXT	No
	53 M	LBP + sciatica	2 yrs	GTR + RXT	No
	48 F	LBP + sciatica	3 yrs	GTR	No
	36 M	LBP	NS	GTR	No
	39 M	LBP	15 yrs	GTR	No
	48 M	LBP + sciatica	1,5 yrs	GTR	No
	40 F	LBP + sciatica	2 yrs	GTR	No
	50 F	LBP + sciatica	15 yrs	GTR	No
	59 M	LBP + sciatica	2 yrs	GTR	No
	58 F	LBP + sciatica	7 mos	GTR	No
	66 F	LBP + sciatica	many yrs	GTR	No
	62 F	LBP + sciatica	many mos	GTR	No
	39 F	LBP + sciatica	10 yrs	GTR + RXT	No
	30 F	LBP + sciatica	4,5 yrs	GTR	No
	69 F	Claudicatio	1 yrs	GTR	No
Russel et al. [32]	61 F	LBP	many yrs	GTR	No
	56 F	progressive paraplegia	10 days	GTR	No
Moran et al. [27]	22 F	LBP	NS	GTR	No
	44 M	LBP	NS	GTR	No
Sousa et al. [24]	51 M	LBP + sciatica	3 yrs	GTR	No
Landi et al. [2]	49 M	sciatica + weakness at lower left limb	3 mos	GTR	No
Shankar et al. [25]	47 M	LBP	8 weeks	GTR	No
Rhee et al. [26]	70 M	gait disturbance	6 months	GTR	No
Gutenberg et al. [7]	52 M	LBP	many years	GTR	No

LBP: Low Back Pain; GTR: Gross Total. Resection; RXT: Radiotherapy

Table 1: Review of the literature from 2007 to 2011.

density imaging may indicate hemosiderin or ferritin from previous haemorrhages [3]. Important is Myelo-3D that frequently reveal partial or complete blocking caused by the intradural mass and serpiginous defects can be found around the mass, suggestive of dilated vessels these finding allow the differential diagnosis with schwannomas, ependymomas and meningioma. Notwithstanding the diagnosis is histological (Figure 1c).

Paragangliomas are intradural extramedullary lesions, well encapsulated, red-black in color, very soft or friable, and bled easily (Figure 2). Histopathologically, these tumours are composed of typical organoid or “Zellballen” pattern, arrangement of argyrophilic and polyhedral cells circumscribed by vascular stroma, arranged around small vessels reminiscent of pseudorosettes, immunohistochemical positivity for chromogranine and sustentacular cell immunoreaction for S100 proteins [2,11]. Areas of haemorrhage and necrosis may be seen. Most of these tumours have low proliferative potential. The objective of surgery is complete removal of the lesion. These lesions present a good prognosis, directly dependent on their complete removal: local recurrence is not uncommon particularly after subtotal excision and distant metastatic spread has also been described [23-27].

Prognosis is dependent on the ability to achieve complete removal of the lesion. Encapsulated lesions therefore have good prognosis. If complete resection is not possible or the tumour is not encapsulated, local recurrence can occur and postoperative radiotherapy is recommended, although radio resistance has been reported [28]. Cases of recurrence have been reported in the literature [29]. Rare is the malignant potential of these lesions. The great majority of metastasizing tumors has evidence of distant spread at diagnosis. Fifty percent are located at the cervical lymph nodes, and the others are evenly distributed among bone, lung and liver. The absolute risk of malignancy is difficult to define given that metastases can occur even up to 20 years after primary tumor diagnosis, so many studies do not have the length of follow up required to capture the true risk of malignancy [30].

Nowadays, chemotherapy does not appear to play a role in the management of paragangliomas of the filum terminale and cauda equina. The median time interval from operation to local recurrence has been estimated as 6 years, although isolated cases of recurrence have been described as late as 20 years after surgery [20]. Scrupulous long-term follow-up is essentials in cases of incomplete removal [31,32].

Age and sex	Symptoms	Duration	Treatment	Recurrence
49/M	LBP + Sciatica	3 months	GRT	No
64/W	LBP + Sciatica	1 month	GRT	No
29/M	LBP	3 months	GRT	no

LBP: Low Back Pain; GTR: Gross Total Resection

Table 2: Cases series: Our experience of 3 patient affected by paraganglioma of the filum terminale.

Conclusions

Paragangliomas of the filum terminale are very rare tumors. Primary symptoms are low back pain and radicular pain, sometimes accompanied by weakness. Important is the differential diagnosis with the degenerative spine disorders and oncological pathologies of frequent observation. Paragangliomas of the filum terminale most often follow a benign course if complete resection is achieved. The median time for local recurrence has been estimated as 6 years. The origin of paragangliomas of the CNS and especially of the filum terminale is still unclear. They do not produce catecholamines, show male predominance and rarely metastasize. The aim of surgery is total resection that is usually curative. Radiotherapy is only indicated for incompletely resected tumors and prolonged postoperative observation is mandatory because of the slow evolution of these tumors.

References

- Kohn A (1903) Die paraganglien. Arch Mikrobiol 62: 263-265.
- Landi A, Tarantino R, Marotta N, Rocco P, Antonelli M, et al. (2009) Paraganglioma of the filum terminale: case report. World J Surg Oncol 7: 95.
- Araki Y, Ishida T, Ootani M, Yamamoto H, Yamamoto T, et al. (1993) MRI of paraganglioma of the cauda equina. Neuroradiology 35: 232-233.
- Ashkenazi E, Onesti ST, Kader A, Llena JF (1998) Paraganglioma of the filum terminale: case report and literature review. J Spinal Disord 11: 540-542.
- Gelabert-González M (2005) Paragangliomas of the lumbar region. Report of two cases and review of the literature. J Neurosurg Spine 2: 354-365.
- Hsieh CT, Tsai WC, Tang CT, Liu MY (2009) Paraganglioma of the cauda equina. Neurol India 57: 833-834.
- Gutenberg A, Wegner C, Pilgram-Pastor SM, Gunawan B, Rohde V, et al. (2010) Paraganglioma of the filum terminale: review and report of the first case analyzed by CGH. Clin Neuropathol 29: 227-232.
- Levy RA (1993) Paraganglioma of the filum terminale: MR findings. AJR Am J Roentgenol 160: 851-852.
- Lerman RI, Kaplan ES, Daman L (1972) Ganglioneuroma-paraganglioma of the intradural filum terminale. Case report. J Neurosurg 36: 652-658.
- Yang SY, Jin YJ, Park SH, Jahng TA, Kim HJ, et al. (2005) Paragangliomas in the cauda equine region: clinicopathological findings in four cases. J Neurooncol 72: 49-55.
- Singh RV, Yeh JS, Broome JC (1993) Paraganglioma of the cauda equina: a case report and review of the literature. Clin Neurol Neurosurg 95: 109-113.
- Aghakhani N, George B, Parker F (1999) Paraganglioma of the cauda equina region--report of two cases and review of the literature. Acta Neurochir (Wien) 141: 81-87.
- Bilbao JM, Horvath E, Kovacs K, Singer W, Hudson AR (1978) Intracellular paraganglioma associated with hypopituitarism. Arch Pathol Lab Med 102: 95-98.
- Miller CA, Torack RM (1970) Secretory ependymoma of the filum terminale. Acta Neuropathol 15: 240-250.
- Kruse F Jr (1960) Petrous ridge chemodectoma (nonchromaffin paraganglioma) simulating meningioma. Case report. J Neurosurg 17: 1108-1111.
- Smith WT, Hughes B, Ermocilla R (1966) Chemodectoma of the pineal region, with observations on the pineal body and chemoreceptor tissue. J Pathol Bacteriol 92: 69-76.
- Warrier S, Owler BK, Besser M (2006) Paraganglioma and paragangliomatosis of the cauda equina. ANZ J Surg 76: 1033-1037.
- Carney JA, Sheps SG, Go VL, Gordon H (1977) The triad of gastric leiomyosarcoma, functioning extra-adrenal paraganglioma and pulmonary chondroma. N Engl J Med 296: 1517-1518.
- Boncoeur-Martel MP, Lesort A, Moreau JJ, Labrousse F, Roche I, et al. (1996) MRI of paraganglioma of the filum terminale. J Comput Assist Tomogr 20: 162-165.
- Say CC, Hori J, Spratt J Jr (1973) Chemodectoma with distant metastasis: case report and review of the literature. Am Surg 39: 333-341.
- Brodkey JA, Brodkey JS, Watridge CB (1995) Metastatic paraganglioma causing spinal cord compression. Spine (Phila Pa 1976) 20: 367-372.
- Wester DJ, Falcone S, Green BA, Camp A, Quencer RM (1993) Paraganglioma of the filum: MR appearance. J Comput Assist Tomogr 17: 967-969.
- Sonneland PR, Scheithauer BW, LeChago J, Crawford BG, Onofrio BM (1986) Paraganglioma of the cauda equina region. Clinicopathologic study of 31 cases with special reference to immunocytology and ultrastructure. Cancer 58: 1720-1735.
- Sousa J, O'Brien D, Crooks D (2005) Paraganglioma of the filum terminale. J Clin Neurosci 12: 584-585.
- Shankar GM, Chen L, Kim AH, Ross GL, Folkerth RD, et al. (2010) Composite ganglioneuroma-paraganglioma of the filum terminale. J Neurosurg Spine 12: 709-713.
- Rhee HY, Jo DJ, Lee JH, Kim SH (2010) Paraganglioma of the filum terminale presenting with normal pressure hydrocephalus. Clin Neurol Neurosurg 112: 578-581.
- Moran CA, Rush W, Mena H (1997) Primary spinal paragangliomas: a clinicopathological and immunohistochemical study of 30 cases. Histopathology 31: 167-173.
- Scott HW Jr, Reynolds V, Green N, Page D, Oates JA, et al. (1982) Clinical experience with malignant pheochromocytomas. Surg Gynecol Obstet 154: 801-818.
- Thines L, Lejeune JP, Ruchoux MM, Assaker R (2006) Management of delayed intracranial and intraspinal metastases of intradural spinal paragangliomas. Acta Neurochir (Wien) 148: 63-66.
- da Silva ME, Carvalho MJ, Rodrigues AP, Neves NS, Gonçalves AM, et al. (2012) Rare vertebral metastasis in a case of Hereditary Paraganglioma. Hered Cancer Clin Pract 10: 12.
- Ilgren EB, Teddy PJ (1984) Chemodectoma of the cauda equina: case report. Clin Neuropathol 3: 148-152.
- Russell CD, Jander HP, Dubovsky EV (1975) Demonstration of a chemodectoma by perfusion scanning: case report. J Nucl Med 16: 472-473.

This article was originally published in a special issue, [Advanced Techniques in Spine Surgery](#) handled by Editor. Dr. Alessandro Landi, University of Rome Sapienza, Italy