

## Diaphragmatic Hernia Resembling Tension Pneumothorax

Luis Angel Medina Andrade\* and Staphanie Serrano Collazos

Universidad de Quintana Roo, Hospital General Regional #17, Department of General Surgery, Mexican Social Security Institute (IMSS), Cancun, Quintana Roo, Mexico

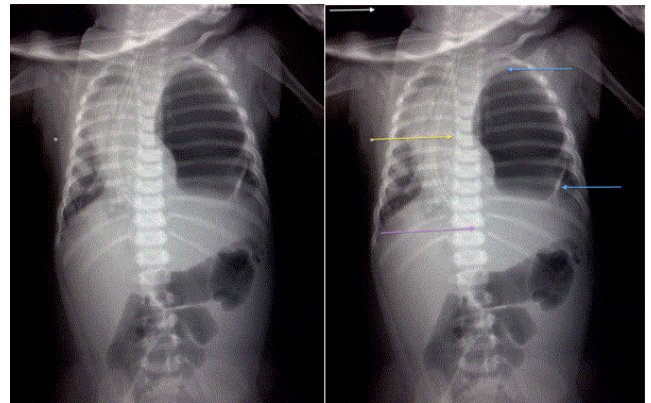
\*Corresponding author: Luis Angel Medina Andrade, Universidad de Quintana Roo, Department of General Surgery, Mexican Social Security Institute (IMSS), Cancun, Quintana Roo, Mexico, Tel: +52559981114201; E-mail: [buismedina\\_5@hotmail.com](mailto:buismedina_5@hotmail.com)

Received date: February 12, 2016; Accepted date: February 15, 2016; Published date: February 22, 2016

Copyright: © 2016 Medina Andrade Luis Angel, et al. This is an open-access article distributed under the terms of the Creative Commons Attribution License, which permits unrestricted use, distribution and reproduction in any medium, provided the original author and source are credited.

### Clinical Image Article

An 8-months male patient presents at Emergency Department with respiratory distress. His parents refer beginning of symptoms two days ago with worsening 10 hours previous to first contact. After initial minutes of initial evaluation and x-ray performance the patient present cardiorespiratory failure and cardio pulmonary reanimation was given to him. At physical examination without ventilation in left hemithorax, a hematoma in the left axillar region was noted and a tension pneumothorax suspected. After the first two cycles of compressions surgery department service was informed of the case. By the mentioned facts and a radiograph resembling a tension pneumothorax with displacement of vessels and heart to the right hemithorax, a decompression puncture was performed in medial clavicular line second intercostal space obtaining air and a white fluid resembling milk. A diaphragmatic hernia was suspected in this moment but pulse was not obtained after reanimation maneuvers and exploratory laparotomy could not be performed.



**Figure 1:** Toraco-abdominal X-ray showing cardiac displacement to the right and an air bubble in left hemithorax resembling tension pneumothorax. White arrow: Top of the image; Yellow arrow: Great vessels and hearth displacement; Purple arrow: End of nasogastric tube; Blue arrows: Gastric wall.