

Differentiating Osteomyelitis from Charcot Joint by Using Sulphur Colloid and Besilosomab (Scintimun®) Scan at Sarawak General Hospital

Zool Hilmi Bin Awang*, Anthony Louis Kindu, Nadiyah Abd Razak, Wan Muhd Anas Bin Wan Hussain, Saieehwaran Menon and Nurul Nadiyah Zulkifli

Department of Nuclear Medicine, Sarawak General Hospital, Kuching, Malaysia

*Corresponding author: Zool Hilmi Bin Awang, Department of Nuclear Medicine, Sarawak General Hospital, Kuching, Malaysia, Tel: 0326905836; Fax: 0326155714; E-mail: zoolhilmi_75@hotmail.com

Received date: December 26, 2016; Accepted date: January 02, 2017; Published date: January 09, 2017

Copyright: © 2017 Awang ZHB, et al. This is an open-access article distributed under the terms of the Creative Commons Attribution License, which permits unrestricted use, distribution, and reproduction in any medium, provided the original author and source are credited.

Abstract

Introduction: Differentiating osteomyelitis (OM) from charcot joint is a vital necessity. Despite having almost similar presentation, both OM and charcot joint are managed vastly different. This study proposes the use of combined Sulphur Colloid and Besilosomab (Scintimun) scan to differentiate OM from Charcot Joint based on the understanding of their dissimilar pathophysiology.

Method: Image acquisitions of two patients using the ^{99m}Tc -Scintimun and ^{99m}Tc -Sulphur colloid were obtained accordingly at the affected sites.

Result: Both patients produced similar images on the combined Sulphur Colloid and Scintimun scans. There were increased activity on both Sulphur Colloid and Scintimun scans which suggested the exclusion of OM in both cases. Both patients were treated conservatively by the primary team.

Conclusion: The combined study of Scintimun and Sulphur Colloid imaging is a useful tool in assisting the primary team to exclude OM although a wider data sample is needed to further support this study.

Keywords: Osteoyelitis; ^{99m}Tc -Scintimun; Sulphur colloid imaging; Osteoblasts; Besilosomab

Introduction

In 2006, it is said that we lost 4% to 7% foot to infections in a year. Being a country with 14.9% of the population having diabetes mellitus (DM), the number might have increased as the accurate method for screening and diagnosis yet still unestablished [1]. Differentiating between osteomyelitis (OM) and Charcot joint has been the most difficult in chronic patients as they have almost similar presentations. Patients' low level of awareness and late presentations complicate the diagnosis even more. Taking into account that the management of each differs dramatically, as the former may warrant an amputation while the latter needs conservative therapy, a reliable tool for assessment with high sensitivity and specificity is much needed.

OM is a progressive infection process involving various components of bone; periosteum, medullary cavity and cortical bone. It is characterized by progressive, inflammatory destruction of bone, namely by necrosis and by new bone apposition. Many bacteria can cause OM. *Staphylococcus aureus* is the predominant microorganism with up to 50% of cases. Acute OM evolves over several days to week, forming osteonecrosis, soft tissue necrosis and neutrophilic granulocytes infiltration into the edematous medullary spaces.

In chronic OM, osteoneogenesis occurs as spongy osseous tissue is bordered by osteoblasts. Medullary space shows fibrosis and granulation tissue formation with infiltration of macrophages predominantly, lymphocytes, plasma cells and a few neutrophilic granulocytes [2].

On the other hand, Charcot Joint or Charcot osteoarthropathy is a progressive, relatively painless degenerative arthropathy of single or multiple joints caused by underlying neurological deficits. Peripheral joints are most commonly affected. The etiology of Charcot arthropathy in diabetic patient is due to loss of proprioception, thus increasing the tendency of local inflammation, even when triggered by a minor injury, infection, operation or ulceration.

In diabetic patient with Charcot arthropathy, there is imbalance between pro and anti-inflammatory cytokines that restrains the inflammatory response. There will be increased in proinflammatory cytokines with decreased in anti-inflammatory cytokines.

Hence, the affected site is exposed to prolonged inflammatory response. Increased amounts of proinflammatory cytokines, especially tumor necrosis factor- α (TNF- α) triggered another cytokines pathway (receptor activator of nuclear factor- κB ligand, RANKL) and induces osteoclasts precursor to differentiate into mature osteoclasts. The precursor cells of osteoclasts, monocytes, are the first cell to dysfunction. Anti-inflammatory secretion is reduced as a result of high levels of dysfunctional monocytes thus increases resistance to apoptosis. As a consequence, this will further prolong the already prolonged and intense inflammatory response [3-5].

A study done by Palestro et. al [6] concluded that the combined study of WBC and bone marrow imaging; using ^{111}In -labelled WBC and sulphur colloid might have increased the accuracy of diagnosing OM up to 90% in altered marrow distribution cases. Palestro et. al [6] study was based on the understanding that both WBCs and Sulphur Colloid accumulate in marrow regardless of its location, whereas only WBCs accumulate at the infection sites.

By using the similar understanding of their different pathophysiologicals, our study has proposed the use of combined ^{99m}Tc -Scintimun and ^{99m}Tc -Sulphur colloid in differentiating OM from Charcot joint. Technetium-99 was chosen in this study due to its availability in our centre.

Sulphur Colloid and Besilosomab (Scintimun) both accumulate in the bone marrow. However, only the Scintimun accumulates at the site of infection. Sulphur Colloid is taken up by the reticuloendothelial system (RES) rich structures; which are monocytes predominant, thus uptake in this area marks inflammatory process in Charcot arthropathy [6,7]. In acute OM, there is a combination of low oxygen tension, acidic pH, vascular insufficiency, and elevated intraosseous pressure that suppresses or destroys the bone marrow macrophages at the infection site [2]. Therefore, this prevents the uptake of Sulphur Colloid at affected site, thus producing a photopenic lesion on the Sulphur Colloid image.

On the other hand, Scintimun; a murine IgG1k antibody BW 250/183 recognizes the presence of non-specific cross-reacting antigen 95 (CRA-95). It is found mainly in the cytoplasm and on the cell membrane of granulocytes and granulocyte precursor cells. These cells are present in major amounts in hematopoietic bone marrow, inflammation and infection lesions. There are two theories that explain the uptake of Scintimun during the scintigraphy.

The first theory involves the targeting of NCA-95 on the circulating granulocytes in the bloodstreams with subsequent migration of Scintimun-labelled granulocytes to the inflammatory and infection sites. The other theory believes that the free Scintimun is transported to the inflammatory and infection sites via bloodstream. The free Scintimun is then sequestered to the extravascular space due to an increased capillary permeability followed by specific binding to the granulocytes. In OM, increased neutrophilic granulocytes infiltrate the edematous medullary spaces. This in turn, will show up as increased activity on the Scintimun images. As a result, both infection and inflammation are indistinguishable on Scintimun scintigraphy as both processes will have increased activities on their images [8].

Methods

Image acquisition for Scintimun was done 4 hours after injection of 600 MBq ^{99m}Tc -Scintimun with anterior, posterior, lateral, medial and SPECT views of affected site taken using Siemens E-Cam Duet.

Sulphur colloid for bone marrow imaging was done after 48 hours, preferably 72 hours apart as per protocol. Scan was done 30 minutes after injection of 370 MBq, ^{99m}Tc -Sulphur colloid. Anterior, posterior, lateral, medial and SPECT views of affected site were taken using Siemens E-Cam Duet.

Case Report

Mr. X, a 37 year old male with uncontrolled DM came to emergency department (ED) for on and off fever with swollen right foot which was associated with hemoserous discharge since two weeks ago. He had a history of necrotizing fasciitis at the same area a year before, for which he underwent wound debridement with split-skin graft (SSG) at dorsal aspect of right foot and right second toe amputation.

The lesion had started off as a blister at the SSG site. After it ruptured, it became a pustular lesion. On presentation and examination, there were 3 sinuses with hemoserous discharge on the dorsal part of the right foot. Right foot x-ray done showed no OM

changes. Soft tissue culture from the right foot showed no growth (Figures 1 and 2).

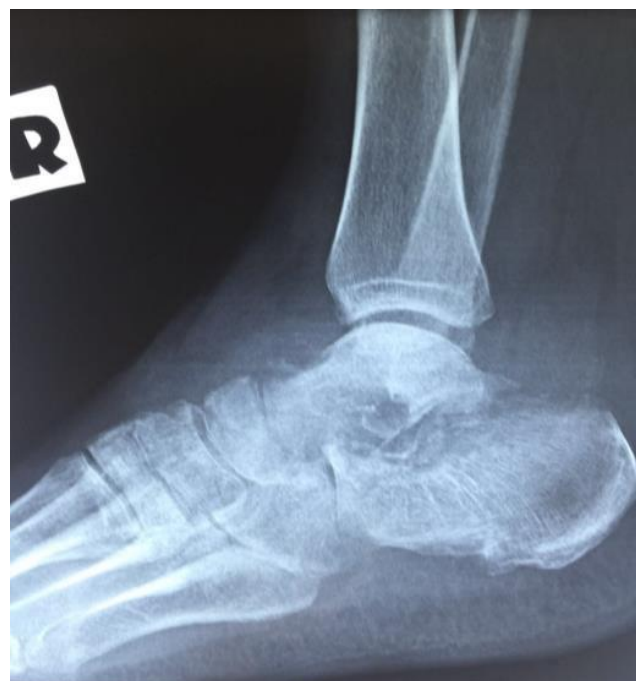

Figure 1: Mr X's lateral view of right ankle. No OM changes.

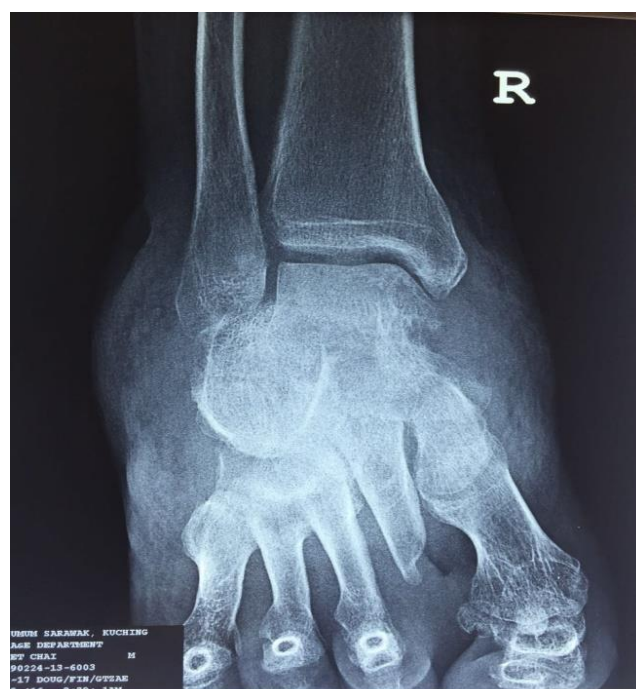

Figure 2: X-ray anterior view of Mr X's right ankle. He had Ray's amputation of 2nd metatarsal for infected diabetic foot ulcer. Otherwise, no OM changes noted at ankle region.

He then underwent Sulphur Colloid and Scintimun scan, both at at least 72 hours apart. Scan showed that OM was excluded. However this patient defaulted his Orthopaedic follow up, thus further assessment could not be acquired (Figures 3 and 4).

Another patient, Mr. Y, a 53 year old male with uncontrolled DM came for left plantar abscess for 1 month. He underwent incision and drainage (I and D) and had on and off hemerosous discharge from the plantar aspect upon post operation follow up. Cultures taken intraoperative yielded *Staphylococcus epidermidis* which is a common skin flora (Figures 5 and 6).

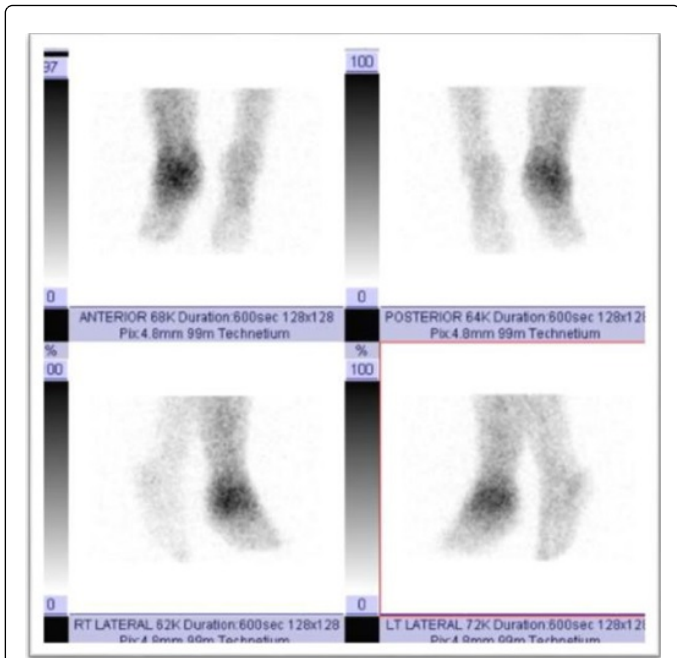


Figure 3: ^{99m}Tc-Besilosomab (Scintimun®) scan of Mr. X shows focal uptake at ankle region of right foot.

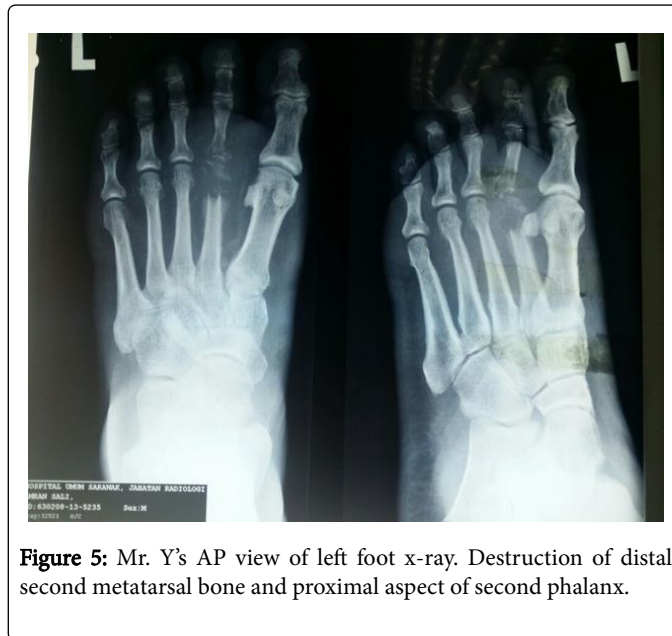

Figure 5: Mr. Y's AP view of left foot x-ray. Destruction of distal second metatarsal bone and proximal aspect of second phalanx.

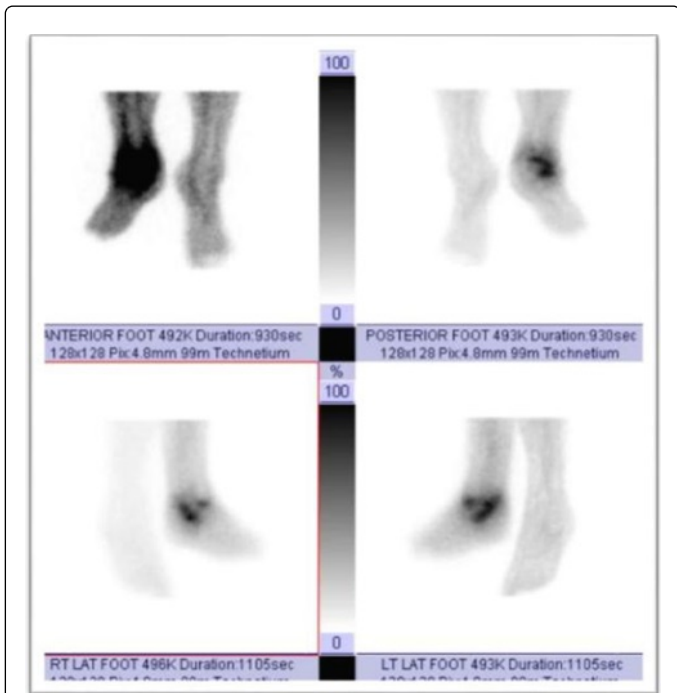


Figure 4: ^{99m}Tc-Sulphur colloid scan of right ankle of Mr. X showed focal uptake at ankle region corresponding to his Scintimun scan.

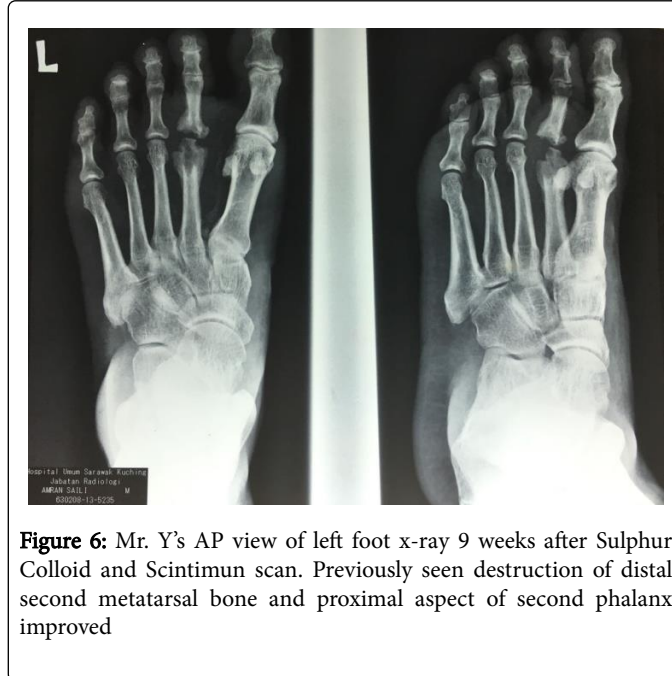


Figure 6: Mr. Y's AP view of left foot x-ray 9 weeks after Sulphur Colloid and Scintimun scan. Previously seen destruction of distal second metatarsal bone and proximal aspect of second phalanx improved

A Sulphur colloid and Scintimun scan was done for him, both at at least 72 hours apart. Scan showed that OM was excluded. On follow up with Orthopaedic, Mr. Y was not posted for any active surgical intervention and was treated conservatively. On his last follow up, 9 weeks after the scan, a repeated left foot x-ray was done and it showed improvement of the bony structures with no more discharge from the plantar aspect of the left foot (Figures 7 and 8).

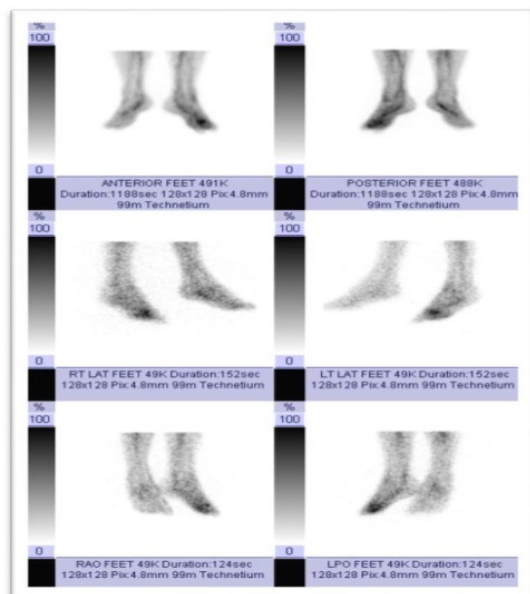


Figure 7: ^{99m}Tc -Besilosomab (Scintimun®) scan of Mr. Y's left foot showed focal increased tracer uptake at tarsal region of left foot.

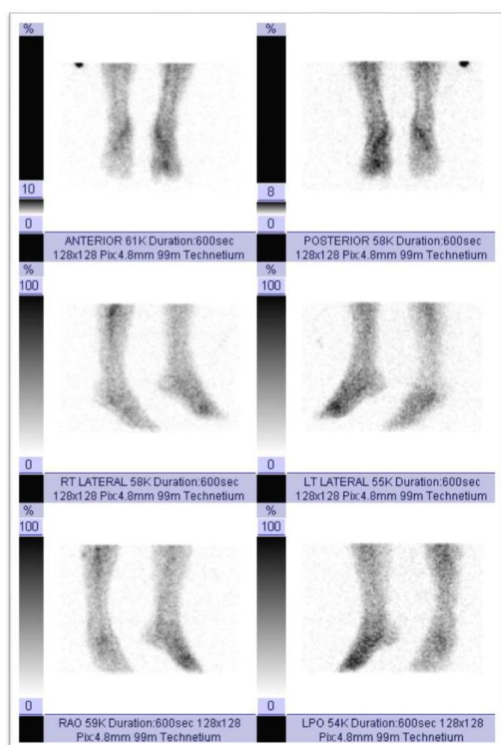


Figure 8: ^{99m}Tc -Sulphur Colloid scan of left foot of Mr Y showed similar uptake as his Scintimun scan.

Discussion

In both of our case studies, increased uptakes were seen on the combined Sulphur Colloid and Scintimun images. Therefore, both cases excluded OM. Based on our scan findings, both patients were treated conservatively and the initial plans of surgical interventions were abandoned by the primary team. However, we realised that increased tracer uptake on the sulphur colloid may not exclusively represent Charcot Joint, but could also signify other inflammation processes. Mr. Y's repeated foot X ray 9 weeks after our scan showed improvement of previous destructed bones. This improvement would not be seen in the progressive and destructive pathophysiology of Charcot Joint. Therefore, we concluded that this combined study may help in excluding OM but it is not specific for diagnosing Charcot Joint.

The combined Scintimun and Sulphur colloid scan costs roughly RM4000 per patient. Considering the scan may prevent unnecessary surgical intervention, which may cause permanent disability to the patient, the cost is acceptable provided a thorough selection of patients have been conducted.

Conclusion

The combined study of WBC and bone marrow imaging; Scintimun and Sulphur Colloid imaging is a useful tool in assisting the primary team to exclude OM which in turn help in patient's management. However, a wider sample of data is needed in the future to support this study.

References

- Chin LN (2011) Foot at Risk. Health in The Star Online. Berhad, Malaysia.
- Roy M, Somerson JS, Kerr KG, Conroy JL (2012) Pathophysiology and Pathogenesis of Osteomyelitis. In: Baptista MS, Tardivo JP, editors. Immunology, Allergology and Rheumatology. InTechOpen, Croatia.
- Moline L, Darmon P, Raccach D (2010) Charcot's foot: Newest findings on its pathophysiology, diagnosis and treatment. *Diabet Metab* 36: 251-255.
- Holmes C, Schmidt B, Munson M, Wrobel JS (2015) Charcot stage 0: A review and considerations for making the correct diagnosis early. *Clin Diabet Endocrinol* 1: 18.
- Kaynak G, Birsel O, Guven MF, Ogut T (2013) An overview of the Charcot foot pathophysiology. *Diabet Foot Ankle*. 4: 21117.
- Palestro CJ, Love C, Tronco GG, Thomas MB, Rini JN (2006) Combined Labeled Leukocyte and Technetium 99m Sulfur Colloid Bone Marrow Imaging for Diagnosing Musculoskeletal Infection. *Radiographic* 26: 859-870.
- Palestro CJ, Mehta HH, Patel M, Freeman SJ, Harrington WN, et al. (1998) Marrow versus Infection in the Charcot Joint: Indium-111 Leukocyte and Technetium-99m Sulfur Colloid Scintigraphy. *J Nucl Med* 39: 346-50.
- Richter WS, Ivancevic V, Meller J, Lang O, Le Guludec D, et al. (2011) ^{99m}Tc besilosomab (Scintimun) in peripheral osteomyelitis: comparison with ^{99m}Tc -labelled white blood cells. *Eur J Nucl Med Mol Imaging* 38: 899-910.