

Does Giant Multilocular Cystadenoma of Prostate Respond to LHRH Agonist or It Is a Case of Cystic Prostate Cancer Wrongly Diagnosed – A Report of 3 Cases and Review of Literature

Abeeku Afedzi Hammond*, Alison Bradley, Vijay Ramani and Miles Howe

University Hospital of South Manchester, NHS Foundation Trust, UK

Abstract

A retrospective review of radiology registry identified 3 cases of diagnosed giant multilocular cystadenoma of prostate. The first case illustrates a 59-year-old man with worsening voiding and storage symptoms of 2 months duration. The prostate was enlarged with the right lobe being bigger than the left node and his PSA was 9.3 ug/l. MRI showed large Multi cystic mass from the prostate and TRUS biopsy revealed adenocarcinoma prostate. Neoadjuvant LHRH agonist shrunk the mass before radiotherapy. He has no urinary symptoms and PSA consistently less than 0.1. Repeat MRI showed highly shrunken mass. In the second case, we present a 79-year-old patient presenting with rising PSA despite being on finasteride. MRI diagnosed large cystic and solid mass arising from the prostate and extending to the abdomen. Tran's rectal ultrasound guided biopsy plus aspiration of the fluid from the multiloculated cyst revealed benign cystic adenoma with no evidence of any malignancy. Repeat MRI after 6 months of LHRH agonist showed multiloculated cyst adenoma of the prostate appears stable with no significant reduction in size and his PSA remains high. The third case is an 83-year-old presenting with LUTS, haematuria and rising PSA. He has a past medical history of low grade prostate cancer (diagnosed at TURP). MRI scan showed an enlarged echogenic prostate. TRUS biopsy of the mass identified complex proliferation of atypical glandular epithelium in a rather villous adenomatous pattern. Neoadjuvant LHRH agonist showed reduction in lower urinary symptoms.

Keywords: Multilocular cystadenoma; Luteinising hormone releasing hormone; Cystic prostate cancer

Case Reports

Case 1

A 59-year-old Caucasian man presented with both worsening urinary voiding and storage symptoms of 2 months duration. In addition, he complained of dysuria but he denied fever, chills, rigors or penile discharges. He has background history of hypertension and impaired glucose tolerance. He is a non-smoker and moderately consumes alcohol. On examination, his external genitalia were normal. The prostate was enlarged and non-tender. The right lobe of the prostate was bigger and irregular with palpable nodules. Urinalysis was negative and mid-stream urine grew no organism. His prostate specific antigen (PSA) was 9.3 ug/l. His flow rate was 15 ml/s and had a residual volume of 50 ml. In view of his high prostate specific antigen (PSA) and enlarged prostate, a Trans Rectal Ultrasound (TRUS) guided biopsy was done and revealed a focus of 3+4 (mostly 3) adenocarcinoma prostate. Magnetic Resonance Imaging (MRI) requested for staging showed a large multi-cystic mass lesion arising from lateral aspect of base of prostate, displacing bladder base superiorly and extending down right side of prostate to para-urethral tissues in the region of membranous urethra. Bone scan was negative. At urology, multi-disciplinary team (MDT) an option of Luteinizing Hormone-Releasing Hormone (LHRH) was started with the aim of shrinking the mass to make it operable or to have radiotherapy. Repeat MRI 3 months after hormonal manipulation showed improvement of the peripheral zones that contained the carcinoma. There was also shrinkage of the multilocular right para-prostatic and para-urethral cystic mass. Further repeat MRI showed further shrunken cystic mass, but still has the urethra involved. At another MDT, a decision was taken on whether to subject him to surgery or radiotherapy, however due to the low position in the urethra of some residual cystic lesion; it was felt that radiotherapy would be superior. He had an adjuvant radical course of radiotherapy to his prostate after 9 months of LHRH and continued LHRH two years radiotherapy. Periodic PSA check within the two years post radiation LHRH therapy was constantly less than 0.1. PSA 3 months after

stopping LHRH was also unrecordable and MRI also showed further improvement of the pelvic mass as compared to previous scans. He is being monitored yearly and his PSA and PSA nadir consistently low. He doesn't have any urinary symptoms anymore and will return to LHRH alone or in combination with radiotherapy if PSA rises or symptoms reoccur (Figures 1 and 2).

Case 2

A 79-year-old patient referred from another facility as a case of a

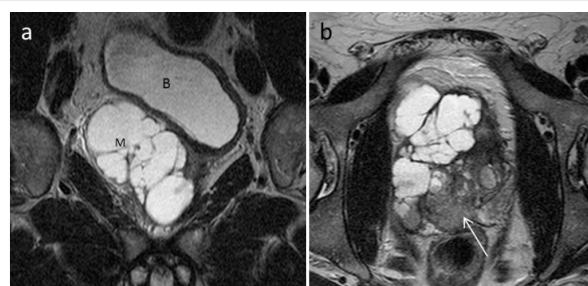


Figure 1: (a) T2W coronal, (b) T2W axial sections through the pelvis. The bladder (B) is displaced superiorly and to the left by a multiloculated cystic mass (M). Note the low signal area in the right peripheral zone (white arrow) which corresponded to the biopsy proven Gleason 7 prostate cancer.

*Corresponding author: Abeeku Afedzi Hammond, University Hospital of South Manchester, NHS Foundation Trust, UK, Tel: +44 161 998 7070; E-mail: hammonda04@yahoo.com

Received July 05, 2017; Accepted July 20, 2017; Published July 25, 2017

Citation: Hammond AA, Bradley A, Ramani V, Howe M (2017) Does Giant Multilocular Cystadenoma of Prostate Respond to LHRH Agonist or It Is a Case of Cystic Prostate Cancer Wrongly Diagnosed– A Report of 3 Cases and Review of Literature. J Clin Case Rep 7: 996. doi: 10.4172/2165-7920.1000996

Copyright: © 2017 Hammond AA, et al. This is an open-access article distributed under the terms of the Creative Commons Attribution License, which permits unrestricted use, distribution, and reproduction in any medium, provided the original author and source are credited.

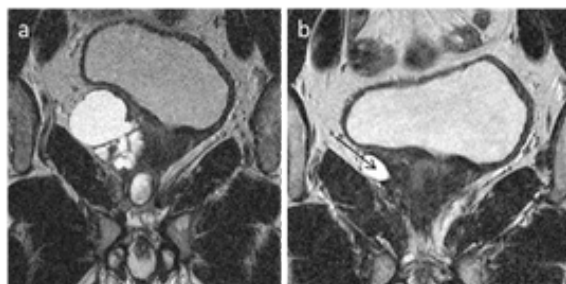


Figure 2: Coronal sections from repeat MRI prostate (a) 3 months and (b) 6 months after the initial study. At 3 months, the mass has shrunk considerably, but the multicystic nature is still evident. At 6 months, only one small cystic locule is seen (black arrow), demonstrating the excellent response to LHRH treatment.

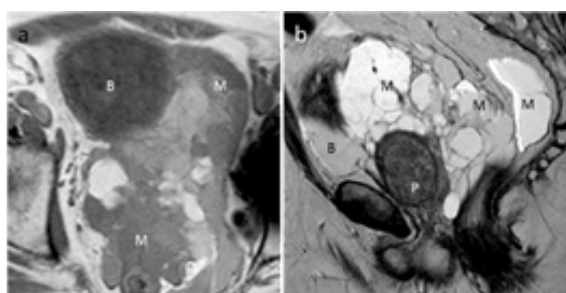


Figure 3: (a) T1W axial and (b) T2W sagittal. The multicystic mass (M) surrounding the prostate gland (P) and bladder (B) has locules of different signal on the T1W image, but appears of uniformly high signal on the T2W. The mass extends around the rectum posteriorly. The bladder is displaced anteriorly.

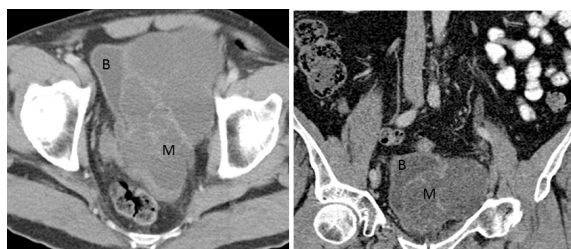

Figure 4: (a) axial and (b) Coronal portal venous phase CT. The central pelvic multiloculated mass (M) demonstrated enhancement within the septa. It is displacing the bladder (B) superiorly and to the left.

rising PSA despite being on finasteride. MRI diagnosed large cystic and solid mass arising from the prostate and extending to the abdomen. He denies any urinary or bowel symptoms. He has a background history of hypertension, previous laminectomy, right total knee replacement and left total hip replacement. Examination of his abdomen was unremarkable. With the exception of phimosis, the external genitalia were unremarkable. His prostate was firm 30 cc with a fluctuant area commencing in the midline at the apex extending upwards. Trans rectal ultrasound guided biopsy plus aspiration of the fluid from the multiloculated cyst was done. The results came out as benign cystic adenoma with no evidence of any malignancy. MDT consensus was to put him on LHRH as it has shown regression in these types of lesions. Repeat MRI after 6 months and 12 months showed multiloculated cyst adenoma of the prostate appears stable with no significant reduction in size. MDT agreed on two options, either to stop the LHRH or to continue with it. If continued it is unlikely to reduce the size of the abnormality but may stop it from getting bigger, however the alternative if continued would be to assess patient with a scan in a year's time. The potential

for the abnormality to increase in size off medication is unknown. He has agreed to stop medication and have surgery if future scan shows increase in size of the mass (Figure 3).

Case 3

An 83-year-old man was referred from another facility in 2008 as a case of lower urinary tract symptoms (LUTS), haematuria, rising PSA and CT scan diagnosed “puzzled” left pelvic mass. He had no bowel symptoms. He has a past medical history of low grade low volume prostate cancer (Gleeson 3+3 diagnosed at TURP) managed by watchful waiting and aortic stenosis. His examination findings were unremarkable. His PSA was 40. MRI scan showed an enlarged echogenic left lobe of the prostate with prostate volume 57 cc and cystic areas within the left lobe. An initial diagnosis of seminal vesicle cyst was made by the radiologist. Chest X-ray was normal. Mid-stream urine was mixed growth without any predominant organism. Trans rectal ultrasound guided biopsy of the mass was done showing complex proliferation of atypical glandular epithelium in a rather villous adenomatous pattern. Immunohistochemistry for high molecular weight cytokeratin was almost totally negative throughout the epithelium. At MDT, he was put on LHRH which showed reduction in lower urinary symptoms. He later had an extra peritoneal exploration and deroofting of a large multiloculated left pelvic cyst that was adherent and compressing bladder. Histology from the base of the cyst showed confirmed slightly upgraded prostate cancer and no other pathology was identified. The epithelium was PSA positive. Cytology preparations showed blood and pigment laden with no malignant cells seen. He is having adjuvant LHRH and the PSA has dropped considerably. He is currently on lifelong LHRH and 6 monthly PSA check. His last checked PSA was 6.9. His LUTS (relating to reduced bladder capacity) has improved considerably (Figure 4).

Discussion

Prostate cyst adenoma is a relatively rare benign neoplasm originating from the prostate. Maluf et al. described this pathology in 1991 and proposed the name prostate cyst adenoma by Maluf et al. in 1991 [1]. Most patients present with voiding and storage urinary symptoms mimicking benign prostate hyperplasia [2,3]. A few of the patients present with haematuria [4] abdominal distention, abdominal mass [5,6] constipation [6] or infertility [7,8]. Over the years prostate cyst adenoma has been wrongly diagnosed, as in-depth literatures do not exist pertaining to this pathology and most definite diagnosis are done only after surgical resection. Recently with the increasingly wide availability of many imaging facilities around most hospital, this pathology is gradually being picked up before intervention thus enhancing our knowledge of prostatic cyst adenomas. Few cases have been published with [7,9,10] patients age ranging from 20 years to 80 years [4] and also varying range of sizes. Many diverse midline retro vesical pathologies may mimic prostate cyst adenoma and examples include simple cyst of the prostate, prostatic cyst carcinoma, cyst of the müllerian ducts, prostatic utricle cyst, ejaculatory duct cyst, prostatic abscess, pelvic mesothelioma, lymphangioma, Multilocular peritoneal inclusion cyst, teratoma.

Conclusion

Prostate cyst adenomas can be anatomically separated from the prostate [1] or attached to the prostate by a pedicle [4]. They mostly produce mass effect and do not invade adjacent structures. Macroscopic, microscopic or radiological evidence of invasion rules out prostatic cyst adenoma or possibly cohabitation with prostate cancer or other malignancies, however adherence to surrounding structures [11] have been reported thus increasing the chance of recurrence. The

prostate cystadenomas are surrounded by membranous membrane and histologically are composed of glandular and cystic structures. The cysts are lined by columnar and cuboid epithelia cells with pale cytoplasm and basally located nuclei. The prostatic origin of the epithelia is usually confirmed by positive immunohistochemically staining for PSA [12,13]. The sequelae or natural history of the disease prostate cyst adenoma still remains a mystery and there is still not a generally accepted consensus on optimum management. Surgery is currently the preferred treatment option despite Datta et al. reporting otherwise [3]. Surgery provides samples for pathological diagnosis as well as a cure. Recently luteinising hormone releasing hormone has been used with marked improvement in symptoms and the cases described showed success apparently from the use of LHRH agonist alone, or as neoadjuvant or adjuvant. However, the twist of the story is most scientists admit difficult diagnosis pre-operatively and a handful of possible successful treatment with LHRH agonist may in fact be a cystic prostate cancer that was wrongly diagnosed as prostate cystadenoma or rather a combination of prostate cyst adenoma and cystic prostate cancer. Both of these lesions are extremely rare and have similar cytoarchitecture [9] leading to wrong diagnosis. The 3 cases described above buttress the point that patients with co-existing prostate cancer had success story with LHRH and just prostate cyst adenoma had no response with LHRH. Currently with improved diagnostic knowledge patient with co-existing prostate cancer can be tried on LHRH and not necessarily on giant multilocular cystadenoma of prostate. This case report also supports the fact that the treatment of choice for giant multilocular prostatic cystadenoma is complete surgical excision.

References

1. Maluf HM, King ME, DeLuca FR, Navarro J, Talerma A (1991) Giant multilocular prostatic cystadenoma: A distinctive lesion of the retroperitoneum in men. A report of two cases. *Am J Surg Pathol* 15: 131-135.
2. Allen EA, Brinker DA, Coppola D, Diaz JI, Epstein JI (2003) Multilocular prostatic cystadenoma with high-grade prostatic intraepithelial neoplasia. *Urology* 61: 644.
3. Datta MW, Hosenpud J, Osipov V, Young RH (2003) Giant multilocular cystadenoma of the prostate responsive to GnRH antagonists. *Urology* 61: 225.
4. Seong BM, Cheon J, Lee JG, Kim JJ, Chae YS (1998) A case of multilocular prostatic cystadenoma. *J Korean Med Sci* 13: 554-558.
5. Rusch D, Moizadeh A, Hamawy K, Larsen C (2002) Giant multilocular cystadenoma of the prostate. *Am J Roentgenol* 179: 1477-1479.
6. Olgun DC, Onal B, Mihmanli I, Kantarci F, Durak H, et al. (2012) Giant multilocular cystadenoma of the prostate: A rare cause of huge cystic pelvic mass. *Korean J Urol* 53: 209-213.
7. Park JP, Cho NH, Oh YT, Choi YD (2007) Giant multilocular prostatic cystadenoma presenting with obstructive aspermia. *Yonsei Med J* 48: 554-556.
8. Mosharafa AA, Torky MH, Ragab Y, Dahba N (2011) Prostate cystadenoma presenting with obstructive azoospermia. *J Androl* 32: 364-366.
9. Tuziak T, Spiess PE, Abrahams NA, Wrona A, Tu SM, et al. (2007) Multilocular cystadenoma and cystadenocarcinoma of the prostate. *Urol Oncol* 25: 19-25.
10. Chowdhury MM, Abdulkarim JA (2009) Case report. Multilocular cystadenoma of the prostate presenting as a giant pelvic mass. *Br J Radiol* 82: e200-e201.
11. Choi YH, Namkung S, Ryu BY, Choi KC, Park YE (2000) Giant multilocular prostatic cystadenoma. *J Urol* 163: 246-247.
12. Levy DA, Gogate PA, Hampel N (1993) Giant multilocular prostatic cystadenoma: A rare clinical entity and review of the literature. *J Urol* 150: 1920-1922.
13. Lim DJ, Hayden RT, Murad T, Nemcek AA, Dalton DP (1993). Multilocular prostatic cystadenoma presenting as a large complex pelvic cystic mass. *J Urol* 149: 856-859.