

## Effects of Combination Therapy of Repetitive Transcranial Magnetic Stimulation and Intensive Physiotherapy on Adult Patients with Cerebral Palsy-Study of Two Patients with Spastic Diplegia

Aya Okamichi, Masahiro Abo\* and Yasuhide Nakayama

Department of Rehabilitation Medicine, The Jikei University School of Medicine, Tokyo, Japan

\*Corresponding author: Masahiro Abo, MD, PhD, Department of Rehabilitation Medicine, The Jikei University School of Medicine, 3-25-8, Nishi-Shimbashi, Minato-Ku, Tokyo 105-8461, Japan, Tel: +81-3-3433-1111; Fax: +81-3-3431-1206; E-mail: abo@jikei.ac.jp

Received date: July 05, 2018; Accepted date: July 18, 2018; Published date: July 20, 2018

Copyright: ©2018 Okamichi A, et al. This is an open-access article distributed under the terms of the Creative Commons Attribution License, which permits unrestricted use, distribution, and reproduction in any medium, provided the original author and source are credited.

### Abstract

We often reported beneficial effects on post stroke upper-limb hemiparesis by using combination therapy of repetitive transcranial magnetic stimulation (rTMS) and intensive therapy. This time, we performed this method on adult patients with cerebral palsy, despite being able to walk independently, both patients presented gait problems, such as scissor gait and crouching posture due to the spasticity of lower limbs. Both patients showed reduced spasticity of lower limbs, resulting in the ability to perform isolated movements, which was difficult prior to the intervention, and demonstrated gait improvement due to increased muscular strength. The acquired effect continued one month after the discharge. Combination therapy of rTMS and intensive PT was effective for gait improvement in adult patients with cerebral palsy.

**Keywords:** Adult cerebral palsy; Spastic paralysis; Repeated transcranial stimulation; Intensive physical therapy; Gait

### Introduction

Although cerebral palsy is known to be neurologically non-progressive, secondary disorders of the musculoskeletal system often become a problem with aging [1].

Many patients with spastic diplegia start the treatment during their infancy and acquire some type of gait ability around the time of starting school. However, along with the increase in height, the difference in the growth between the biarticular muscle group and the bones becomes significant in the lower limbs. Therefore, patients typically present hip adduction/flexion, knee flexion, and ankle equinus, leading to the exacerbation of a gait pattern. In many cases, patients develop hip pain and advanced scoliosis due to a dislocated hip and degenerative hip disease, resulting in difficulty or inability for ambulation [2,3].

Various types of rehabilitation, such as Neurodevelopmental Therapy (NDT), the Vojta method and the Ueda method, are being carried out for motor dysfunction in children with cerebral palsy. However, there have been no reports that demonstrate the greater effectiveness of these methods than general exercise therapy, with no specific procedures recommended.

In adulthood, although the importance of the prevention and improvement of secondary disorders has been reported, there have been few reports of intervention in rehabilitation, aiming to improve physical function. Therefore, we believe that treatment methods based on high medical rationale have not yet been established. There are currently not enough reception facilities, including environments such as institutions that conduct rehabilitation, for adult patients with cerebral palsy.

Department of Rehabilitation Medicine, the Jikei University School of Medicine, Tokyo, has reported many trials that demonstrate the effectiveness of the combined therapy of Repetitive Transcranial Magnetic Stimulation (rTMS) and intensive occupational therapy for upper limb hemiparesis in post-stroke patients [4-7].

rTMS is an approach that activates the cerebral cortex of the lesional hemisphere through the reduction of the interhemispheric inhibition by stimulating the cerebral cortex of the non-lesional hemisphere with inhibitory low-frequency rTMS [5]. Combination therapy of low-frequency rTMS and intensive occupational therapy demonstrated an anti-spasticity effect on the affected upper limb, confirming the safe and significant improvement of motor function of the affected upper limb [6]. The improvement of motor function in the affected limb appears to occur by activating the processing of the brain-derived neurotrophic factor [7]. And this combination therapy showed the superiority relative to constraint-induced movement therapy; this therapy improved the motion of the whole upper limb and resulted in functional improvement in activities of daily living [4].

Control of spasticity is important not only for motor function in upper limb paresis, but also for gait in patients with spastic diplegia from cerebral palsy. In the current study, we report the investigation of the clinical effects of combined therapy of rTMS and intensive PT on two hospitalized adult patients with spastic diplegia.

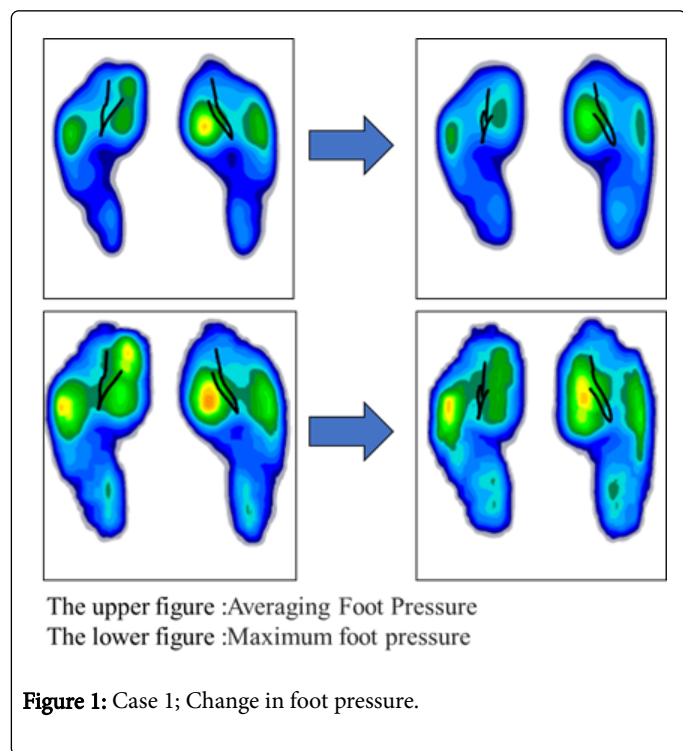
### Case Report

#### 29-year-old woman

**Overview:** After graduating from university, the patient works as a clerical worker at a company. She currently lives alone. Although she had received periodic rehabilitation at a medical institution until she was a junior high school student, she does not currently have access to a rehabilitation service. Therefore, the patient is concerned that her gait will deteriorate in the future.

**Chief complaints:** “I want to be able to walk naturally” and “I want to walk without hitting one leg against the other.”

**History:** Received Achilles tendon lengthening once for each leg during childhood. Evaluation at admission (Table 1, Figure 1).



No abnormalities were found in general biochemical findings. Muscle tone measured by the Modified Ashworth scale (MAS) was 1+ for hip adductor muscles on both sides, 2 for the right and 1 for the left of both hip flexor muscles and ankle plantar flexor muscles. The abdomen, especially the lower part, was so hypotonic that the muscle contraction was slightly palpable by hand when the pelvis was tilted backward. Therefore, although voluntary hip abduction was possible in a supine position, the patient showed hip flexion and excessive lumbar lordosis in the standing position, accompanied by hip adduction and incycloduction.

The patient presented knee flexion throughout the gait cycle. Due to the poor hip extension at the terminal stance, she gained propulsive force by enhancing the muscle activities of the ankle plantar flexor muscles. The forward swing of the lower limbs was achieved through the effort of rotating the pelvis, with the swung lower limb coming in contact with the other lower limb. The patient was able to walk without orthoses or walking aids. However, she complained of fatigue after walking continuously from the bedroom to the rehabilitation room (about 200 m), exhibiting poor endurance.

### 37-year-old woman

**Overview:** After graduating from high school and a vocational skills development center, the patient works as a clerical worker at a company.

She lives with her parents and drives to work independently. She received periodic rehabilitation at a medical institution until she was a senior high school student. She currently receives rehabilitation, such as stretching, at an orthopaedic institution once a week.

(Rt.Lt)			Before	After 3 weeks	After 7 weeks
ROM (°)	hip	extension	0/-5	10/10	10/10
		abduction	30/20	35/30	35/30
MAS	ankle	dorsal reflexion	0/5	10/15	10/15
	hip	abduction	1+/1+	1/1	1+/1
		extension	2/1+	1/1	1+/1
	ankle	dorsal reflexion	2/1+	1/1	1+/1
12 Step Hemiplegic Function Inspection					
MMT	hip	extension	-/-	2/2	2/2
		abduction	2/2	3/3	3/3
	knee	extension	3/3	4/4	4/4
	ankle	dorsal reflexion	-/-	2/3	3/3
Timed up and Go		clockwise	12.02	10.05	10.52
		counter clockwise	13.27	11.2	9.75
Gait	toe out angle	(°)	-5.9 ± 1.4/-3.9 ± 1.3	1.5 ± 1.9/4.3 ± 1.5	1.2 ± 2.3/3.9 ± 2.1
	stride width	(cm)	25 ± 2	25 ± 3	24 ± 2

	stride	(cm)	12 ± 3/4 ± 3	15 ± 4/10 ± 3	15 ± 2/10 ± 2
	cadence	(steps/min)	129 ± 3	136 ± 3	140 ± 4
	10m gait	(sec)	6.16	6.02	6.51

**Table 1:** Case 1; Physical therapy evaluation.

**Chief complaints:** “I want to be able to walk without falling” and “I want to be able to walk easily.”

**History:** Received muscle release operation on both sides of hip adductors and hamstrings during childhood and high school. Evaluation at admission (Table 2, Figure 2).

		(Rt.Lt)	Before	After 3 weeks	After 7 weeks
ROM (°)	hip	extension	-10°/-10°	0°/0°	0°/0°
		abduction	20°/15°	35°/30°	35°/30°
	ankle	dorsal reflexion	0°/-5°	5°/0°	5°/0°
MAS		hip	abduction	2/3	1+/1+
		extension	2/2	1+/1+	1+/1+
	ankle	dorsal reflexion	1+/1+	1/1	1/1
12 Step Hemiplegic Function Inspection			6/6	7/7	7/7
MMT	hip	extension	-/-	2/2	2/2
		abduction	-/-	3/3	3/3
	knee	extension	2/3	4/4	4/4
	ankle	dorsal reflexion	-/-	3/2	3/2
Timed up and Go			clockwise	13.52	8.79
		counter clockwise	12.02	8.21	9.86
Gait	toe out angle	(°)	2.5 ± 3.4/4.9 ± 2.6	5.1 ± 4.5/5.6 ± 4.5	5.4 ± 2.6/5.4 ± 3.2
	stride width	(cm)	9 ± 1	15 ± 1	13 ± 1
	stride	(cm)	40 ± 3/38 ± 2	30 ± 2/31 ± 1	32 ± 2/32 ± 1
	cadence	(steps/min)	27 ± 1	35 ± 1	33 ± 2
	10m gait	(sec)	9.66	9.31	9.22

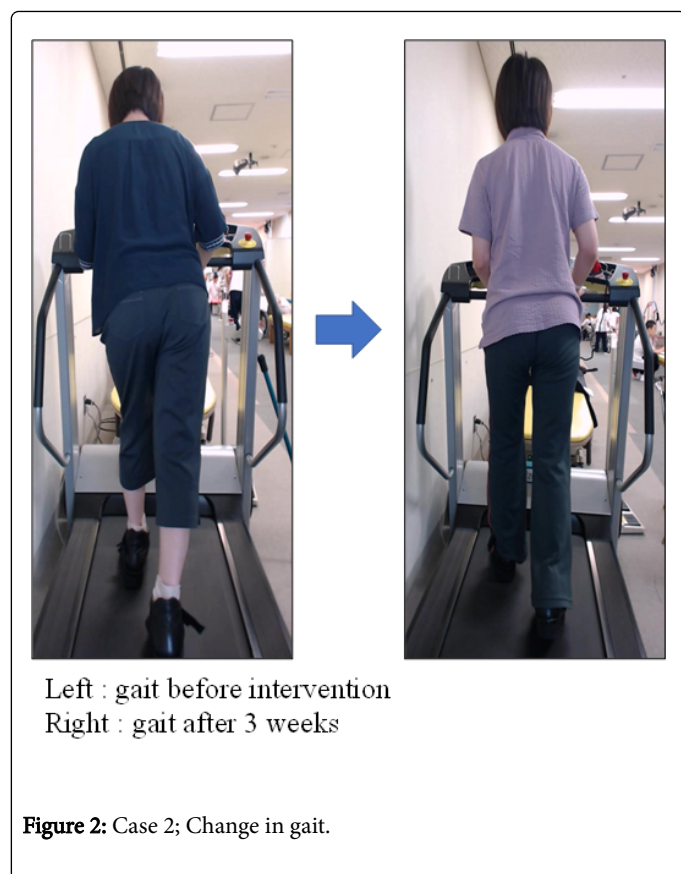**Table 2:** Case 2; Physical therapy evaluation.

No abnormalities were found in general biochemical findings. The patient wore shoe-type orthosis on both feet and walked using a T-cane in her right hand. MAS score was 2 for the right and 3 for the left hip adductor muscle. Although spasticity of the hamstrings was mild, excessive forward tilting of the pelvis and trunk due to hip adduction and incycloduction in the standing position necessitated compensative knee flexion in order to maintain proper posture. Spasticity of the ankle plantar flexor muscles was relatively mild for both sides.

Because the patient had to make her feet everted at the subtalar joint to maintain her heel contact on the ground, she exhibited pes planovalgus. The contraction of the gluteus maximus and gluteus medius on both sides is slightly palpable, leading to difficulty in voluntary hip extension, abduction, and abduction movement in flexion even in the gravity-assisted position. There is a significant

decrease of muscle output, especially in the left lower limbs, with a score of less than level 2 for the manual muscle test (MMT), even for hip extension with adequate isolated movements.

When walking, due to the low amount of activity in her hip extension muscles against the increased forward tilting of the trunk by adductor muscle spasticity, the patient had to enhance muscle activity in her hamstrings to apply deceleration and exhibited dynamic equinus by knee joint flexion. During the left loading response phase, due to weakness in the hip lateral rotators and knee extension muscles, she was unable to apply deceleration against rapid hip internal rotation and knee flexion and sometimes exhibited buckling.



During the mid-stance phase, due to forward tilting of the trunk and weak abduction muscles, she exhibited a significant

	Day 1	Day 2-6	Day 7	Day 8-12	Day 13
AM	(admission)	Intensive PT (60 min)	rest	Intensive PT (60 min)	evaluation after treatment
PM	pre-treatment evaluation	low frequency rTMS (40 min)		low frequency rTMS (40 min)	(discharge)
		Intensive PT (60 min)		Intensive PT (60 min)	

**Table 3:** Combination protocol of rTMS and intensive PT (The same schedule will be held for another week in case of 3 weeks hospitalization).

### Clinical Course/Results

The two patients completed the hospitalization protocol without adverse events, such as convulsion, nausea, and headaches. After the first or the second treatment, both patients began to reduce spasticity in the proximal muscles, including extension muscles followed by the reduction of spasticity in distal muscles, such as those of the lower legs and feet. At the same time, the patients complained of weakness in the lower limbs, such as, "It's difficult to strain the leg," or "My legs are limp," objectively exhibiting increased flail gait. However, their motor function improved during the repeated exercise therapy, as shown in Table 2, with strengthening of the weakness.

In patient 1, as shown in Table 1, MAS score of hip flexor muscles on both sides and of the right ankle plantar flexor muscle were reduced and the restricted range of motion was alleviated to confirm the heel contact. Increased foot load was observed from the midfoot to rearfoot

Trendelenburg's sign on both sides and maintained support by knee locking. Thus, she exhibited increased dynamic equinus by avoiding a load on the left lower limb, presented with a rush-like gait, and fell several times a day due to the inability to maintain toe clearance.

### Combination protocol of rTMS and intensive PT

We explained the purpose to the two patients and obtained their consent for publication.

Patient 1 and patient 2 received inpatient treatment for 2 weeks (13 days) and for 3 weeks (19 days), respectively (Table 1,2). During the period of hospitalization, low-frequency rTMS using a double cone coil and intensive PT were performed for 60 minutes twice daily (Table 3).

### TMS protocol

a) Magnetic stimulation coil: double cone coil (Cool D-B80 Butterfly Coil, Mag Venture), b) Stimulation frequency: 1 Hz, c) Coil application site: cranial midline, d) Stimulation time: 40 minutes/session (2,400 pulses/session).

### Intensive PT program

With 60 minutes per session, PT consisted of stretching the spastic muscles, incremental muscle training of trunk and lower limb muscles, repeated standing practice, walking exercise, ergometer and so on. A gait analysis treadmill (FDM-T, Inter Reha Co., Ltd) was used for gait evaluation to calculate the foot pressure distribution and parameters in the gait cycle.

by foot pressure distribution analysis (Figure 1). In addition, increased activities of the abdominal muscles enabled voluntary backward tilting of the pelvis in standing position, leading to adequate hip extension at the terminal stance with increased length of stride (Table 1). Although there was no change in stride width, reduction in the endeavored forward swing of the lower limbs by pelvis rotation enabled an increased toe-out angle on both sides (Table 1), leading to no contact between the lower limbs. Achievement of efficient gait also alleviated complaints of fatigue. Although gait improvement did not increase gait speed, because the patient gained propulsive force by compensating for the lack of hip joint extension with ankle plantar flexion prior to the combined therapy, the required time for the Timed Up and Go Test (TUG), which requires smooth motion in complicated movements, such as rising and turning, was reduced for both clockwise and counter clockwise turning (Table 1).

The patient was aware of the changes in her condition, such as, “I have become able to touch my heels to the ground,” “I have become able to walk without hitting one leg against the other,” and “It took me less time to move.” In particular, there was a response that although the patient had received a lot of rehabilitation so far, this was the first time she was able to achieve such a degree of improvement over a short period of time.

For patient 2, MAS score of the hip adductor muscles was reduced, as shown in Table 2. The patient became able to perform voluntary hip abduction and abduction movement in flexion, both of which had been difficult prior to the intervention. Also, her muscular strength by MMT improved to level 3 on both sides. In her gait, hip adduction and deceleration in internal rotation direction became possible and the alleviated Trendelenburg's sign increased her stride width (Table 2). The patient's buckling was resolved by the improvement in left kneel extension muscle strength as well as hip abductor muscle strength. Because adequate loading on the left lower limb became possible, she secured toe clearance, alleviated the rush-like gait, and no longer falls while walking. During the treadmill walking for patient 2 prior to the therapy, her upper body was fixed by the support of upper limbs, while the lower limb was somewhat passively extended by the forward trunk inclination due to the backward movement of the walking passage (running belt) on the treadmill. Therefore, as for patient 1, the trunk extension enabled a significant reduction of time in TUG for both clockwise and counterclockwise turning (Table 2), although there was a reduced length of stride (Table 2).

The patient was aware of the changes in her condition, such as, “My body stopped swaying from side to side” and “I no longer fear falling.” In her office, the patient was told, “Your posture has improved,” and “Your gait became better.”

## Discussion

The combined use of low-frequency rTMS and intensive PT is expected to be effective for gait improvement in adult patients with spastic diplegia.

For the motor function and movement capability of adult patients with cerebral palsy (CP), individual patients have learned their own method of movement through limited experience with their restricted physical function during the process of growth and development. Also, individual patients have their own movement style that is dynamically fixed. Under these conditions, treatment in adulthood is believed to be less likely to exert significant improvement in motor function and movement capabilities compared to childhood. However, both patients demonstrated significant improvements in physical function, movement ability, and gait with this combined therapy over a few weeks. Remarkably, both patients alleviated spasticity in the lower limbs early after the implementation of rTMS and became able to perform isolated movements such as hip abduction and ankle joint dorsiflexion. Therefore, we consider these facts an indication that the result of this study, which shows a significant improvement in declining physical function due to aging or disuse, is not merely a result of intensive physical therapy.

In addition, the effect of rTMS is reported not to be sustained over a long period of time [4]. However, the physiotherapy findings and gait ability of the two patients were maintained even 4 weeks after being discharged. From the above, we believe that neuromodulation obtained by rTMS implementation will be carried over for a longer period of time, by combined use with rehabilitation.

Kakuda et al. position rTMS as a means of intervention-“preconditioning and neural plasticity modulation” of rehabilitation-to induce plastic changes in the brain [5].

The two patients in the current study alleviated spasticity and improved voluntary movement in the lower limbs at an early stage after the implementation of rTMS. Also, both patients demonstrated improved physiotherapy findings and gait ability by combined use with rehabilitation.

Motor areas of lower limbs are more adjacent to each other, the left and right, in the deep part inside of the frontal lobe compared to those of the upper limbs. In addition, for the nerve fibers that are responsible for the lower limb motor function, only 70% to 80% are from the opposite hemisphere, while the remaining 20% to 30% are from the same hemisphere without crossing [6]. As the two patients in the current study have spastic diplegia, an approach to inhibit the activity of the non-lesional hemisphere, which is a treatment for upper limb paresis by stroke, could also inhibit the recovery of the lower extremity motor function. Therefore, we intended to stimulate and activate the motor areas of the lower limbs simultaneously in both hemispheres using low-frequency rTMS with a double cone coil. We assume that if the spasticity of both lower limbs were to be simultaneously reduced due to the suppression of spinal cord excitability through the stimulation and activation of the bilateral cerebral cortex, compensative support obtained from the spasticity may be temporarily impaired, as in the present two patients. Therefore, we regard the enhancement of weakened muscles and active motor learning based on the assessment of individual patients under reduced spasticity to be important for the sustained improvement of voluntary movement and gait capability.

In other words, as with rTMS treatment for upper limb paralysis, the treatment concept of “enhancing neuromodulation of the brain with rTMS and conducting intensive rehabilitation” is also useful for adult patients with CP spastic diplegia.

When considering that CP spastic diplegia in adult patients features a non-progressive lesion of the brain and has functional deterioration correlated with aging, an approach to improve functions such as muscle strengthening is not commonly prioritized. Therefore, we consider that the results obtained from the two patients in the present study to be significant in the physical therapy of adult CP patients.

As a challenge of the combined therapy, we believe that it is necessary to standardize the specifics of the intensive PT program to be used together. In addition, for patients with CP who exert an effort while performing gait due to spasticity, as with the two patients in the present study, gait analysis by treadmill or gait speed analysis for a short length, such as 10 m, is insufficient for gait ability analysis. Therefore, we will continue the investigation using the six-minute walk test, physiological cost index (PCI) and others. Further, we will conduct a randomized controlled trial to demonstrate the evidence for the usefulness of this combination therapy.

## Conclusion

Combination therapy of low-frequency rTMS and intensive PT was performed for two hospitalized adult patients with CP spastic diplegia. Both patients showed reduced spasticity of lower limbs, improved voluntary movement, and improved gait. The combined use of low-frequency rTMS and intensive PT is expected to be effective for gait improvement in adult patients with spastic diplegia.

## Conflict of Interest

No conflict of interest was declared by the authors.

## References

1. Gajdosik CG, Cicirello N. Secondary conditions of the musculoskeletal system in adolescents and adults with cerebral palsy. *Phys Occup Ther Pediatr* 21: 49-68.
2. Carter DR, Tse B (2009) The pathogenesis of osteoarthritis in cerebral palsy. *Dev Med Child Neurol* 51 Suppl 4: 79-83.
3. Theroux MC, DiCindio S (2014) Major surgical procedures in children with cerebral palsy. *Anesthesiol Clin* 32: 63-81.
4. Abo M, Kakuda W, Momosaki R, Harashima H, Kojimaet M, et al. (2014) Randomized, multicenter, comparative study of NEURO versus CIMT in poststroke patients with upper limb hemiparesis: the NEURO-VERIFY Study. *Int J Stroke* 9: 607-612.
5. Kakuda W, Abo M, Sasanuma J, Shimizu M, Okamoto T, et al. (2016) Combination Protocol of Low-Frequency rTMS and Intensive Occupational Therapy for Post-stroke Upper Limb Hemiparesis: a 6-year Experience of More Than 1700 Japanese Patients. *Transl Stroke Res* 7: 172-179.
6. Kakuda W, Abo M, Kobayashi K, Momosaki R, Yokoi A, et al. (2011) Anti-spastic effect of low-frequency rTMS applied with occupational therapy in post-stroke patients with upper limb hemiparesis. *Brain Inj* 25: 496-502.
7. Niimi M, Hashimoto K, Kakuda W, Miyano S, Momosaki R, et al. (2016) Role of Brain-Derived Neurotrophic Factor in Beneficial Effects of Repetitive Transcranial Magnetic Stimulation for Upper Limb Hemiparesis after Stroke. *PLoS One* 11: e0152241.