

## Efficacy of Imiquimod Cream Administered Intraperitoneally for Ovarian Metastases in Colorectal Cancer

Yi-Hao Lin, Fu-Chieh Chu, Hsiu-Huei Peng, Hsuan Weng and Cheng-Tao Lin\*

Department of Obstetrics and Gynecology, Chang Gung Memorial Hospital, Linkou Medical Center, Chang Gung University College of Medicine, Taoyuan, Taiwan

\*Corresponding author: Cheng-Tao Lin, Department of Obstetrics and Gynecology, Chang Gung Memorial Hospital, Linkou Medical Center, Chang Gung University College of Medicine, Taoyuan, Taiwan, Tel: +886-975365886; Fax: +886-3-3288252; E-mail: [51424@cgmh.org.tw](mailto:51424@cgmh.org.tw)

Received date: November 02, 2016; Accepted date: December 14, 2016; Published date: December 20, 2016

Copyright: © 2016 Lin Y, et al. This is an open-access article distributed under the terms of the Creative Commons Attribution License, which permits unrestricted use, distribution, and reproduction in any medium, provided the original author and source are credited.

### Abstract

In this case report, we sought to determine the efficacy of intraperitoneal Imiquimod cream for the treatment of persistent ovarian metastases in colorectal cancer after Avastin-based chemotherapy failure. Topical Imiquimod cream is an immune response modifier. It could trigger skin Langerhan cells (naïve dendritic cells) as the priming responsive cell type and initiate a strong Th1-switched anti-tumor cellular immune response. This is a 50-year-old woman with rectal cancer with liver, lung, left adrenal gland and ovarian metastasis, and pelvic carcinomatosis. CEA level decreased after the initial optimal debulking surgery and 12 cycles of chemotherapy. However, CEA level persistently elevated, and CT scan showed progressed carcinomatosis, malignant ascites and diffused metastasis. After intraperitoneal immunomodulatory therapy (IMT) administration with intraperitoneal Interleukin-2 mix Thymoxin on Day 1, and intraperitoneal Imiquimod cream (5% 250 mg in normal saline 2 ml) on Day 2, the amount of drainage ascites gradually decreased, and CEA level dramatically decreased after IMT.

### Introduction

Most existing vaccines and immunomodulatory adjuvants are administered via subcutaneous or intramuscular injection due to the consideration of drug safety. The challenge of immunization is to provide vaccines that ensure enhancement of anti-cancer effects in elderly or immunocompromised patients. Vaccines containing tumor-associated antigens and adjuvants together trigger in situ antigen presentation in cells. In such efforts, the safety of immunomodulatory adjuvants is always the limitation factors.

Topical Imiquimod cream (Trade name: Aldara 5% 250mg) is an immune response modifier, toll-like receptor 7 (TLR7) agonist for the treatment of anogenital warts proved by the US Food and Drug Administration [1]. Imiquimod cream could also eliminate cervical residual intraepithelial neoplasia after conization [2]. It could trigger skin Langerhan cells (naïve dendritic cells) as the priming responsive cell type and initiate a strong Th1-switched anti-tumor cellular immune response.

The mechanism for the eradication of genital verrucous lesions with Imiquimod may involve the induction of both innate and cellular immunity [3-5]. Anti-viral activity may be stimulated through the induction of cytokines, such as Interferon-alpha, tumor necrosis factor-alpha, and interleukins. It is known that Imiquimod activates immune cells through the TLR7, commonly involved in pathogen recognition, on the cell surface. There is evidence suggesting that Imiquimod, when applied to skin, cervix and vagina, can lead to the activation of naïve dendritic cells, which subsequently migrate to local lymph nodes; activating the adaptive immune system. Other cell types activated by Imiquimod include NK cells, macrophages, and B-lymphocytes.

In the United States, approximately 20 percent of patients with colorectal cancer (CRC) have metastatic (stage IV) disease at the time of diagnosis [6-9]. The incidence of ovarian metastases in patients with

CRC is around 1 to 14 percent. They are more common in premenopausal as compared to postmenopausal women, and with colonic rather than rectal primaries. Ovarian metastases represent a poor prognostic factor in colorectal cancer, but complete resection may improve survival. A systematic review of cytoreductive surgery and intraperitoneal chemotherapy for peritoneal dissemination of CRC showed median survival varied from 13 to 29 months, and five-year survival rates ranged from 11 to 19 percent.

In this case report, we sought to determine the efficacy of intraperitoneal Imiquimod cream for the treatment of persistent ovarian metastases in colorectal cancer after failure of Avastin-based chemotherapy.

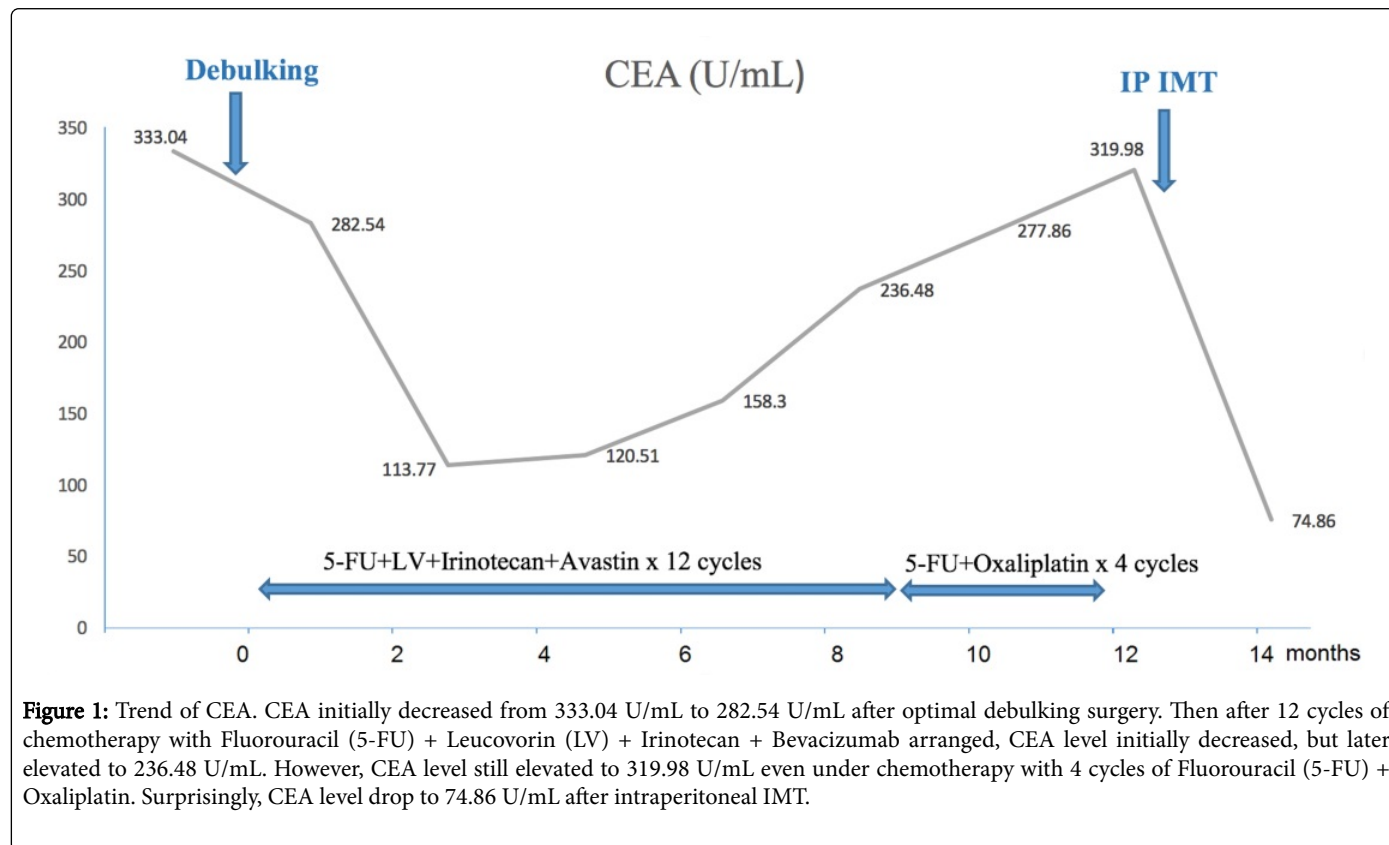
### Case Report

A 50-year-old woman had a past history of duodenal ulcer and appendicitis, status post appendectomy 35 years ago, who had complained about progressive diffused abdominal distension. Initial CT scan showed suspected rectal cancer with liver, lung, left adrenal gland and ovarian metastasis, and pelvic carcinomatosis, iT3N1bM1b. Initial tumor marker showed CA-199: 10266 U/mL and CEA: 333.04 U/mL. Therefore, debulking surgery with end colostomy was arranged later. The final pathology report showed rectal moderately differentiated adenocarcinoma with liver, left lower lung, left adrenal gland, and ovarian metastasis T4aN1bM1b.

The next day after the debulking surgery, she received her 1st course of immunomodulatory therapy (IMT) administered by subcutaneous injection. This immunomodulatory therapy consisted of Picibanil (OK-432: TLR4 agonist) by subcutaneous injection on Day 1, Interleukin-2 on Day 2, and Interferon-alpha on Day 3. She also received the 2nd course of IMT with the same regimen one week later after the debulking surgery.

Afterwards, she was transferred to the medical oncologist for adjuvant chemotherapy, 12 cycles of chemotherapy with Fluorouracil (5-FU) + Leucovorin (LV) + Irinotecan + Bevacizumab over the duration of eight months. Tumor marker with CEA decreased from

333.04 U/mL to 113.77 U/mL initially, but elevated to 236.48 U/mL after the 11th cycle of chemotherapy (Figure 1). Therefore, we shifted the chemotherapy regimen to Fluorouracil (5-FU) + Oxaliplatin, 4 cycles arranged over the duration of two months.



**Figure 1:** Trend of CEA. CEA initially decreased from 333.04 U/mL to 282.54 U/mL after optimal debulking surgery. Then after 12 cycles of chemotherapy with Fluorouracil (5-FU) + Leucovorin (LV) + Irinotecan + Bevacizumab arranged, CEA level initially decreased, but later elevated to 236.48 U/mL. However, CEA level still elevated to 319.98 U/mL even under chemotherapy with 4 cycles of Fluorouracil (5-FU) + Oxaliplatin. Surprisingly, CEA level drop to 74.86 U/mL after intraperitoneal IMT.

	Before surgery	1 month after OP	3 month	6 month	7 month	8 month	10 month	11 month Before IMT	12 month After IMT
CA-199 U/mL	10266	7182	4670	4947	6706	7503	7210		2402
CEA U/mL	333.04	282.54	113.77	120.51	158.3	236.48	277.86	319.98	74.86

**Table 1:** The trend of tumor maker.

However, she complained about progressed ascites 11 months after the initial debulking surgery. CT scan showed newly onset pelvic carcinomatosis with massive ascites and progressed disease of metastasis over the left lower lung, liver, and left adrenal gland. Then the patient was admitted to our hospital for abdominal paracentesis and palliative care. Tumor marker with CEA elevated to 319.98 U/mL, so the patient requested further IMT. Therefore, intraperitoneal immunotherapy was suggested with the purpose of linking innate and adaptive immune cells. We prescribed intraperitoneal Interlukin-2 mix Thymoxin on Day1, and intraperitoneal Imiquimod cream on Day 2 (Imiquimod cream 5% 250mg in normal saline 2 ml). After intraperitoneal IMT was administered, the amount of drainage ascites gradually decreased and CEA decreased from 319.98 U/mL to 74.86 U/mL (Table 1). The iRAEs (immune-related adverse effect) in our case is grade 1 to grade 2.

We also monitored her ascites immune risk profile before and after the intraperitoneal IMT (Table 2). We monitored the immune risk

profiles (IRP) including CD3 (T-cell), CD19 (B-cell), CD25, CD4 (T-cell), CD8 (T-cell), NK, CD11b (immature dendritic cell), HLA-DR (major histocompatibility complex class II: MHC II) and CD28 (co-stimulatory marker) in intraperitoneal local and/or systemic circulation. First, we compared the IRP change in ascites before and after the intraperitoneal IMT (Table 2). We realized that intraperitoneal IMT can trigger host immunogenic potency such as elevated CD4/CD8 ratio to 2.6 fold (from 0.77 to 1.99), elevated CD4<sup>+</sup> T cell to 4.2 fold (from 4.84 to 20.4), elevated CD4<sup>+</sup> HLA-DR<sup>+</sup> T cells to 5.3 fold (from 3.16 to 16.8), while enhanced phagocytosis cells' marker CD11b<sup>+</sup> immature dendritic cells elevated 2.1 fold (from 21.4 to 45.5) after the intraperitoneal procedure. However, NK cells declined from 65.2% to 40.4%. This result showed an increasing trend in local immunogenicity and efficient anticancer response. Intraperitoneal IMT may trigger a "danger signal" to mimic signal 0 and chaperone signal 1. We found out that CD28 as "signal 2" enhanced 3.7 fold (from 7.86 to 29.1). In healthy patients, activation of

the adaptive immune system can not render autoimmune disease. Though activation of the adaptive immune system can enhance signal 2 to mimic CD28 co-stimulatory molecules under controlled regulation via central and/or peripheral tolerant immune system, the percentage of immune cells with CD28<sup>+</sup> should be higher than the threshold. The stress caused by patients who received surgical procedures facilitate immune signal 2 [10].

	Before IMT (%)	After IMT (%)
T-CD3	20.6	65.9
B-CD19	0.4	0.26
CD25	1.18	2.7
CD4 + CD25 +	0.92	2.1
HLA - DR +	46.1	82.4
CD4 + DR +	3.16	16.8
CD11b	21.4	45.5
CD8 + CD11b	12.2	17
CD4 T Cell	4.84	20.4
CD8 T Cell	6.26	10.3
CD4/CD8	0.77	1.99
NK-Cell	65.2	40.4
CD28	7.86	29.1
CD8 + CD28 +	2.38	4.58
CD8 + CD28-	29.3	17.3
NKT	29.3	49.9

**Table 2:** Comparison of immune risk profiles (IRP) in ascites before and after the intraperitoneal immunomodulatory therapy (IMT).

Therefore, we hypothesize danger signals alone would not be enough. It must be incorporated with immunomodulatory therapy, including endogenous and exogenous adjuvants, to form an effective vaccine under *in vivo* condition. From our investigation, we can ensure proof of principal and concept to trigger *in situ in vivo* antigen-presenting cells to perform timely and complete host immunosurveillance to link innate and adaptive cells. Completely effective immunity include cooperation between both cellular mediated immunity (CMI) and/or humoral mediated immunity (HMI). Efficient T-cell activation depends on signals delivered through the antigen-specific T-cell receptor (signal 1) and costimulatory receptors on T cells (signal 2).

## Discussion

Topical Imiquimod cream (Trade name: Aldara 5% 250mg), approved by the US Food and Drug Administration, is a TLR7 agonist used to treat skin or vulva virus related lesions. Small-molecular Aldara cream had demonstrated a vivid interest in cancer therapy that is being used as a vaccine adjuvant in immunotherapy. Skin Langerhan cells (naïve dendritic cells) are the priming responsive cell type and initiate a strong Th1-switched anti-tumor cellular immune response.

We have published Imiquimod cream to eliminate cervical residual intraepithelial neoplasia after cervical conization. We present this case via intraperitoneal immunomodulatory agents with Aldara cream to elicit promising host immunosurveillance anticancer response.

Vaccines have many beneficial effects in combating ovarian cancer through Bevacizumab (Avastin) since its approval by the 2010 NCCN guideline. They have also proved to be effective cancer treatments by Avastin combined immunomodulatory therapy. Therefore, we combined various TLR agonists to elicit excellent anticancer therapy. Although vaccines are widely considered safe via monotherapy, we combined dual or tripartite adjuvants to augment host immunosurveillance with limited adverse effects. We have experienced handling Aldara cream in the elimination of vulva, vaginal and cervical lesion. Imiquimod (5% cream) has been shown to be safe and effective in the treatment of genital warts caused by low-risk HPV infections [11,12]. The mechanism for the eradication of genital verrucous lesions with Imiquimod may involve the induction of both innate and cellular immunity [12]. Anti-viral activity may be stimulated through the induction of cytokines, such as interferon-alpha, tumor necrosis-alpha, and interleukins [12]. It is known that Imiquimod activates immune cells through the TLR7, commonly involved in pathogen recognition on the cell surface. Cells activated by Imiquimod via TLR7 secrete cytokines such as IFN-alpha, IL-6 and TNF-alpha. There is evidence suggesting that Imiquimod, when applied to skin, cervical and vaginal, can lead to the activation of naïve dendritic cells, which subsequently migrate to local lymph nodes to activate the adaptive immune system. Other cell types activated by Imiquimod include NK cells, macrophages and B-lymphocytes [12,13]. In this retrospective study, we sought to determine the efficacy and toxicity of Imiquimod cream for the treatment of persistent cancer metastatic ovarian cancer after Avastin-based chemotherapy failure. The weakness of this study is small case numbers. However, our case highlights the possible clinical application of Imiquimod cream in the case of ovarian metastases in colorectal cancer.

## Acknowledgment

The study was supported by the following grants: CMRPG3D0051-3 provided by Chang-Gung University Hospital, Taoyuan, Taiwan.

## Disclosure

All authors do not have any existing or known future financial relationships or commercial affiliations to disclose.

## References

1. Ahn CS, Huang WW (2014) Imiquimod in the treatment of cutaneous warts: an evidence-based review. *Am J Clin Dermatol* 15: 387-399.
2. Lin CT, Qiu JT, Wang CJ, Chang SD, Tang YH, et al. (2012) Topical imiquimod treatment for human papillomavirus infection in patients with and without cervical/vaginal intraepithelial neoplasia. *Taiwan J Obstet Gynecol* 51: 533-538.
3. Xiong Z, Ohlfest JR (2011) Topical imiquimod has therapeutic and immunomodulatory effects against intracranial tumors. *J Immunother* 34: 264-269.
4. Fehres CM, Bruijns SC, van Beelen AJ, Kalay H, Ambrosini M, et al. (2014) Topical rather than intradermal application of the TLR7 ligand imiquimod leads to human dermal dendritic cell maturation and CD8<sup>+</sup> T-cell cross-priming. *Eur J Immunol* 44: 2415-2424.
5. Schön MP, Schön M (2008) TLR7 and TLR8 as targets in cancer therapy. *Oncogene* 27: 190-199.

6. Siegel RL, Miller KD, Jemal A (2016) Cancer statistics, 2016. *CA Cancer J Clin* 66: 7.
7. Segelman J, Flöter-Rådestad A, Hellborg H, Sjövall A, Martling A (2010) Epidemiology and prognosis of ovarian metastases in colorectal cancer. *Br J Surg* 97: 1704-1709.
8. McCormick CC, Giuntoli RL 2nd, Gardner GJ, Schulick RD, Judson K, et al. The role of cytoreductive surgery for colon cancer metastatic to the ovary. *Gynecol Oncol* 105: 791-795.
9. Rayson D, Bouttell E, Whiston F, Stitt L (2000) Outcome after ovarian/adnexal metastectomy in metastatic colorectal carcinoma. *J Surg Oncol* 75: 186-192.
10. Lin CT, Wang CN, Lai CH (2013) Immunotherapy for advanced or relapsed cervical cancer. *Gynecology and Minimally Invasive Therapy* 2: 3-7.
11. Tyring SK, Arany I, Stanley MA, Tomai MA, Miller RL, et al. (1998) A randomized, controlled, molecular study of condylomata acuminata clearance during treatment with imiquimod. *J Infect Dis* 178: 551-555.
12. Edwards L, Ferenczy A, Eron L, Baker D, Owens ML, et al. (1998) Self-administered topical 5% imiquimod cream for external anogenital warts. HPV Study Group. *Human PapillomaVirus. Arch Dermatol* 134: 25-30.
13. Chuang CM, Monie A, Hung CF, Wu TC (2010) Treatment with imiquimod enhances antitumor immunity induced by therapeutic HPV DNA vaccination. *J Biomed Sci* 17: 32-40.