

Endodontic Management of a Young Patient with Avulsion and Root Fracture: A Case Report with 4 Years Follow-up

Hamid Jafarzadeh

Department of Endodontics, Dental Research Center, Faculty of Dentistry, Mashhad University of Medical Sciences, Mashhad, Iran.

Abstract

Avulsion and root fractures are complications may be seen after a traumatic accident. These should be diagnosed and treated as soon as possible because the time elapsed between the trauma and start of the treatment is considered as the most important factor in the prognosis. All treatment protocols should be directed toward the management of the pulp and periodontal ligament. The present case report reviews a 22-year-old male patient which was visited with 5 hours delay after accident and avulsion of right central incisor. The avulsed tooth soaked in 2.4% fluoride solution for 20 minutes. Extra-oral root canal treatment was performed and it was immediately replanted. Anterior maxillary teeth were splinted by a semi-rigid splint. After 10 days, an intra-oral sinus tract was observed on the oral mucosa of the left central incisor, its tracing revealed a root fracture on this tooth. The coronal section of this tooth was endodontically treated. Four years follow-up revealed no radiographic or clinical signs and symptoms.

Key Words: Avulsion, Case report, Dental trauma, Root fracture

Introduction

Avulsion or exarticulation is defined as complete extrusion or displacement of a tooth from its socket. For endodontic treatment of these cases, a complete medical and dental history in addition to the complete clinical and radiographic examination is mandatory. All treatment protocols should be directed toward the management of the pulp and Periodontal Ligament (PDL) [1].

Another complication may be seen after a traumatic accident is root fracture which should be diagnosed by peri apical or occlusal radiographs. This kind of injury is relatively infrequent, occurring in $\leq 3\%$ of all traumatized teeth. In these cases, the coronal section may be displaced to a varying degree; however, the apical segment usually has no displacement and remains vital [2].

This case report describes the endodontic management of a young patient with avulsion and root fracture with 4 years follow-up.

Case Report

A 22-year-old male patient was referred to the Department of Endodontics of Mashhad Faculty of Dentistry for the management of traumatic accident. Due to the car accident at 8 o'clock, avulsion of maxillary right central incisor had been occurred. The avulsed tooth had been placed in tap water at 10 o'clock. The time of dental visit was 13. The patient had no pain and the patient's medical history was non-contributory.

In clinical examination (*Figure 1*), the socket of right central incisor was empty with no bleeding. There was a complicated crown fracture on maxillary left central incisor with a small exposure. The mobility of all anterior maxillary teeth was normal. No tenderness in palpation or percussion in these teeth was present. Because the time saving is very important in these cases, the avulsed tooth soaked in 2.4% fluoride solution (DibaDent, Tehran, Iran) for 20 minutes before radiographic examination.

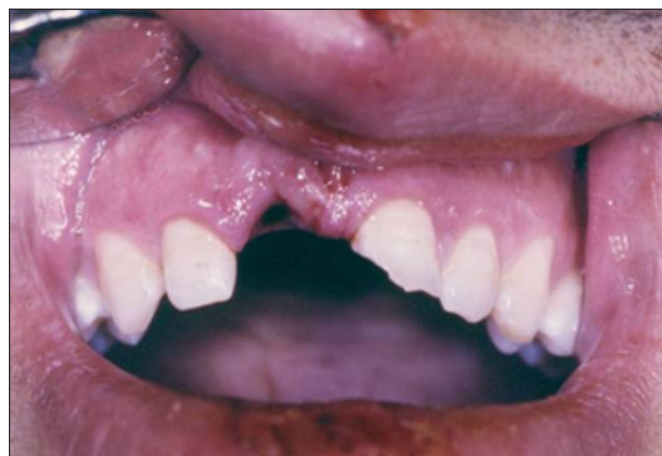

Figure 1. Initial photograph indicating the free space due to avulsion.

In radiographic examination (*Figure 2*), there was an empty socket on the right side with no other radiographic sign. Also, the radiographs of the opposite arch and the lip soft tissues were taken which showed no abnormality.

Since there was no possibility for preserving the vitality of the pulp tissue and PDL cells, extra-oral root canal treatment was performed on the right central incisor. A conventional access opening was made by using a diamond fissure bur (D & z, Berlin, Germany). The working length was established by a K-file No. 35 (Maillefer, Dentsply, Switzerland), the root canal was prepared by step-back technique and application of No. 3 and 4 gates-glidden drills (Maillefer, Dentsply, Switzerland) under copious irrigation with 5.2% sodium hypochlorite. The preparation was ended by K-file No. 80 (Maillefer, Dentsply, Switzerland) and the canal was dried by sterile paper points (AriaDent, Tehran, Iran). Then, canal was obturated by lateral condensation technique with gutta-percha (AriaDent, Tehran, Iran) and AH26 sealer (Dentsply, De Trey, Germany) and then Cavit (ESPE, Seefeld, Germany) was applied as temporary restoration of the cavity.

After completion of endodontic treatment and rinsing the root surface by normal saline, it was replanted immediately (in 20 minutes) (*Figure 3*). Also, because of the pulpal exposure of the left central incisor, a cervical pulpotomy was performed for it. For this purpose, the patient received local anesthesia of 2% lidocaine with 1: 100,000 epinephrine. Under rubber dam isolation, the access opening was made by using a diamond fissure bur (D & z, Berlin, Germany) and cervical pulpotomy was performed. The pulp chamber was irrigated by normal saline and dried with sterile cotton pellets and then, Cavit (ESPE, Seefeld, Germany) was applied as temporary restoration of the cavity. After completion of this procedure, the anterior maxillary teeth were splinted by a semi-rigid splint using 0.6 mm orthodontic wire and resin composite.

After 10 days, patient was revisited. In this appointment, an intra-oral fistula sinus tract was observed on the oral mucosa of the left central incisor. The tracing by a #25 gutta-percha (AriaDent, Tehran, Iran) revealed that there is a root fracture on this incisor; the coronal section had been necrotized (*Figure 4*) so we decided to treat the coronal section of this tooth. After removing the temporary restoration, a complete

mechanical and chemical debridement of the coronal section was performed. Firstly, the working length was established by a K-file No. 70 (Maillefer, Dentsply, Switzerland), the root canal was prepared by step-back technique and application of No. 4 and 5 gates-glidden drills (Maillefer, Dentsply, Switzerland) under copious irrigation with 5.2% sodium hypochlorite. The preparation was ended by K-file No. 110 (Maillefer, Dentsply, Switzerland) and the canal was dried by sterile paper points (AriaDent, Tehran, Iran) and calcium hydroxide paste (Produits Dentaires S.A, Switzerland) was inserted in this part of the canal. After 48 hours, the calcium hydroxide paste was remove by using mechanical instrumentation and 5.25% sodium hypochlorite and then, the obturation of the canal by using MTA (ProRoot, Dentsply, USA) was performed (*Figure 5*). For placing the MTA, the special carrier (MEDECY, Roma, Italy) was used. The restorative treatment was performed after one week by a specialist (*Figure 6*).

Four years follow-up revealed no radiographic or clinical signs and symptoms (*Figure 7*). The mobility of both the incisors was normal.

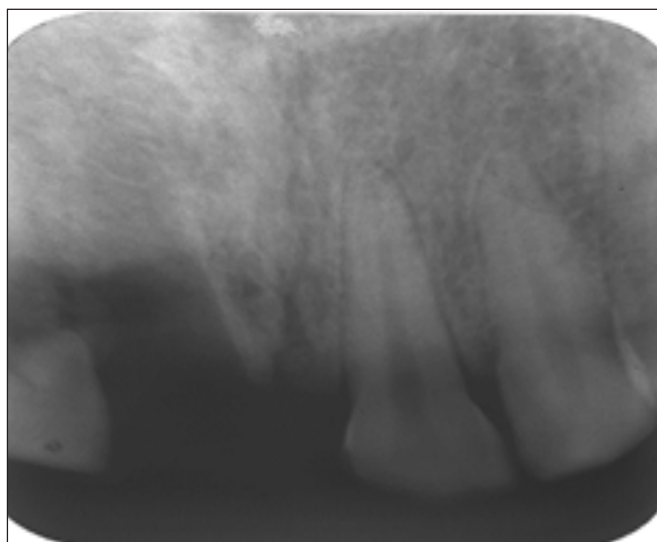


Figure 2. Initial radiograph indicating the empty socket of right central incisor and no sign in left central incisor.

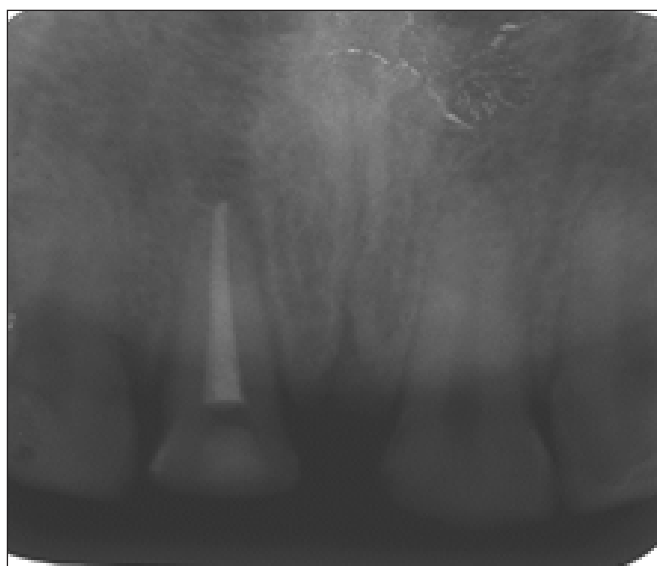


Figure 3. Replantation of the endodontically treated avulsed tooth.

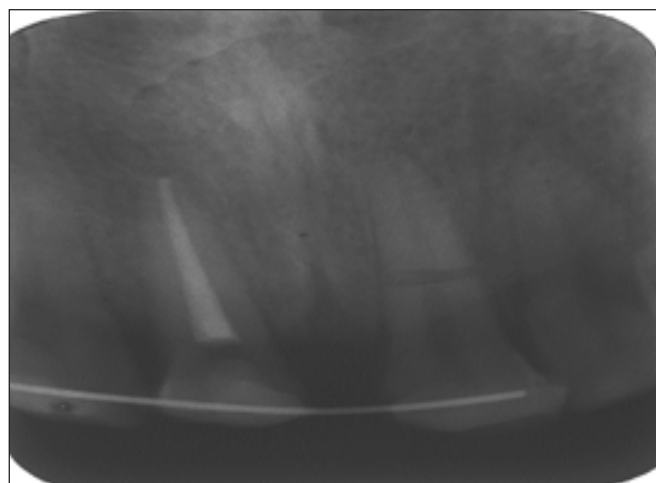


Figure 4. 10 days follow-up radiograph indicating the root fracture of left incisor.

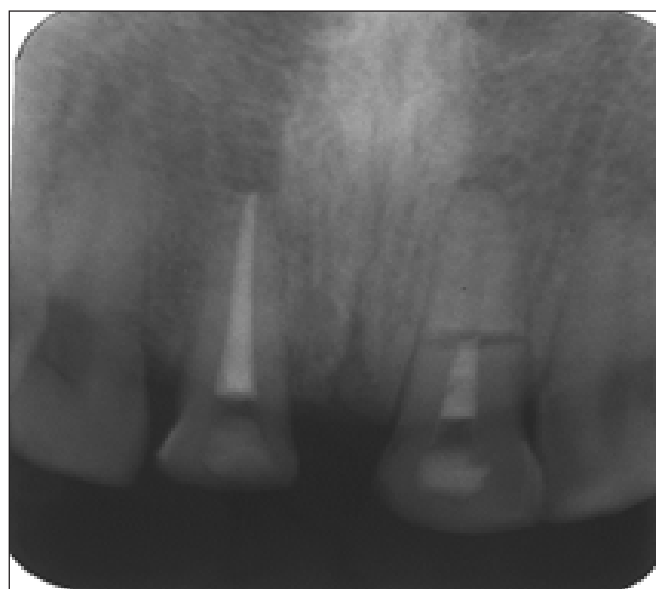

Figure 5. MTA plug in left incisor.

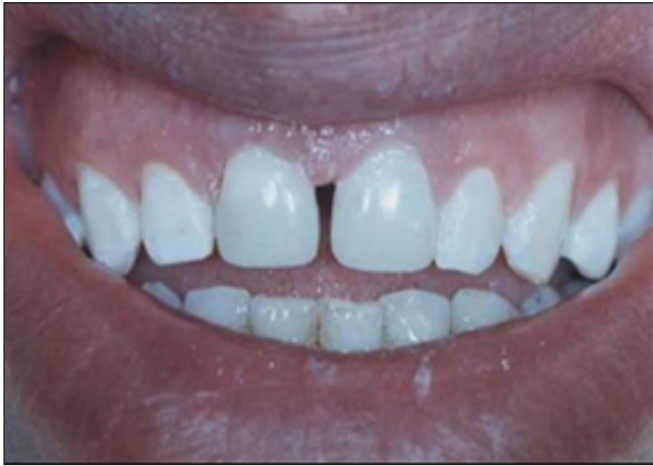

Figure 6. Clinical view after restorative treatment.

Discussion

The time out of the socket, transport medium, treatment of the root surface, kind and duration of splinting, and endodontic treatment are important factors affecting the prognosis of avulsed cases; however, the time elapses between the accident and replantation is the most important factor. The incidence of replacement root resorption may be increased with long extra-oral time [1,3]. In the present case, although the extra-oral time was about 5 hours, no resorption was seen after 4 years follow-up. This can be considered as a document for good prognosis even in delayed replantations.

When an avulsed tooth has been remained outside the mouth for a long time without a suitable transport medium, we can assume that PDL cells are necrotic, so in these cases, the root surface should be primarily treated with sodium fluoride solution. The rationale for this procedure is that the incorporation of fluoride into the cementum may increase its resistance to resorption [4]. This procedure was performed for the present case which may be a factor helped the tooth surface not be resorbed.

Endodontic treatment may not be necessary in root fractures where there is no mobility of the coronal part. It has been reported that 31% of the root fractures were identified coincidentally at subsequent radiographic examinations [5]. A careful radiographic examination for diagnosis of the root fractures is very important. Because a fracture may be oblique, a periapical radiograph may miss its presence so taking at least three radiographs with angle of 45, 90, and 110 degrees or taking occlusal radiographs may be helpful [2,6]. This is a general law not respected in the first appointment of the treatment of the presented case. Diagnosing the root

References

1. Andersson L, Andreasen JO, Day P. International Association of Dental Traumatology guidelines for the management of traumatic dental injuries: 2. Avulsion of permanent teeth. *Dental Traumatology*. 2012; **28**: 88-96.
2. Rouhani A, Javidi B, Habibi M, Jafarzadeh H. Intentional replantation: A procedure as a last resort. *Journal of Contemporary Dental Practice*. 2011; **12**: 486-492.
3. Al-Sane M, Bourisly N, Almulla T, Andersson L. Laypeoples' preferred sources of health information on the emergency management of tooth avulsion. *Dental Traumatology*. 2011; **27**:

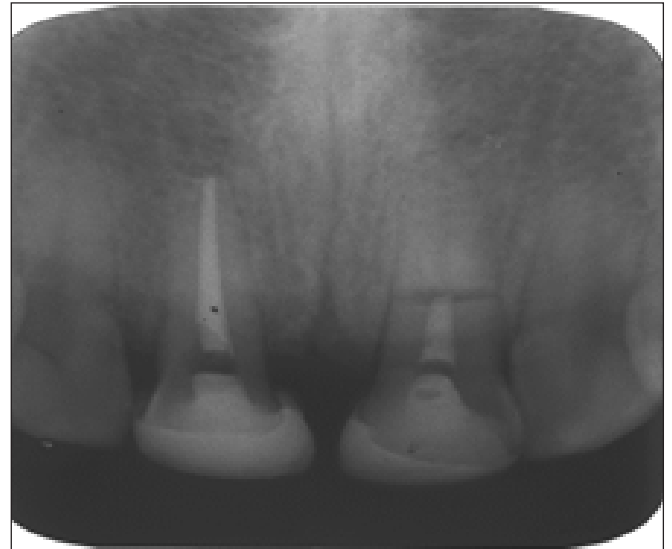

Figure 7. Four years follow-up radiograph.

fracture in the first appointment could be a help in obtaining a better prognosis.

In most cases of root fractured teeth, the pulpal circulation of the apical section is not disrupted, so the pulp necrosis in this segment is very rare. However, pulp necrosis of the coronal section may be seen in 25% of the cases. Splinting may induce healing of the fractured zone [2]. In the present case, the apical part of the tooth has been remained vital and no periapical pathosis is observed.

Follow-up of traumatized teeth is of paramount importance because the exact extent of damage is not discoverable at the first visit. Long term follow-ups may be hardly achievable; however, they can show the true prognosis of the traumatized teeth [7]. This case report involves a 4 year follow-up with favorable results.

In all follow-up visits, the pulp vitality testing of fractured teeth is necessary [8-10] which was not applicable in the present case because its coronal section has been endodontically treated. The careful evaluation of the traumatized teeth regarding clinical symptoms, radiographic signs, and vitality status are recommended.

Conclusion

Many of the challenges faced during endodontic management of traumatized teeth may be controlled by a precise and careful clinical and radiographic examination. Clinicians should be aware of taking extra periapical radiographs for diagnosis of oblique root fractures.

432-437.

4. Coccia CT. A clinical investigation of root resorption rates in reimplanted young permanent incisors: A five year study. *Journal of Endodontics*. 1980; **6**: 413-420.

5. Aras MH, Ozcan E, Zorba YO, Aslan M. Treatment of traumatized maxillary permanent lateral and central incisors horizontal root fractures. *Indian Journal of Dental Research*. 2008; **19**: 354-356.

6. Misra SB, Toumba KJ. Case report: A combined avulsion and root fracture/avulsion trauma with ten years review. *European Archives of Paediatric Dentistry*. 2008; **9**: 153-159.

7. Panzarini SR, Pedrini D, Poi WR, Sonoda CK, Brandini DA, Monteiro de Castro JC. Dental trauma involving root fracture and periodontal ligament injury: A 10-year retrospective study. *Brazilian Oral Research*. 2008; **22**: 229-234.

8. Jafarzadeh H, Abbott PV. Review of pulp sensibility tests. Part I: General information and thermal tests. *International Endodontic Journal*. 2010; **43**: 738-762.

9. Jafarzadeh H, Abbott PV. Review of pulp sensibility tests. Part II: Electric pulp tests and test cavities. *International Endodontic Journal*. 2010; **43**: 945-958.

10. Ajayi DM, Abiodun-Solanke IM, Sulaiman AO, Ekhalufoh EF. A retrospective study of traumatic injuries to teeth at a Nigerian tertiary hospital. *Nigerian Journal of Clinical Practice*. 2012; **15**: 320-325.