

Endonasal Endoscopic Approach for Primary and Secondary Orbital Lesions

Joel Caballero García^{1*}, Iosmill Morales Pérez¹, Franklin Abreu Perdomo¹, Nérido Gonzáles Fernández¹ and Adolfo Michel Giol Álvarez²

¹National Institute of Oncology and Radiobiology, Cuba

²Juan Manuel Marquez Paediatric Hospital, Cuba

*Corresponding author: Joel Caballero García, National Institute of Oncology and Radiobiology, Cuba, Tel: +53882195; E-mail: joelcg@infomed.sld.cu

Received date: June 27, 2017; Accepted date: July 27, 2017; Published date: August 01, 2017

Copyright: © 2017 García JC, et al. This is an open-access article distributed under the terms of the Creative Commons Attribution License, which permits unrestricted use, distribution, and reproduction in any medium, provided the original author and source are credited.

Abstract

Purpose: To describe the results of endonasal endoscopic resection for primary and secondary orbital lesions.

Design: A retrospective cohort study was performed.

Subjects: The clinical data of patients with primary and secondary orbital tumors who received treatment with endonasal endoscopic surgery from August 2016 to July 2017 in the Department of Head and Neck Surgery of the National Institute of Oncology and Radiobiology (Cuba) were analysed.

Intervention: All surgeries were performed by using Karl Storz 00, 450 and 700, 4 mm diameter; 18 cm rod-lens rigid telescopes (Karl Storz and Co, Tuttlingen, Germany). Endonasal endoscopic transtethmoidal route was the primary approach, and according to the tumor size, histology and location, a transantral route was aggregate.

Main outcome measures: Demographic data, histology nature of the lesions, clinical presentation, surgical route, frozen section margins and complications relative to treatment were obtained. Grade of resection was measured.

Results: From total of 12 patients that were interviewed, 7 were male and 5 female. Age range was 20-70 years and a mean age of 50.2 years. According to nature of the lesions, seven patients have malignant neoplasm and three patients have non-neoplastic disorders. Transtethmoidal route was performed in 4 patients and transtethmoidal/transantral in 8 patients. Total resection was achieved in 11 patients (92%). Frozen section margins were negative in all patients. All patients experienced complete resolution of the presenting symptoms with no evidence of optic nerve injury. Two patients presented transient opthalmoparesis.

Conclusion: Endonasal endoscopic surgery is a safe, successful and minimally invasive technique for resecting extra-intraconal primary and secondary orbital tumors; especially those arise posterior to the ocular globe and inferomedially of optic nerve. There are some important key points to take account in order to prevent complications.

Keywords: Orbital tumor; Endonasal endoscopic approach; Minimally invasive surgery

Introduction

In the domain of endoscopic orbital surgery, endoscopic dacryocystorhinostomy and orbital decompression are well-established techniques [1]. However, techniques for more advanced endoscopic intraconal surgery in benign tumors and orbital preservation in malignant nasosinus tumors are in their nascent stage [2-12].

We report a group of patients with intraconal and extraconal, primary and secondary extended orbital lesions including neoplastic and non-neoplastic etiologies. Indications and limitations of this approach were discussed take in account the location, pathology and tumor status.

Patients and Methods

The clinical data of patients with primary and secondary orbital tumors who received treatment with endonasal endoscopic surgery

from August 2016 to July 2017 in the Department of Head and Neck Surgery of the National Institute of Oncology and Radiobiology (Cuba) were retrospectively analysed.

All patients had been referred initially for diagnostic biopsy and possible treatment. Initial evaluation included a complete history and physical examination including diagnostic rhinoscopy.

Radiographic assessment included both Magnetic Resonance Imaging (MRI) and Computed Tomography (CT) of the skull and paranasal sinuses. The CT images were achieved at 2 mm thickness in the axial plane in order to reconstruct with OsiriX in the sagittal, coronal planes and 3D module for assessment preoperatively.

The inclusion criteria used for benign lesions were: 1) Intraconal or extraconal lesions situated posterior to the equator of the globe; 2) lesions situated medial or infero-medial to the optic nerve (in order to do not disturb this nerve); in malignant lesions were added: 3) previous biopsy that confirms the feasibility of the surgery (for example to discard lymphoma, indifferenciated carcinoma, etc.); 4) integrity of the periorbita in the MRI; and 5) absence of distant metastases.

The preoperative “checklist” included categorizing sphenoidal sinus type, locating the optic nerve position related to the lesion, identifying the localization of the tumor (intra-extraconal) and orbital extension. Displacement or involvement of papyracea, periorbita, orbital fat and extrinsic muscles must be noted. Such anatomic variations will impact on the extent of dissection and ease of access to the lesion.

The term “intraconal” was referred to tumors that lying within the boundaries of the muscles.

Demographic data, histology nature of the lesions, clinical presentation, surgical route, frozen section margins and complications relative to treatment were obtained. Grade of resection was measured.

All the patients were evaluated and discussed in an interdisciplinary team and the operations were carried out for a single surgical team composed by two neurosurgeons. All the operations were carried out by the first author as first surgeon, most of them with the attendance of another neurosurgeon (second and third authors).

Surgical technique

All patients underwent general anesthesia. The patients were placed in the supine position, with the head in the neutral position and with a 30 adduction. The nose was prepared with 2% lidocaine and 1:100,000 topical epinephrine. The head was secured with Mayfield head frame.

All surgeries were performed by using Karl Storz 00, 450 and 700, 4 mm diameter; 18 cm rod-lens rigid telescopes (Karl Storz and Co, Tuttlingen, Germany). Transethmoidal route was the primary approach, and according to the tumor size, histology and location, transantral route was aggregate. Transantral route was done when tumors extended adjacent to the orbital floor or in case of large lesions, in order to provide enough space for bimanual dissection technic. Extensive bone resection (including orbital floor but no more than 75%, so rigid reconstruction of inferior orbital wall was not necessary) was achieved in malignant tumors in order to perform an oncological safe surgery.

Different surgical steps were as follows:

1) **Nasal step:** Using a 00 grades telescope an inferior turbinate lateralization was performed. Surgical technic depends of nature of the lesion. In malignant tumors nasal step began with centrifugal removal of the lesion and them centripetal removal including the orbital component. In benign tumors a middle turbinectomy were achieved. Them, using the superior turbinate as a landmark the ipsilateral sphenoid ostium was localized (medial to the junction between middle third and inferior third). After that, a septostomy was performed as anteriorly as possible in order to facilitate a binarial approach and enough dissection angles for the most anterior part of the retrobulbar space (except in benign extraconal lesions situates in osteomeatal complex who was approached by means a mononarial approach without septostomy). Anterior and posterior ethmoidectomy was performed until papyracea was reached. The first step of ethmoidectomy was to perform an uncinectomy (Figure 1A) and identify and enlarge the natural ostium of the maxillary sinus (if a transmaxilar approach did not anticipated, to ensure that obstruction

of the ostium does not occur with prolapse of orbital fat once the orbital periosteum is opened) as Trisbas et al. [2] recommended. Anterior lesions were also required dissection of the frontal recess with clearance of all cells and exposure of the frontal ostium (Figure 1B). Authors used in this step a 300 or 450 scopes. Maxilar ostium was localized and exposed using a superior border of inferior turbinate as a reference. If an additional transantral approach was necessary, a wide middle antrotomy was performed o completely expose the inferior and medial orbit (Figure 1C).

2) **Sphenoidal step:** Using a 0 grades telescope, an ipsilateral hemisphenoidotomy was performed to expose lateral optocarotid recess and optic prominence as a landmark for orbital apex (Figure 1D). Bilateral exposure was not necessary in almost cases, only if optocarotid recess was not evident and it requires a wide bilateral exposure to use contralateral recess as a reference.

3) **Orbital step:** Using a 30 grades telescope a papyracea was removed by a Freer dissector ensuring that the orbital periosteum is kept intact. Approximately 1 cm of papyracea under the frontal sinus ostium was preserved to prevent orbital fat blocking of the frontal sinus drainage pathway (Figure 1E). Periorbita was exposed and incised in a window manner beginning with a vertical incision just anterior to sphenoid and continued anteriorly with two horizontal incisions, the first inferiorly just above the maxillary sinus and the second just below the skull base (to prevent orbital fat obstruction during this step) [2] (Figure 1F). An alternative included removing periorbita using a cut forceps. This cut was executed far to middle rectus muscle in order to avoid their injury. Them, orbital fat and tumor limits was identified. The extraconal fat was reduced *via* bipolar cautery or gently teased away to underlay medial rectus muscle identification. The tumor was dissected by microsurgery way using the four hands two surgeons technic (the first surgeon perform a bimanual dissection, using al aspirator in their left hand and a dissector or a bipolar in their right hand while the assistant holding the endoscope with their left hand performing a dynamic movement and the suction with their right hand) (Figure 1G). In intraconal tumors we used the surgical corridor between middle and inferior rectus muscle (Figure 1H). Otherwise, if this space was not enlarged, or if middle rectus muscle was infiltrated, a technique of rectus muscle retraction developed by McKinney et al. [3] was done, whereby the medial and inferior rectus muscles are isolated with vessel loops as they insert on the globe (Figure 1I). A 1 cm conjuntival incision was performed in middle point between middle orbital cantus and the pupil. Then, a muscular insertion was identified and mobilized using a loop. This manoeuvre facilitated the muscle identification (with movements of the loop) and it allows for traction to be placed on the muscles to make them less compressible and easier to dissect between. Using cutting forceps and fine endoscopic pituitary instruments facilitated manipulation of orbital soft tissue. However, blunt dissection was used when working directly in the vicinity of delicate surrounding structures. It is advantageous to have one assistant retracting the mass inferomedially, while the surgeon uses a bimanual technique to dissecting the lateral tumor margin.

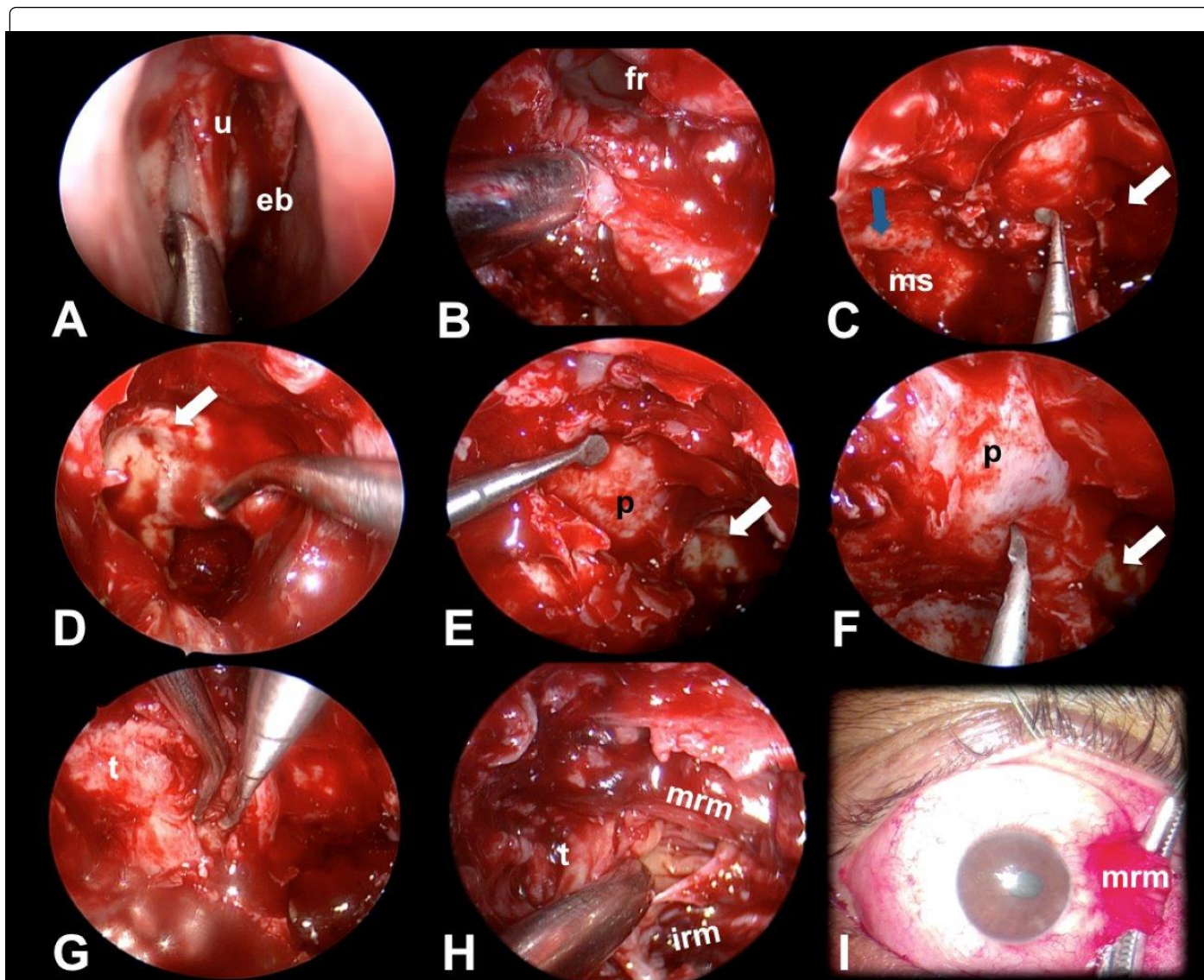


Figure 1: Different surgical steps. A: 0 grades scope vision after performing a uncinectomy; B: after frontal sinus recess and ostium exposition; C: after a wide maxillary antrostomy. Infraorbital nerve are exposed as a lateral limit of the orbital floor; D: wide right hemisphenoidotomy lateral opticocarotid recess and optic prominence are exposed as a landmark; E: during removal of papyracea of orbital apex; F: 45 grades scope vision during periorbita opening; G: exposing posterior pole of the tumor using a microsurgical bimanual dissection by four hands two surgeons procedure; H: 70 grades scope vision during removal of intraconal component of the tumor using the corridor between middle rectus muscle and inferior rectus muscle; I: exposition or medial rectus muscle attachment. eb: ethmoidal bulla; fr: frontal recess; irm: inferior rectus muscle; p: periorbita; ms: maxillary sinus; mrm: medial rectus muscle; u: unciform process; black arrow: infraorbital nerve; white arrow: optic prominence.

Once the lesion was removed, careful haemostasis was obtained, and the rectus muscle vessel loops were released. Frozen sections of the periorbital margins were performed in all cases. The orbital fat was then dragged over the muscles to prevent scarring. In malignant tumors orbital defect was covered with muscle fascia and in benign tumors with a nasoseptal flap, using tissue sealants (Tissuacryl). Nasal packing was not used because of the risk for raising the intraocular pressure.

4) **Reconstructive step:** In malignant tumors we covered orbital defect with fascia lata and in benign tumors with a patch of middle

turbinate mucoperiosteum previously resected, using tissue sealants (Tissuacryl).

Informed consent forms were obtained from all patients included in the study before treatment start.

The Ethics Committee of the National Institute of Oncology and Radiobiology approved this study. Research adhered to the tenets of the Declaration of Helsinki.

A CT scan was obtained during the first 24 h after surgery in order to identify complications (Figure 2A-2I). Ulterior following include a 3

months RMI in benign lesions in order to estimate the grade of resection and monthly RMI in malignant lesions during the first 6 months in order to estimate the local control. The minimum following was of 6 months.

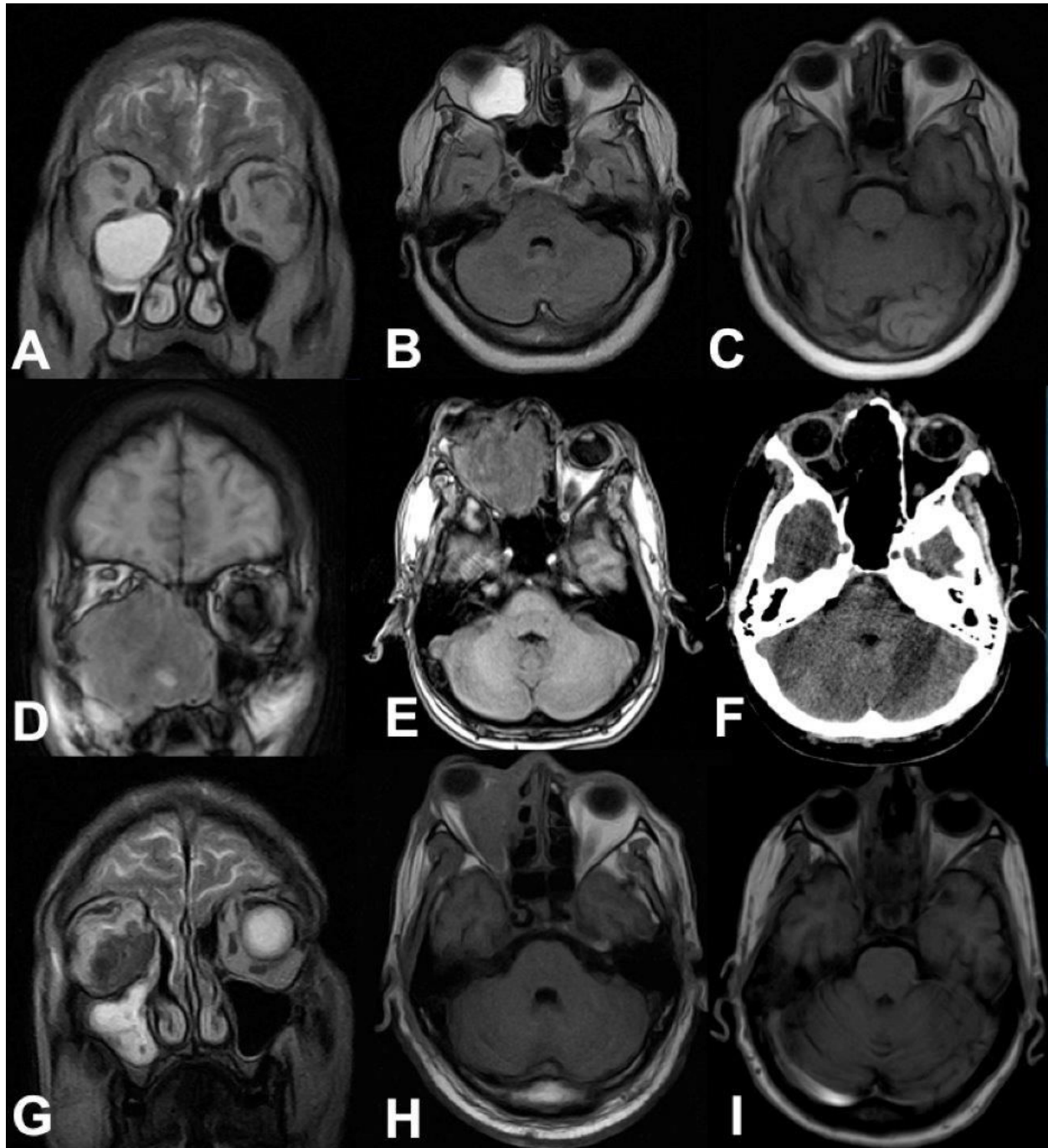


Figure 2: Preoperative and postoperative images of representative cases. A-B: preoperative coronal T2WI and axial T1WI RMI of patient number 4 with ethmoidal mucocele. C: postoperative T1WI RMI total removal of the mucocele. D-E: preoperative coronal and axial T1WI of patient number 1 with alveolar rhabdomyosarcoma. F: in postoperative CT scan a total resection of the lesion and medial orbital wall removal may observe. G-H: preoperative coronal T2WI and axial T1WI of patient number 3 with intraconal pseudotumor. I: postoperative CT scan shows a near-total removal of the lesion.

Results

From total of 12 patients that were interviewed, 7 were male and 5 female. Age range was 20-70 years and a mean age of 49.7 years. According to nature of the lesions, seven patients had malignant neoplasm (two adenocarcinomas, one esthesioneuroblastoma, one rhabdomyosarcoma, one undifferentiated carcinoma and one renal metastases), two patients had benign neoplasms (inverted papilloma and pilocytic astrocytoma of optic nerve) three patients have non neoplastic disorders (two mucoceles and one pseudotumor) (Table 1).

Transethmoidal route was performed in 4 patients and transethmoidal/transantral in 8 patients.

Total resection was achieved in 11 patients (92%). In one patient with orbital intra-extraconal pseudotumor the surgical resection was subtotal due the firm, infiltrative nature of the lesion and adhesions to ocular globe and medial rectus muscle (8%).

Frozen section margins were negative in all patients with malignant tumors. Definitive biopsy by paraffin confirmed previous frozen sections.

All patients experienced complete resolution of the presenting symptoms (including patients 7 and 11 with impairment of vision) with no evidence of optic nerve injury. Two patients presented transient ophthalmoparesis that solved between 2 and 3 weeks of the procedure. Patient with pseudotumor experienced transient diplopia due medial rectus muscle paresis due the adhesions or the tumor to this muscle.

Routinely preoperative or transoperative steroids was not used. Patient with orbital pseudotumor was treated with high steroid doses during the postoperative period and patients with malignant tumors were submitted for adjuvant chemo-radiotherapy treatment.

Id	Age	Sex	Pathology	Localization	Ophthalmologic sign/symptom	Surgical approach	Grade of resection	Complications
1	20	M	Rhabdomyosarcoma	Extraconal, retrobulbar	Proptosis, chemosis.	Transethmoidal/transantral	Total	Transient ophthalmoparesis
2	60	M	Esthesioneuroblastoma	Extraconal, retrobulbar	Proptosis	Transethmoidal/transantral	Total	None
3	44	M	Orbital pseudotumor	Intraconal inferomedial	Proptosis, ophthalmoparesis	Transethmoidal/transantral	Near-total	Transient ophthalmoparesis
4	60	F	Ethmoidal mucocele	Extraconal, retrobulbar	Proptosis	Transethmoidal/transantral	Total	None
5	62	F	Inverted papilloma	Extraconal, retrobulbar	Proptosis	Transethmoidal	Total	None
6	30	M	Adenocarcinoma	Extraconal, orbital apex	Ophthalmoparesis	Transethmoidal	Total	None
7	59	M	Sphenoidal mucocele	Extraconal, orbital apex	Vision loss	Transethmoidal	Total	None
8	63	F	Renal metastases	Extraconal, orbital apex	Proptosis, vision loss	Transethmoidal/transantral	Total	None
9	70	F	Epidermoid carcinoma	Extraconal, retrobulbar	Ocular pain.	Transethmoidal/transantral	Total	None
10	63	M	Undifferentiated carcinoma	Extraconal, retrobulbar	Proptosis	Transethmoidal/transantral	Total	None
11	11	F	Pilocytic astrocytoma	Intraconal, orbit nerve (intraaxial)	Vision loss	Transethmoidal	Total	None
12	54	M	Adenocarcinoma	Extraconal retrobulbar	Proptosis	Transethmoidal/transantral	Total	None

Table 1: Demographics, presentation, procedure and complications for patient series.

Discussion

A barber surgeon, George Bartisch, performed the first ocular cancer removal in the sixteenth century [13]. Conventional approaches for inferomedial intraconal space include LeFort I orbitotomy described by Dailey et al. [14] in 1998 and those approaches have been the "standard" technique until today in most of centers.

In 1990 Kennedy et al. [15] first described an endoscopic approach to decompression of the orbit for Graves Basedow ophthalmopathy.

Sethi and Lau in 1997 [16] described the benefits of endoscopic approaches to biopsy and decompressing tumors of the orbital apex. Since that time there has been increasing interest in the use of the endoscope to target tumors located in orbital apex.

Pure endonasal endoscopic approach for removal of orbital tumors was previously described in only a few reports [2-12]. Recently, recognized authors in this field like Carrau, Snyderman, Prevedello, Kassam [3] and Castelnovo [5] suggest that medially located

intraorbital lesions, especially the inferomedial ones, can be successfully by an endonasal endoscopic approach.

The endonasal endoscopic approach was successfully performed on all 12 patients in our cohort. Of these, total resection was achieved in most of them and a subtotal excision in one patient who have a firm, irregular and adherent, intra extraconal mass (pseudotumor).

Exposure of the medial intraconal space

Desinsertion of medial rectus muscle are often necessary during traditional approaches to lesions situated in this region because of this muscle constitutes the medial boundary to the intraconal space [6]. Authors opine that if there is an enlarged space between middle rectus muscle and inferior rectus muscle is not necessary to expose the rectus muscle attachment. However, as in some cases of these reports, when these space are normal or reduced, the microsurgical dissection are limited due the movable and elastic nature of these orbital structures. In these cases we use a middle and inferior muscle retraction as McKinney et al. [3] recommended with good results. Nevertheless there are other alternate techniques for controlling the rectus muscles: using a special instrument (double ball instrument), transeptal retraction, transchoanal retraction or detachment [17] of medial rectus muscle opening the medial orbit like a book with medial rectus pedicled on the annulus of Zinn [3].

Orbital preservation in malignant tumors

Orbital exenteration for locally advanced malignant nasosinusal tumors with orbital involvement was traditionally the preferred option [18]. However, it resulting in loss of visual function and disfigurement for the patient, producing a serious decline in quality of life. On the other hand, some studies show that the surgical removal of the invaded orbital organ in cases of carcinomas did not benefit patient survival [7,19]. Otherwise, preservation of orbital contents during surgical resection of malignant tumors encroaching on the orbit remains a controversial issue [8].

First reports suggested for orbital exenteration in all cases with bony orbital invasion [20,21]. In 1970, Sisson et al. [22] report a series of 60 patients with selective orbital preservation surgery following adjuvant preoperative radiotherapy. They found that orbital preservation did not affect local control or survival compared with patients with orbital exenteration. In these cohort authors doesn't use preoperative radiation in malignant tumors due the presumed integrity of periorbita in RMI studies. However, they pronounce that it is a reasonable option in cases with limited orbital fat invasion in order to reducing tumor mass prior to surgery. Recently, some authors have promoted orbital preservation in cases with limited soft tissue orbital invasion by resecting the invaded periorbita and using histological frozen section control to achieve negative margins [23,24].

Iannetti et al. [25] staged orbital invasion in three stages: stage I: medial orbital wall erosion and destruction; stage II: tumor invasion of orbital fat; stage III: invasion of medial rectus muscle, optic nerve, ocular bulb or eyelid skin. Histological studies have shown that tumor invasion is limited to the periorbit so orbital exenteration is recommended only in stage III [8].

There were few previously reports of conservative attitude preserving ocular globe in surgery of ethmoid tumors extended to the orbit in traditional 9 and endoscopic approaches with acceptable results [8].

In a recent systematic revision [10] the authors conclude that presently, tumors that extend to the bony orbital walls with or without focal infiltration of the periorbit are amenable to orbital preservation. Instead, infiltration of extraocular muscles and neurovascular structures are an indication to orbital exenteration. The ideal surgical treatment in cases of limited involvement of orbital fat is still controversial.

In this cohort, authors perform a conservative surgery in 8 patients with invasive tumors (7 malignant and one inverted papilloma). Frozen section margins were negative in all patients, demonstrating the oncologically safe procedure.

Surgical principles - Avoiding complications

The endonasal endoscopic approach has some advantages over external conventional approaches for retrobulbar medial/inferior orbital lesions. External scarring is not present so preserves cosmetic. Endoscopic view offers a better illumination and angular visualization, while external approach has a cone-shaped surgical window with less illumination and visibility. On the other hand, conventional approaches to lesions of the medial orbital demand significant displacement of orbital structures and medial rectus muscle desinsertion.

However, endonasal endoscopic approach is limited for lesions that extended anterior to the orbital globe midpoint, especially if are adherent. Instead, require familiarization with endoscopic technic, visualization and a teamwork philosophy.

There are some keys points must be tailed in order to prevent complications. One of the cranial base endoscopic surgeries principle is do not disturb cranial nerves, so, optic nerve must localized lateral to the tumor (usually displaced supero-laterally). McKinney et al. 3 recommended do not extend papiracea removal near to the level of ethmoidal arteries in other to avoid damaged to these vessels and reduce the risk of retrobulbar hemorrhage and vision loss. Work between rectus muscles preserve their function and transmuscular approach are not recommended [3].

There are vascular, neural and muscular early complications [9]. Vascular complications include diffuse venous bleeding secondary to orbital fat damage, and ethmoid artery bleeding which is the main source of vascular complications to the orbit. This bleeding leads to the formation of orbital hematoma with intraocular pressure increasing and optic nerve or retina compromise. Neural complications include optic nerve damaged, which can occur directly by surgical instruments or indirectly secondary to orbital hematoma [9]. Muscular complications are secondary to right medial and inferior muscles and can be avoided using technics of exposure the medial extraconal space as previously referred. The complications of external conventional approaches for orbital tumors include motility deficits (22.9%), ptosis (13.6%), visual deterioration (12.1%), etc. [26,27]. In this cohort only one patient suffer any complication (diplopia secondary to middle rectus muscle paresis) relative to surgical manipulation of these muscles due the adherent nature of the tumor (firm, adherent pseudotumor).

Results of this study support that endonasal endoscopic surgery is a safe, successful and minimally invasive technique for resecting extra-intraconal primary and secondary orbital tumors; especially those arise posterior to the ocular globe and inferomedially of optic nerve. There are some important key points to take account in order to prevent complications.

References

1. Lund VJ, Stammberger H, Nicolai P, Castelnuovo P, Beal T, et al. (2010) European position paper on endoscopic management of tumours of the nose, paranasal sinuses and skull base. *Rhinol Suppl* 22: 1-143.
2. Tsirbas A, Burt BO, Mancini R, Wormald PJ (2008) Endoscopic surgery of the orbital apex. *Operat Tech Otolaryngol* 19: 167-171.
3. McKinney KA, Snyderman CH, Carrau RL, Germanwala AV, Prevedello DM, et al. (2010) Seeing the light: Endoscopic endonasal intraconal orbital tumor surgery. *Otolaryngol Head Neck Surg* 143: 699-701.
4. Sun MT, Wu W, Yan W, Tu Y, Selva D (2017) Endoscopic endonasal-assisted resection of orbital schwannoma. *Ophthalm Plast Reconstr Surg* 33: 121-124.
5. Castelnuovo P, Dallan I, Locatelli D, Battaglia P, Farneti P, et al. (2012) Endoscopic transnasal intraorbital surgery: our experience with 16 cases. *Eur Arch Otorhinolaryngol* 269: 1929-1935.
6. Wu W, Selva D, Jiang F, Jing W, Tu Y, et al. (2013) Endoscopic transthemoidal approach with or without medial rectus detachment for orbital apical cavernous hemangiomas. *Am J Ophthalmol* 156: 593-599.
7. Chen NX, Chen L, Wang JL, Wang JY, Yan F, et al. (2016) A clinical study of multimodal treatment for orbital organ preservation in locally advanced squamous cell carcinoma of the nasal cavity and paranasal sinus. *Jpn J Clin Oncol* 46: 727-734.
8. Imola MJ, Schramm VL Jr (2002) Orbital preservation in surgical management of sinonasal malignancy. *Laryngoscope* 112: 1357-1365.
9. Stoica C, Hainarosie R, Stan C, Zainea V (2015) Conservative attitude preserving ocular globe in surgery of ethmoid tumor extended to the orbit. *Rev Chim* 66: 158-161.
10. Muscatello L, Fortunato S, Seccia V, Marchetti M, Lenzi R (2016) The implications of orbital invasion in sinonasal tract malignancies. *Orbit* 35: 278-284.
11. Re M, Tarchini P, Gioacchini FM, Pasquini E (2016) Endonasal endoscopic approach for removal of intraorbital cavernous hemangioma in childhood. *Head Neck* 38: E1-E6.
12. Arai Y, Kawahara N, Yokoyama T, Oridate N (2016) Endoscopic transnasal approach for orbital tumors: A report of four cases. *Auris Nasus Larynx* 43: 353-358.
13. Straatsma BR (1994) Principles and practice of ophthalmology. *Arch Ophthalmol* 112: 1153.
14. Dailey RA, Dierks E, Wilkins J, Wobig JL (1998) LeFort I orbitotomy: a new approach to the inferonasal orbital apex. *Ophthalm Plast Reconstr Surg* 14: 27-31.
15. Kennedy DW, Goodstein ML, Miller NR, Zinreich SJ (1990) Endoscopic transnasal orbital decompression. *Arch Otolaryngol Head Neck Surg* 116: 275-282.
16. Sethi DS, Lau DP (1997) Endoscopic management of orbital apex lesions. *Am J Rhinol* 11: 449-455.
17. Lin GC, Freitag SK, Kocharyan A, Yoon MK, Lefebvre DR, et al. (2016) Comparative techniques of medial rectus muscle retraction for endoscopic exposure of the medial intraconal space. *Am J Rhinol Allergy* 30: 226-229.
18. McIntyre C, Allen J, Jones S, Nash R, Clarke PM (2014) Quality of life after orbital exenteration. *J Neurol Surg Part B: Skull Base* 75: a143.
19. Suárez C, Ferlito A, Lund VJ, Silver CE, Fagan JJ, et al. (2008) Management of the orbit in malignant sinonasal tumors. *Head Neck* 30: 242-250.
20. Ketcham AS, Chretien PB, Van Buren JM, Hoyer RC, Beazley RM, et al. (1973) The ethmoid sinuses: a re-evaluation of surgical resection. *Am J Surg* 126: 469-476.
21. Harrison DFN (1976) Problems in surgical management of neoplasms of the paranasal sinuses: a retrospective study. *J Laryngol Otol* 90: 68-74.
22. Sisson GA Sr, Toriumi DM, Atiyah RA (1989) Paranasal sinus malignancy: a comprehensive update. *Laryngoscope* 99: 143-150.
23. Perry C, Levine PA, Williamson BR, Cantrell RW (1988) Preservation of the eye in paranasal sinus cancer surgery. *Arch Otolaryngol Head Neck Surg* 114: 632-634.
24. McCary SW, Levine PA, Cantrell RW (1996) Preservation of the eye in the treatment of sinonasal malignant neoplasms with orbital involvement. *Arch Otolaryngol Head Neck Surg* 122: 657-659.
25. Iannetti G, Valentini V, Rinna C, Ventucci E, Marianetti TM (2005) Ethmoido-orbital tumors: our experience. *J Craniofac Surg* 16: 1085-1091.
26. Yan J, Wu Z (2004) Cavernous hemangioma of the orbit: analysis of 214 cases. *Orbit* 23: 33-40.
27. Khan AM, Varvares MA (2006) Traditional approaches to the orbit. *Otolaryngol Clin North Am* 39: 895-909.