

Essentials of Intraoperative Gonioscopy

Shakeel Shareef

Flaum Eye Institute, University of Rochester School of Medicine and Dentistry, Rochester, USA

Corresponding author: Shakeel Shareef, MD, Flaum Eye Institute - University of Rochester School of Medicine and Dentistry, Rochester, NY, USA, Tel: 585-276-6104; E-mail: shklshrf@gmail.com

Received date: Sep 22, 2015; **Accepted date:** Oct 06, 2015; **Published date:** Oct 09, 2015

Copyright: © 2015 Shareef S. This is an open-access article distributed under the terms of the Creative Commons Attribution License, which permits unrestricted use, distribution, and reproduction in any medium, provided the original author and source are credited.

Commentary

Since Barkan's description of goniotomy in 1936 [1], angle surgery was primarily confined to the pediatric age group [2]. However, following the FDA approval of the Trabectome [3] (NeoMedix) in 2006 and the iStent [4] (Glaukos Corp.) in 2012, there has been an exponential growth within the micro-invasive glaucoma surgery (MIGS) arena, especially amongst the adult population [5-9]. Over the last decade, several other micro-stent devices are currently awaiting clinical trials or nearing commercialization (Table 1) [7-9]. Independent of the dynamic progress within this field, the rate-limiting step and key to successful angle surgery will remain optimal visualization of angle anatomy with intraoperative direct gonioscopy [10].

Surgical gonioscopy forms part of a continuum of essential perioperative steps (Table 2) ophthalmologists need to consider if they wish to embark on operating in a surgically confined space of 0.7 mm [11] within the angle. However, the need to learn this new skill set does not replace the pre-operative slit lamp based indirect gonioscopy needed for surgical planning [12]. In a chart review of patients undergoing ocular medical therapy, <50% had documentation of gonioscopy [13]. Additionally, an analysis of Medicare claims data showed that only 50% of open angle glaucoma patients undergoing surgery had a claim for pre-operative gonioscopy [14].

Familiarity of angle anatomy is essential in determining a patient's surgical candidacy. Is the angle open or closed? If closure is present, is it appositional or synechial? Identification of the scleral spur serves as the surgical landmark separating the conventional outflow pathway anteriorly (via the trabecular meshwork for canal based surgery) from the uveoscleral pathway posteriorly (via the ciliary body for suprachoroid based surgery) (Figure 1). For novice surgeons, initial consideration for a peri- or retrobulbar block to attain akinesia is a reasonable step in order to help build surgical confidence and avoid potential intra-ocular complications.

Procedure	#Performed or Implanted	FDA Approval or Trials
Trabectome (NeoMedix)	>5,435 [5]	June 2006 [3]
iStent (Glaukos)	>100,000 [6]	June 2012 [4]
CyPass (Transcend)	>1,000 [7]	COMPASS trial completed March 2015 [8]
Hydrus (Ivantis)	2000 [9]	Investigational use in US

Table 1: Gonioscopic assisted angle surgeries.

Intra-operatively, one needs to consider both extra- and intraocular factors [Table 2]. In order to access the angle nasally from a temporal approach, the head needs to be rotated approximately 30 to 40 degrees away while the microscope should be rotated an equal amount towards the surgeon. The endpoint is to find an appropriate combination to align the coaxial light along the axis of the iris plane. Unlike phacoemulsification [Table 3] with full access to the entire cornea, these adjustments will result in a narrow viewing space that is confined to the anterior chamber (AC) depth, coupled with an increased working distance between the oculars and surgical field. In the absence of a red reflex, the light intensity will need to be increased and magnification adjusted in order to optimally view the desired target tissue.

		Steps	Descriptor
PRE-OP		1	Office Based Gonioscopy
		2	Angle Anatomy
		3	Anesthesia
INTR A-OP	EXTRA-OCULAR	4	Head/Microscope Rotation
		5	Goniolens Selection
		6	Hand Positioning
	INTRA-OCULAR	7	Corneal Incision
		8	Soft Shell Technique
		9	Goniolens Docking and Manipulation
POST-OP		10	Gonioscopy/Goniophotography

Table 2: Essential perioperative steps for successful angle surgery.

Several surgical goniolenses are commercially available [10,15]. Present options all represent a modification of the Swan Jacob lens by varying in degree of corneal contact, field of view, magnification, and handle length [10]. With the exception of the Volk Transcend Vold Gonio (TVG) Surgical Lens [16], the handles are contiguous with the goniolens [15]. The TVG lens is characterized by a free floating lens mounted on a separate sliding handle originating from a hinge suspended on the main handle [16]. In the setting of akinesia, the type of goniolens selected is rarely a critical factor in angle surgery.

Left and right-handed handles are made available based on surgeon preference (i.e., Hill lens), [10] or they are designed for ambidextrous use in order to avoid the need for purchasing multiple lenses. While in use, the handle is clutched in the non-dominant hand with the palm side resting gently either on the patient's forehead or cheekbone

(depending upon laterality) while the fingers are arched parallel to the nasal bridge.

There are several important intraocular factors to consider when performing surgical gonioscopy. These include eccentricity and location of the temporal corneal incision. Wound construction with femtosecond laser assisted cataract surgery is typically offset by a few millimeters inward from the limbus, and can subsequently interfere with peripheral access and intraocular manipulation due to surgical instruments abutting the edge of the goniolens externally. I prefer to make the corneal incision manually just inside the limbus along the 3 to 9 o'clock plane. With a fixation ring, nasal globe rotation facilitates access to the peripheral cornea during initial entry with the keratome. The wound location serves not only as a pivot point and anchor for instruments during intraocular surgical manipulation but it also provides equidistant access to angle structures nasally in the superior and inferior quadrants.

Intraocular manipulation with MIGS takes place anterior to the iris plane in a confined space with added risk to the cornea and iris (Table 3). To protect ocular structures during angle surgery, I employ Arshinoff's soft shell technique [17] to facilitate safe entry of instruments into the AC by providing an adequate workspace. A layer of dispersive ophthalmic viscosurgical device (OVD) is injected to coat and protect the corneal endothelium. Next, a second deeper layer of a cohesive OVD is injected to both tamponade the initial dispersive OVD against the inner cornea anteriorly and advanced into the angle to create and maintain a safe work space.

	Phacoemulsification	
Viewing	Full corneal access	Limited AC depth; increased work distance
Intraocular Surgery	Posterior to dilated iris sphincter	Anterior to iris plane; risk to cornea/iris in narrow space
Corneal Stimulation	Limited to keratome/side-port incisions	Stimulation of sub-epithelial nerve endings in entire surface by goniolens
Instrument Handling	Bimanual intraocular	Simultaneous extra and intra-ocular manipulation; one handed surgery

Table 3: Phacoemulsification vs. Microinvasive Glaucoma Surgery (MIGS). AC: Anterior Chamber

During cataract surgery, the keratome and paracentesis incisions result in minimal neurostimulatory corneal effects [18] (Table 3). Conversely, with MIGS surgery, docking of the surgical goniolens stimulates the entire surface of sub-epithelial nerve endings and limbal plexus [18]. Under topical anesthesia, this can result in discomfort and involuntary saccades with added risk for intra-ocular complications including bleeding and iridodialysis [19]. The use of topical lidocaine gel has been shown to provide analgesia, patient comfort and decreased sensation of tissue manipulation [20]. In lieu of topical anesthetic drops or viscoelastic, I have found that patients tend to be more tolerant during surgery when the anesthetic gel has been applied as a coupling medium between the cornea and goniolens. Furthermore, lens modification with a fixation ring (TVG, Khaw lens) or a peripheral flange (Hill lens) have been designed to not only counter involuntary eye movements but provide globe stability and control during delicate angle surgery [10]. These modifications further enable nasal globe rotation as well as cyclotorsion along the z axis [21] facilitating implantation and or surgical manipulation.

Finally, in the case of MIGS involving micro-stent devices, post-operative office based gonioscopy and gonioscopy serve to not only assess proper anatomic placement but also act to build the doctor-patient relationship when patients are shown the outcomes of the

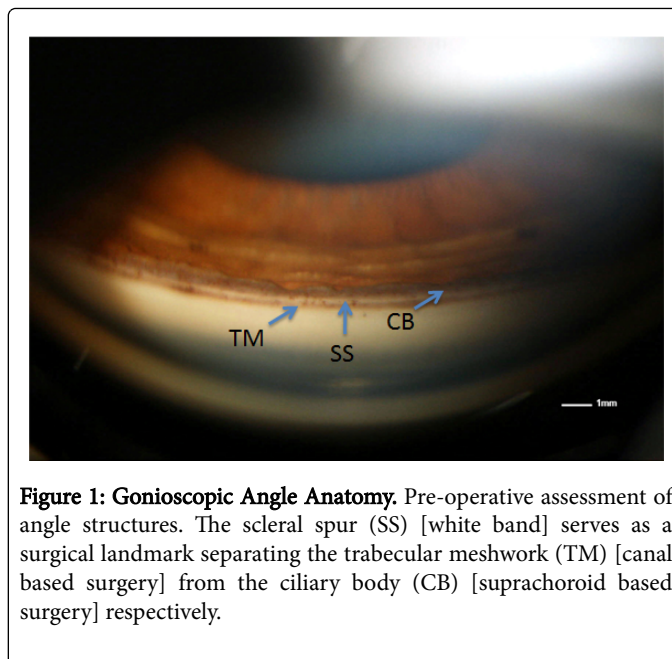


Figure 1: Gonioscopic Angle Anatomy. Pre-operative assessment of angle structures. The scleral spur (SS) [white band] serves as a surgical landmark separating the trabecular meshwork (TM) [canal based surgery] from the ciliary body (CB) [suprachoroid based surgery] respectively.

surgery. Additionally, the photos will later provide a means of counseling surgical candidates regarding options available to them in managing their glaucoma with MIGS.

References

1. Barkan O (1936) A new operation for chronic glaucoma. Am J Ophthalmol 19: 951.
2. Mandal A, Chakrabarti D (2012) Evolution of surgery for congenital glaucoma. Bengal Ophth J 10-19.
3. www.accessdata.fda.gov/cdrh_docs/pdf6/k061258.pdf
4. http://www.accessdata.fda.gov/cdrh_docs/pdf8/p080030a.pdf
5. Mosaed, S (2014) The First Decade of Global Trabectome Outcomes. European Ophthalmic Review 8: 113-119.
6. Corporate Communication, Glaukos.
7. Personal Communication, implantations outside U.S. June 2015
8. https://clinicaltrials.gov/ct2/show/study/NCT01085357
9. Personal communication July 6, 2015 [700 implanted in multi-center trials; 1300 in training programs]
10. Shareef S, Alward W, Crandall A, Vold S, Ahmed I (2014) Intra-operative gonioscopy: a key to successful angle surgery. Expert Review of Ophthalmology 9: 515-527.

11. Kasuga T, Chen YC, Bloomer MM, Hirabayashi KE, Hiratsuka Y, et al. (2013) Trabecular meshwork length in men and women by histological assessment. *Curr Eye Res* 38: 75-79.
12. Gonioscopy.org (2015) University of IOWA Health Care. *Ophthalmology and Visual Sciences*. Available from: <http://www.gonioscopy.org/>
13. Quigley HA, Friedman DS, Hahn SR (2007) Evaluation of practice patterns for the care of open-angle glaucoma compared with claims data: the Glaucoma Adherence and Persistency Study. *Ophthalmology* 114: 1599-1606.
14. Coleman AL, Yu F, Evans SJ (2006) Use of gonioscopy in medicare beneficiaries before glaucoma surgery. *J Glaucoma* 15: 486-493.
15. <http://www.ocularinc.com/products/gonio-lenses/surgical-gonio-lenses.html>
16. <http://www.volk.com/index.php/volk-transcend-vold-gonio-tvg-surgical-lens.html>
17. Arshinoff SA (1999) Dispersive-cohesive viscoelastic soft shell technique. *J Cataract Refract Surg* 25: 167-173.
18. Shaheen BS, Bakir M, Jain S (2014) Corneal nerves in health and disease. *Surv Ophthalmol* 59: 263-285.
19. Shareef S (2015) Get in on the ACT-Optimization of Angle Surgery.Channels: Glaucoma. EyeTube.
20. Page M, Fraunfelder F (2009) Safety, efficacy, and patient acceptability of lidocaine hydrochloride ophthalmic gel as a topical ocular anesthetic for use in ophthalmic procedures. *Clin Ophthalmol* 3: 601-609.
21. Shareef S (2015) Optimizing Angle Surgery with ACT. *Glaucoma Today* 13: 48-50.