

## Evaluation of Dehydrated Human Amnion/Chorion Membrane as an Adhesion Barrier in Women Undergoing Robotic Laparoscopy

John Dulemba\*, Pezhman Mirzakhani, and Niki B Istwan

Tryon, North Carolina, United States

\*Corresponding author: John Dulemba, MD; Denton, Texas, United States, Tel: 940-387-6248; Email: [jdulemba@prodigy.net](mailto:jdulemba@prodigy.net)

Received date: Aug 31, 2016; Accepted date: Oct 12, 2016; Published date: Oct 19, 2016

Copyright: © 2016 Dulemba J, et al. This is an open-access article distributed under the terms of the Creative Commons Attribution License, which permits unrestricted use, distribution, and reproduction in any medium, provided the original author and source are credited.

### Abstract

**Introduction:** Amniotic membrane contains collagen, cytokines and growth factors, is immune privileged, and has been shown to modulate inflammation and reduce scarring. Dehydrated human amnion/chorion membrane (dHACM) allografts have been used in many clinical and surgical applications to facilitate healing. We describe our experience of using commercially available dHACM allograft as an adhesion barrier in women undergoing da Vinci robot laparoscopy at an outpatient surgery center.

**Methods:** With IRB permission, we conducted a retrospective evaluation of medical records from 16 consecutive patients that had undergone robotic laparoscopy for pelvic pain due to endometriosis and adhesions. All patients had resection of endometriosis and adhesiolysis with application of dHACM. As per our routine practice, all had been scheduled for a second surgery to inspect for reformation of adhesions, and to lyse any additional adhesions found.

**Results:** We found handling characteristics of dHACM to be suitable for the microsurgery environment, although care needed to be taken to avoid fraying or breaking the material as it was introduced through the trocar. Fifteen of 16 patients receiving dHACM had a second procedure 1-2 weeks later. In 14 of the 15 cases, no new adhesions were observed in areas where dHACM was placed. No adverse events or major complications had been recorded in the medical record.

**Discussion:** The biologic properties of dHACM give rise to its use in a wide variety of clinical applications. Our experience demonstrates that using dHACM as an adhesion barrier is feasible in women undergoing da Vinci robot laparoscopy.

**Keywords:** Amniotic membrane; Laparoscopy; Dehydrated human amnion/chorion membrane

### Introduction

Peritoneal adhesions that develop following pelvic and abdominal surgery are a frequent cause of intestinal obstruction, reduced fertility, and pelvic pain [1]. While the risk for adhesion formation cannot be completely eliminated, development of postoperative adhesions may be minimized through careful surgical techniques and adherence to microsurgical principles. Surgical barriers may also help to decrease postoperative adhesion formation [1].

The use of human amniotic membrane based products has been considered for the prevention of fibrosis and adhesions. Amniotic membrane has inherent properties including being immune privileged, and having the ability to modulate inflammation and reduce scar tissue formation [2-5]. Such properties present significant therapeutic potential for use of amniotic membrane during wound healing, tissue repair, and regenerative therapy [2-5]. Human amniotic membrane has also been shown to exhibit antibacterial, hemostatic, and pain reduction properties [5]. It is self-signaling, and mediates tissue repair via growth factors contained in the tissue [5].

Amniotic membrane, comprised of both amnion and chorion, is metabolically active tissue, which continually remodels the

extracellular matrix through processes controlled by paracrine growth factors [6]. Amnion is comprised of primarily collagen types I, III, V and VII and glycosaminoglycans.

Chorion is thicker than amnion, contains type IV collagen and is composed of a reticular layer, basement membrane, and trophoblast layer [6].

Human amniotic membrane contains growth factors, which are known to stimulate epithelial cell migration and proliferation as well as many metabolic processes, including general protein and collagen synthesis, collagenase activity, and chemotaxis of fibroblasts and of smooth muscle cells [2].

A search of the literature shows that amniotic membrane has been used in a variety of clinical applications including, but not limited to, conjunctival reconstruction, pterygium repair, tympanoplasty, and various other surgical and wound applications [7-11].

Animal studies have shown that implanting amniotic membrane reduces postlaminectomy epidural adhesions, as well as peritoneal adhesions [3,12].

The purpose of this report is to describe our experience in using a commercially available dehydrated human amnion/chorion membrane (dHACM) allograft (AmnioFix<sup>®</sup>, MiMedx Group, Inc., Marietta, GA) as an adhesion barrier in women undergoing da Vinci<sup>®</sup> robot laparoscopy.

## Methods


With Institutional Review Board (Chesapeake IRB) exemption, medical records were examined from 16 consecutive patients that underwent da Vinci robot laparoscopy over a 2 year period for pelvic pain due to endometriosis and adhesions with application of dHACM as an adhesion barrier. Per our routine practice, patients were scheduled for a second procedure within 2 weeks after the initial laparoscopy to inspect for any formation, or reformation, of adhesions, and to lyse any additional endometriosis lesions or adhesions found.

Robotic laparoscopy was performed under general anesthesia with the patient positioned to obtain sufficient surgical exposure at a Trendelenburg angle of approximately 20%. An indwelling catheter was placed to maintain bladder deflation, and a uterine manipulator was inserted through the uterus, or a manipulator to move the vagina when the uterus was absent. A thorough evaluation of the abdominal cavity was performed after insufflation of carbon dioxide for pneumoperitoneum. Once the extent of endometriosis and/or adhesions was evaluated one robotic trocar and one assistant trocar (12 mm) were introduced, then two 8 mm trocars were inserted lateral to the umbilicus. After endometriosis resection and/or adhesiolysis the dHACM allograft was introduced through the assistant trocar. The dHACM was placed in areas where adhesions are most likely to form: on the pelvic sidewalls, cul de sac, areas of raw/denuded peritoneum, and areas of previous lysed adhesions.

### The dHACM allograft handling characteristics and placement method

Based on each patient's requirements one or two 4 cm × 6 cm dHACM allograft sheets were utilized, and cut into smaller sections if needed for multiple placement areas. Each graft is embossed with the letters UP indicating that the amnion side of the graft is on top and chorion side of the graft is down (Figure 1). Since the allograft is dehydrated, care must be taken to avoid fraying or breaking the material as it is introduced through the trocar. We have found that it works best to fold the dHACM graft 3-4 times with the chorion layer on the inside and to introduce the material through the 12 mm trocar then grasp the edge and slowly unfold. The graft is then placed as a barrier with the amnion side down. Once the graft is in the desired

location it is hydrated with sterile saline. Hydration is necessary in order to insure that the graft adheres to the desired location. Smoothing out any air pockets behind the graft allows for maximum contact. The dHACM was not sutured in place.



**Figure 1:** Dehydrated human amnion/chorion membrane (dHACM) allograft embossed with the letters UP indicating that the amnion layer is on top and chorion layer is on the bottom

## Results

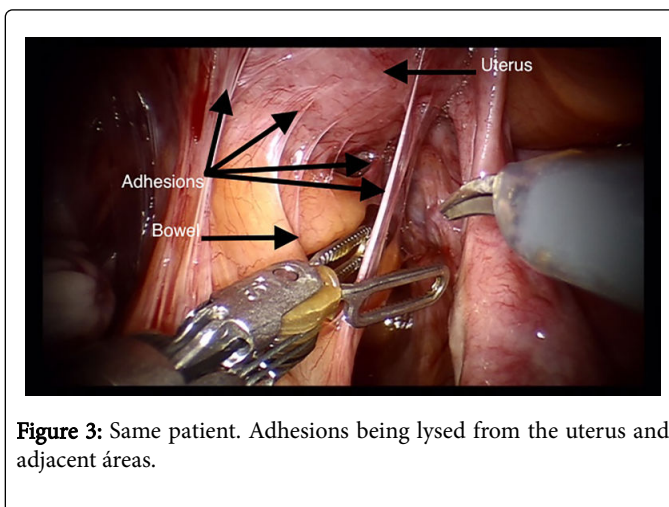
Cases are summarized in Table 1. Women ranged in age from 14 to 51 years with a mean age of  $31.4 \pm 9.4$  years. Mean body-mass-index (weight in kg/height in  $m^2$ ) was  $27.2 \pm 6.4$ , with 31.2% being obese. All but one patient had a history of previous abdominal surgery; mean prior surgeries numbered  $4.1 \pm 3.2$ . At time of laparoscopy, all 16 women were found to have significant abdominal adhesions. The dHACM allograft was applied to various areas based on location and extent of adhesiolysis or resection of endometriosis as described in Table 1.

Case	Age (yrs)	BMI	Previous abdominal surgeries	Surgical notes application of dHACM	Adhesions to dHACM (follow-up surgery)
1	28	30.8	10	dHACM placed at cecum and ascending colon where severe adhesions had formed. Acell had been placed in this location in previous surgery.	No
2	30	28	6	dHACM placed in cul de sac and posterior ovaries.	No
3	25	22.1	2	dHACM placed on left pelvic sidewall and abdominal side wall where ovarian and sigmoid adhesions were located.	Cancelled
4	34	24.5	8	dHACM placed on vaginal cuff post TLH, BSO.	No
5	46	25	2	dHACM placed on defects of left vaginal cuff and left sidewall, and right psoas muscle.	No
6	26	27.1	1	dHACM placed in cul de sac, left and right pelvic sidewalls.	No
7	30	22	9	dHACM placed in cul de sac and left and right pelvic sidewalls.	No

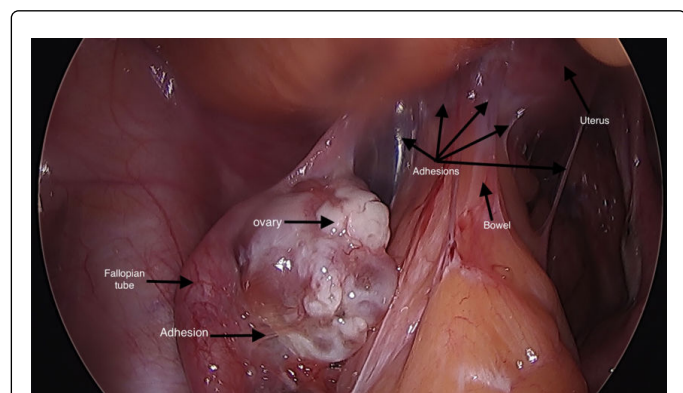
8	30	18	0	dHACM placed on left and right sidewalls.	No
9	39	33	4	dHACM placed on left sidewall where sigmoid had been adhered.	No
10	34	26.2	6	dHACM placed in cul de sac.	No
11	20	17.7	1	Left and right ovaries severely adhered to the respective pelvic sidewalls. dHACM placed on left and right pelvic sidewalls and cul de sac.	No
12	40	41.3	8	Adhesions noted from umbilicus to the vaginal cuff in a severe manner. dHACM placed at the cuff on left and right sides.	Yes
13	51	36.6	3	Bowel adhered along right pelvic sidewall and vaginal cuff, tenting cuff to the right. dHACM placed at right pelvic sidewall and right side of vaginal cuff.	No
14	14	23.4	2	dHACM tissue placed on left and right pelvic sidewalls.	No
15	23	26.6	1	dHACM placed in cul de sac, and left and right pelvic sidewalls.	No
16	33	32.3	3	dHACM placed on the back of the uterus and the left pelvic sidewall.	No
Overall	31.4 ± 9.4	27.2 ± 6.4	4.1 ± 3.2		

**Table 1:** Sixteen consecutive cases receiving dHACM as an adhesion barrier.

Although a second laparoscopy was scheduled in all 16 cases, one patient cancelled her surgery, thus we were able to evaluate reformation of adhesions in fifteen of the sixteen patients that received the dHACM allograft barrier. The second surgery occurred within 2 weeks of dHACM application. Overall, in these 15 patients, dHACM appeared to reduce the incidence of adhesion development. In all but one case no adhesions had formed where dHACM was placed. In one case, adhesions were noted to have formed on the dHACM, yet these adhesions were more easily dissected than adhesions that formed in other areas where no dHACM had been placed. Only one graft had moved from where it had been initially placed (case 15). In that case, adhesions had formed near, but not on, the dHACM. Images from case 16, a 33-year-old female with severe adhesions following 2 prior laparoscopies and 1 prior laparotomy are shown in Figures 2-6. There were no adverse events related to the use of dHACM (Figures 2-6).



**Figure 3:** Same patient. Adhesions being lysed from the uterus and adjacent areas.

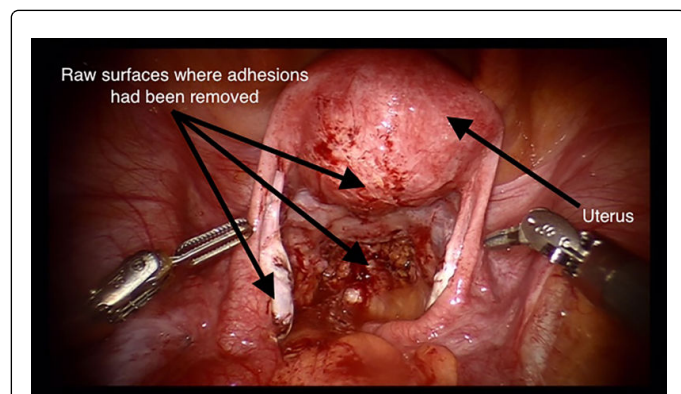


**Figure 2:** Before placement of dHACM. Patient: 33 year old, obese female with history of 2 prior laparoscopies and 1 prior laparotomy for treatment of pelvic pain due to endometriosis and adhesions.

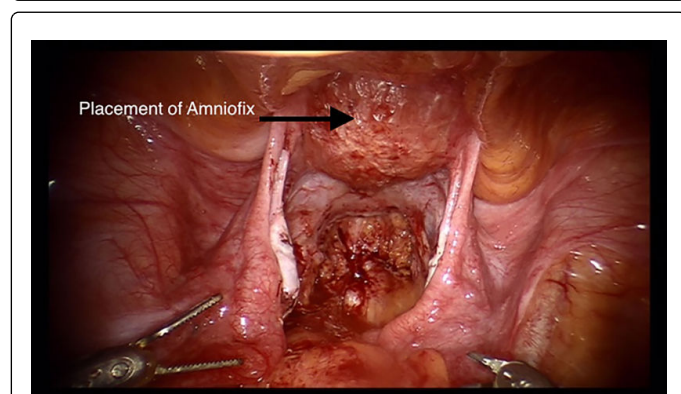
## Discussion

Generally, adhesion formation may be regarded as defective wound healing and as disturbed regeneration of the peritoneal surface [13]. Development of adhesions is a consequence of surgical tissue trauma. Tissue trauma may result from sharp, mechanical or thermal injury; infection; radiation; ischemia; desiccation; abrasion; or reaction to a foreign-body. A cascade of events is triggered involving the release of histamines, cytokines and growth factors, resulting in inflammation, increased vascular permeability and the development of fibrin exudate. In the presence of decreased fibrolytic activity, fibrin deposition and capillary ingrowth ensues and adhesions are formed [1]. Minimally invasive robotic surgery allows for 3-D visualization and very precise movements that may result in less tissue and organ handling and trauma, while avoiding contamination with foreign bodies such as surgical glove powder and lint from laparotomy pads, which may

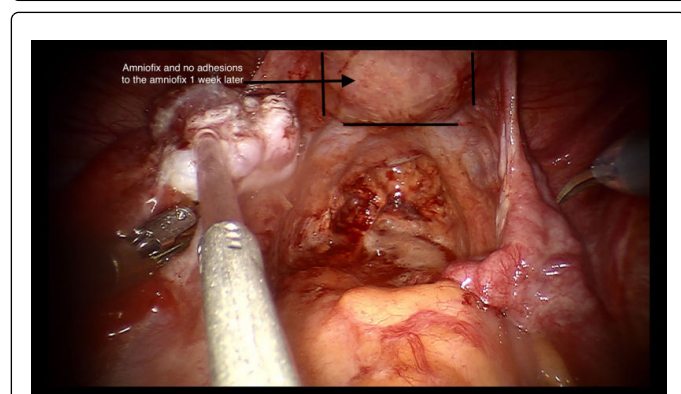
reduce risk for postoperative adhesion formation. Surgical barriers are frequently used to reduce the risk for development of adhesions, although handling characteristics of the barrier may limit the ability to use some barriers when minimally invasive surgical techniques are employed [1].



**Figure 4:** After removal of adhesions.



**Figure 5:** The dHACM allograft in place on the back of the uterus.



**Figure 6:** Same patient. Second look surgery 1 week later. No adhesions where dHACM was placed. Outline of allograft is less visible as the graft is being absorbed.

Dehydrated human amnion/chorion membrane (dHACM) is a dehydrated human tissue allograft comprised of amnion and chorion

membranes derived from donated human placentas. PURION<sup>®</sup> processed dHACM (AmnioFix<sup>®</sup>, MiMedx Group, Inc., Marietta, GA) has been shown to retain the growth factors in natural amniotic membrane including PDGF-AA, PDGF-BB, bFGF, TGF- $\beta$ 1, EGF, VEGF, and PlGF [14]. In addition to growth factors, cytokines including anti-inflammatory interleukins (IL-1ra, IL-4, and IL-10) and the TIMPs (TIMP-1, TIMP-2, and TIMP-4) which help regulate the matrix metalloproteinase (MMP) activity are also present in dHACM [14]. It has been suggested that decreased fibrinolytic activity induced by the cytokine TNF may impair the natural dissolution of fibrin deposits at the peritoneum in the presence of an inflammatory reaction [15]. Cell regulatory factors including TNF- $\alpha$  and IL-10 have been shown to be down regulated in the presence of dHACM [16].

Use of dHACM as a barrier is not unprecedented. A pilot study investigated the use of a dHACM barrier in reducing epidural fibrosis and facilitating dissection in revision spinal surgery. Although the small sample size of the study limited the ability to generalize results, the authors believed that use of a dHACM barrier was clearly useful in limiting epidural fibrosis and promoting dissection in revision spinal surgery [17]. Similar results were observed in our population of women whereas in 14 of 15 cases having second look surgery no adhesions were observed where the dHACM was placed. In one case, filmy adhesions were observed on the dHACM, yet these were more easily dissected than adhesions in areas that had not been covered with dHACM. The use of dHACM was also reported in a case report where robotic repair of a vesicovaginal fistula in an irradiated field was described [18]. In that case, resolution of the fistula was confirmed after 3 weeks and no incontinence or recurrence had occurred at 5-month follow-up. No complications were observed.

The dHACM allograft is available in multiple configurations such as sheets, mesh or particulate and in various sizes to allow for its homologous use in a variety of internal and external clinical applications. The dehydrated allografts have no living cells, yet retain bioactivity with a 5-year shelf life under ambient conditions. We found the material to be easy to obtain and store. As previously reported [18], the material can be fragile and must be handled with care, although we have found that handling characteristics are acceptable for the microsurgery environment.

Weaknesses of our study are those characteristic of a retrospective, observational study. Our primary purpose was to describe our experience with using dHACM and evaluate handling characteristics for use in robotic surgery. Our routine practice of performing a second procedure within 2 weeks limits our ability to assess the use of dHACM on long-term outcomes such as reduction in rates of bowel obstruction, impact on fertility, or rates of adhesion recurrence. Future studies may better elucidate these outcomes and evaluate the cost and comparative effectiveness of using the dHACM material compared with other commercially available barriers.

## Conclusion

Inherent properties of amniotic membrane with the ability to modulate inflammation and reduce scar tissue formation suggest its clinical application as an adhesion barrier. We found the handling characteristics of dHACM allograft acceptable for use in our surgical technique and practice, with no adverse events identified during the follow-up period. Given our observations, we believe that using dHACM as an adhesion barrier is a safe and viable option for women undergoing laparoscopic procedures.

## References

1. Practice Committee of American Society for Reproductive Medicine in collaboration with Society of Reproductive Surgeons (2013) Pathogenesis, consequences, and control of peritoneal adhesions in gynecologic surgery; a committee opinion. *Fertil Steril* 99: 1550-1555.
2. John T (2003) Human amniotic membrane transplantation: past, present, and future. *Ophthalmol Clin North Am* 16: 43-65.
3. Tao H, Fan H (2009) Implantation of amniotic membrane to reduce postlaminectomy epidural adhesions. *Eur Spine J* 18: 1202-1212.
4. Toda A, Okabe M, Yoshida T, Nikaido T (2007) The potential of amniotic membrane/amnion-derived cells for regeneration of various tissues. *J Pharmacol Sci* 105: 215-228.
5. Parolini O, Solomon A, Evangelista M, Soncini M (2010) Human term placenta as a therapeutic agent: from the first clinical applications to future perspectives. *Human Placenta: Structure and Development*. Nova Science Publishers, Hauppauge, New York.
6. Koob TJ, Rennert R, Zabeck N, Masee M, Lim JJ, et al. (2013) Biological properties of dehydrated human amnion/chorion composite graft: implications for chronic wound healing. *Int Wound J* 10: 493-500.
7. Fetterolf DE, Snyder RJ (2012) Scientific and Clinical Support for the Use of Dehydrated Amniotic Membrane in Wound Management. *Wounds* 24: 299-307.
8. Hsu GS (2014) Utilizing Dehydrated Human Amnion/Chorion Membrane Allograft in Transcanal Tympanoplasty. *Otolaryngology* 4: 1-3.
9. Serena TE, Carter MJ, Le LT, Sabo MJ, DiMarco DT, et al. (2014) A multicenter, randomized, controlled clinical trial evaluating the use of dehydrated human amnion/chorion membrane allografts and multilayer compression therapy vs. multilayer compression therapy alone in the treatment of venous leg ulcers. *Wound Repair Regen* 22: 688-693.
10. Zelen CM, Serena TE, Denoziere G, Fetterolf DE (2013) A prospective randomized comparative parallel study of amniotic membrane wound graft in the management of diabetic foot ulcers. *Int Wound J* 10: 502-507.
11. Patel VR, Samavedi S, Bates AS, Kumar A, Coelho R, et al. (2015) Dehydrated Human Amnion/Chorion Membrane Allograft Nerve Wrap Around the Prostatic Neurovascular Bundle Accelerates Early Return to Continence and Potency Following Robot-assisted Radical Prostatectomy: Propensity Score-matched Analysis. *Eur Urol*.
12. Yetkin G, Uludag M, Citgez B, Karakoc S, Polat N, et al. (2009) Prevention of peritoneal adhesions by intraperitoneal administration of vitamin E and human amniotic membrane. *Int J Surg* 7: 561-565.
13. Binnebösel M, Rosch R, Junge K, Lynen-Jansen P, Schumpelick V, et al. (2008) Macrophage and T-lymphocyte infiltrates in human peritoneal adhesions indicate a chronic inflammatory disease. *World J Surg* 32: 296-304.
14. Koob TJ, Lim JJ, Masee M, Zabeck N, Denoziere G (2014) Properties of dehydrated human amnion/chorion composite grafts: Implications for wound repair and soft tissue regeneration. *J Biomed Mater Res B Appl Biomater* 102: 1353-1362.
15. van Hinsbergh VW, Kooistra T, Scheffer MA, Hajo van Bockel J, van Muijen GN (2014) Characterization and fibrinolytic properties of human omental tissue mesothelial cells. Comparison with endothelial cells. *Blood* 75: 1490-1497.
16. Koob TJ, Lim JJ, Masee M, Zabeck N, Rennert R, et al. (2014) Angiogenic properties of dehydrated human amnion/chorion allografts: therapeutic potential for soft tissue repair and regeneration. *Vasc Cell* 6:10.
17. Subach BR, Copay AG (2015) The use of a dehydrated amnion/chorion membrane allograft in patients who subsequently undergo reexploration after posterior lumbar instrumentation. *Adv Orthop* 2015:501202.
18. Price DT, Price TC (2015) Robotic repair of a vesicovaginal fistula in an irradiated field using a dehydrated amniotic allograft as an interposition patch. *J Robot Surg* 10: 77-80.