

Original Research Article**EVALUATION OF INTRAVITREAL BEVACIZUMAB FOR ITS SYSTEMIC SIDE EFFECT THROMBOSIS AFTER CHRONIC ADMINISTRATION****Anila Naz¹, Rahila Najam¹, Bushra Riaz², Arsalan Ahmed³**

1. Department of Pharmacology, Faculty of Pharmacy, University of Karachi, Karachi-75270, Pakistan.
2. Department of Pharmacology, Faculty of Pharmacy, Jinnah University for Women, Karachi, Pakistan.
3. Layton Rehmatullah Benevolent Trust, Lahore, Pakistan.

ABSTRACT:

Bevacizumab targets Vascular endothelial growth factor-A (VEGF-A). Bevacizumab specifically binds to the VEGF-A protein, thereby inhibiting the process of angiogenesis. Thrombosis and hypertension are the major systemic side effects of bevacizumab. As thrombosis and hypertension are the major systemic side effects of bevacizumab whether this drug could predispose a patient to thrombosis or not after intravitreal administration, as it is absorbed even through intravitreal administration. We determined the safety of the drug. This study was conducted at Al Ibrahim eye hospital for 3 months. The drug was intravitreally administered by Professor Dr. P.S. Mahar. For this 10 patients were administered three doses of intravitreal bevacizumab at monthly interval and followed for chronic effects of drug. Blood samples were taken to determine fibrinogen level, platelet count, prothrombin time (PT), activated partial thromboplastin time (APTT) and sodium level by kit method. Blood pressure was also monitored of all the patients before and after the drug administration. There has been significant decrease seen in fibrinogen level. Non-significant rise in the PT. Platelet counts decrease insignificantly. Slight increase is noted in sodium level. Slight increase is noted in diastolic blood pressure where as systolic blood pressure is insignificantly increased. Thus results of our study indicate that there may be bleeding tendency after bevacizumab so careful monitoring is required in patients receiving this drug, as well as monitoring of blood pressure is required.

KEYWORDS: Bevacizumab, thrombosis, intravitreal.

* Author for Correspondence: Bushra Riaz, Department of Pharmacology, Faculty of Pharmacy, Jinnah University for Women, Karachi, Pakistan. E.mail: doctor.bushra@hotmail.com

INTRODUCTION:

Bevacizumab is a humanized monoclonal antibody that targets Vascular endothelial growth factor-A (VEGF-A), an isoform of Vascular endothelial growth factor (VEGF) that is responsible for stimulating abnormal blood vessel growth and blood vessel leakage in disease like diabetic retinopathy and retinal vein occlusion. Its role in the cause and progression of choroidal neovascularization in neovascular age-related macular degeneration has become increasingly important, hence by specifically blocking VEGF, there is reduction in pathological angiogenesis.

Four major steps of angiogenesis have been recognized; namely vasodilation and hyper permeability, vessel destabilization and matrix degradation, endothelial cell proliferation and migration, lumen formation and vessel stabilization. Angiogenesis is a complex biological process involving a delicate balance and

interplay between a variety of molecular angiogenic and angiostatic factors. The VEGF-A is believed to be prime regulator of angiogenesis and takes part in all four stages of angiogenesis [1]. Intravitreal bevacizumab has been described in some recent articles for treatment of proliferative diabetic retinopathy complicated by vitreous hemorrhage [2], macular edema in central retinal vein occlusion, and neovascular age-related macular degeneration [3]. In vivo studies revealed that in human nonproliferative diabetic retinopathy there was increased expression of VEGF-A [4]. Upregulation of VEGFR-1, VEGFR-2 and VEGFR-3 was also observed [4,5].

The role of VEGF-A in the development of choroidal neovascularization has been established. Increased VEGF-A expression was noted in surgically excised choroidal neovascularization, retinal pigment epithelium and vitreous of age-related macular degeneration [6].

The permeability inducing actions of VEGF appear to induce the development of macular edema. VEGF may cause macular edema that accompanies diabetic retinopathy, retinal vein occlusion and uveitis. Human eyes with macular edema secondary to uveitis, retinal vein occlusion and diabetic retinopathy have shown increased retinal levels of VEGF [7]. When VEGF was blocked, blood-retinal barrier breakdown could be both prevented and reversed through VEGF inhibition.

Bevacizumab (Avastin) is full length, recombinant humanized Anti-VEGF monoclonal antibody that binds to all isoforms of VEGF-A. It binds directly to the VEGF ligand (which is expressed by both normal and tumor cells) to prevent its interaction with receptors on the surface of endothelial cells, thereby inhibiting the biologic activity of VEGF as observed in *in vitro* and *in vivo* assay systems [8].

Angiogenesis is an essential process in tumor development [9,10]. The VEGF ligand is the predominant regulator of tumor angiogenesis [10]. Avastin directly targets the VEGF ligand to specifically inhibit angiogenesis [11]. Maintaining VEGF ligand inhibition may prevent tumor vessel regrowth over time [12,13].

It is the FDA's approved Anti-VEGF agent in the treatment of patients with metastatic colorectal cancer [14], lung cancer, metastatic renal cell cancer (FDA, 2009), glioblastoma multiforme [15]. It has shown promising results, through intravitreal route in the treatment of neovascular ocular diseases like choroidal neovascularization, macular edema and diabetic retinopathy [16,17].

As thrombosis and hypertension are the major systemic side effects of bevacizumab whether this drug could predispose a patient to thrombosis or not after intravitreal administration, as it is absorbed even through intravitreal administration. We determined the safety of the drug.

Since no work has been carried out before on this issue in our local setup, this study would be important in decision making regarding the safety of intravitreal bevacizumab in choroidal and retinal neovascular disorders.

MATERIAL AND METHODS:

In order to evaluate the systemic side effects of intravitreal bevacizumab total 10 patients were selected. Patients were selected from Al Ibrahim eye hospital, meeting the inclusion and exclusion criteria receiving Bevacizumab (Avastin) injection. The purpose, procedure, risks and benefits of the study was explained to the patients. Informed consent was taken. In operation theater before injecting the intravitreal bevacizumab, eye ball was anesthetized with topical proparacaine drops sterilized with povidone iodine 5%.

Inclusion criteria:

Patients having neovascularization in retina and choroid of eye like diabetic retinopathy and age related macular degeneration diseases including both males and females having age above 40years. Hypertensive and non hypertensive,diabetic and non diabetic patients were included.

Exclusion criteria:

Patients having any hematological disorders like thrombosis. History of previous Bevacizumab injection.

Drug:

Patients received the drug Bevacizumab. This drug was intravitreally administered by Professor Dr.P.S.Mahar. The dose of intravitreal bevacizumab administered to the patient is 1.25mg in 0.05ml with 1ml syringe.

Experimental protocol:

These 10 patients were administered three doses of intravitreal bevacizumab at monthly interval and followed for chronic effects of drug. Blood samples were taken before and after one week of drug administration to determine fibrinogen level, platelet count, prothrombin time (PT), activated partial thromboplastin time (APTT) and sodium level by kit method. Blood pressure was also monitored of all the patients before and after the drug administration.

Sample collection:

Blood samples were collected in three types of tubes:

BD vacutainer EDTA.K2 tubes for collection of pure blood to study hematological parameter like platelet count.

Bio vac 3.2% sodium citrate tubes for collection of plasma to study coagulation parameters like PT and APTT and fibrinogen level. Prothrombin time and activated partial prothrombin time was checked manually using standard reagent kits of Diagnostica Stago France.

B-ject Gel clot activator vacuum tube for collection of serum to study sodium level.

After the collection of samples 3 ml of blood in 3.2% sodium citrate tubes, plasma was separated out and 4 ml of blood in Gel tubes, Serum was separated out, by centrifuging the blood samples in 800 centrifuge machine (china) at 4000 RPM for 5 minutes. The separated plasma and serum was stored in 2-8 °C and within 3 hours all the coagulation and electrolyte estimation were performed.

The estimation of platelet was directly done on automated MS4E Vet Hematology analyzer model# 3MSR0214 by Melet Schloesing Switzerland.

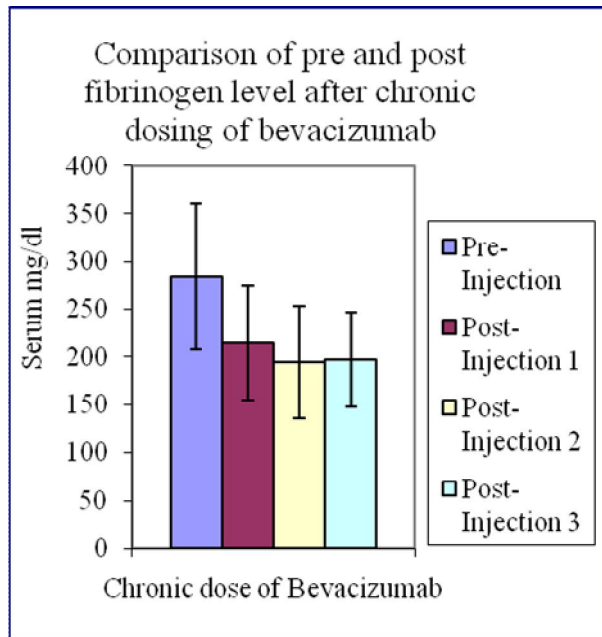
After separating the plasma the fibrinogen level was measured by humacloot duo (coagulation analyzer, model# 18650) (Human Germany) using standard reagent kits of Human Germany. Hemostat fibrinogen (manual and automated determination of plasma fibrinogen) was used [18].

Neoplastin CI Plus was used for the determination of prothrombin time [19]. C.K.Prest was used for the determination of Kaolin-activated partial thromboplastin time [20,21].

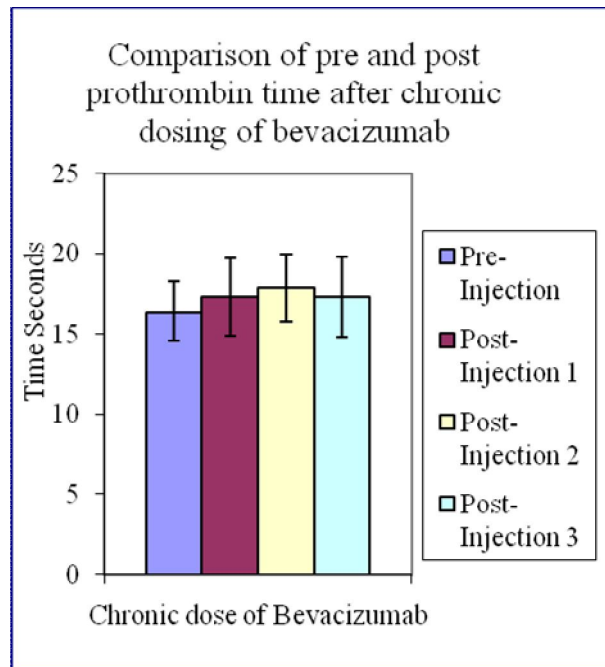
After separating the serum, the sodium level was measured by Microlab 300 semi-automated clinical chemistry analyzer by Merck Netherlands.

RESULT

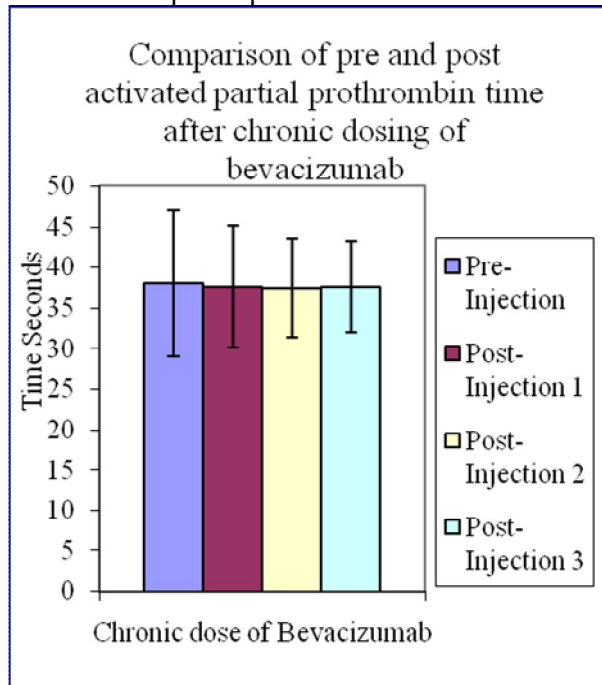
GRAPH-1:Effect of Bevacizumab on fibrinogen level



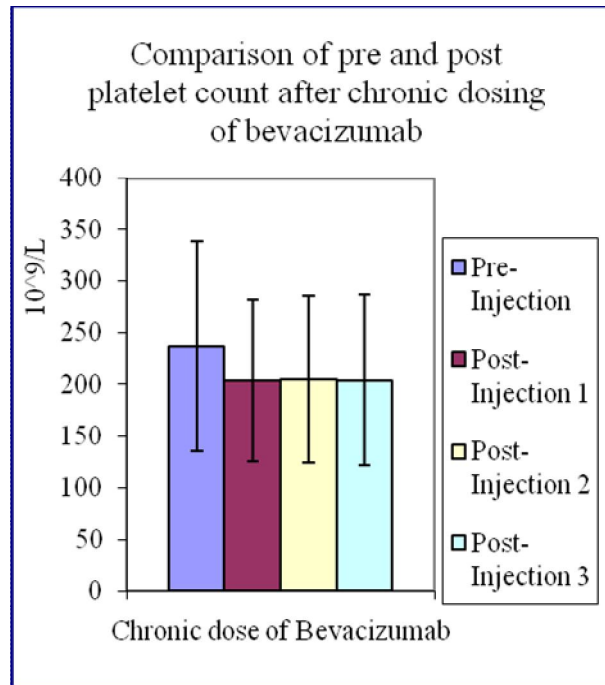
GRAPH-2:Effect of Bevacizumab on prothrombin time



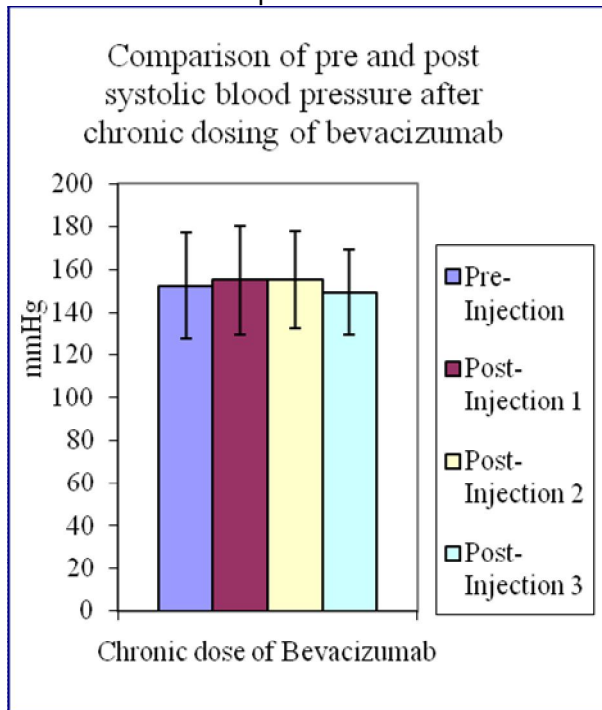
GRAPH-3:Effect of Bevacizumab on activated partial prothrombin time



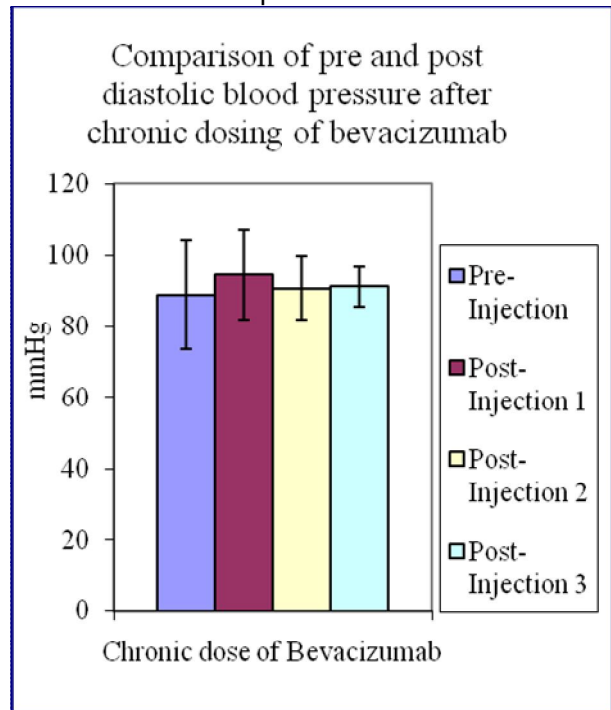
GRAPH-4:Effect of Bevacizumab on platelet count



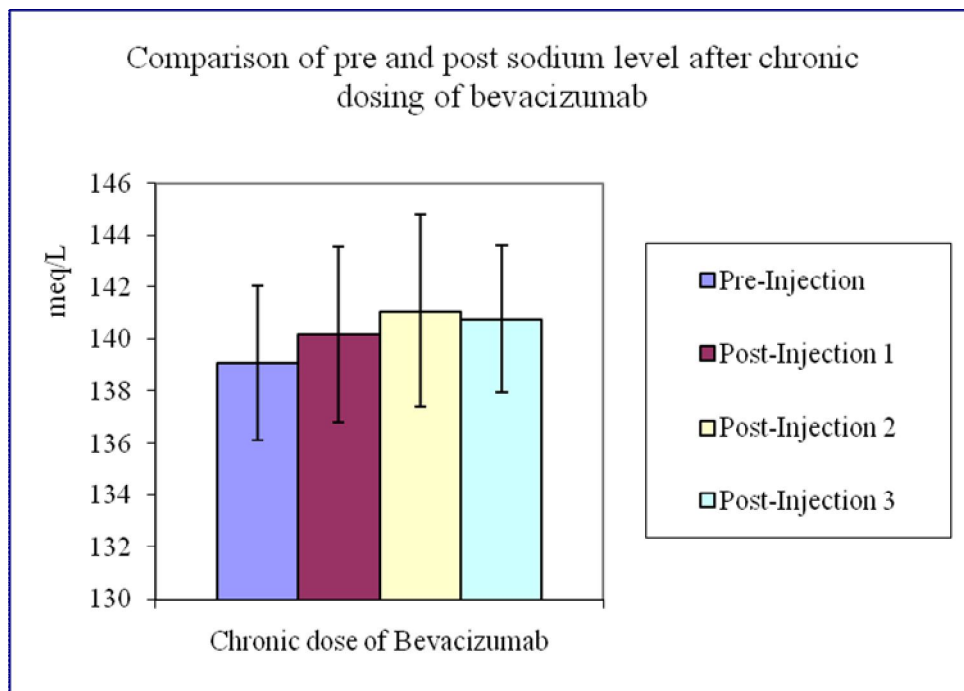
GRAPH-5:Effect of Bevacizumab on systolic blood pressure



GRAPH-6:Effect of Bevacizumab on diastolic blood pressure



GRAPH-7:Effect of Bevacizumab on sodium level



DISCUSSION

Scutz in the study reported that Bevacizumab treatment is associated with significant increase in the risk of arterial thrombosis[22]. In the present study, determination of fibrinogen level, platelet count, prothrombin time (PT), activated partial thromboplastin time (APTT) and sodium level was conducted by kit method. Blood pressure was also monitored of all the patients before and after the drug administration.

There has been significant decrease in the fibrinogen levels seen after chronic administration. Fibrinogen is a key protein in the coagulation pathway, interacting in multiple processes of platelet aggregation, clot formation and wound healing, and contributing to the final step of the coagulation cascade[23]. Low level of fibrinogen may lead to predisposition to bleeding. Thus if a patient receiving intravitreal bevacizumab have any history of thrombosis should receive chronic dosing of intravitreal bevacizumab.

There has been some rise in the PT but it is non-significant. Decreased level of fibrinogen and platelet count may be causing this rise of PT. The results of our study indicate that there is slight risk of bleeding after using intravitreal bevacizumab in neovascularization of choroid and retina. APTT is non-significantly decreased after the injection in chronic stages.

Platelet counts decrease after the injection. Platelets are meant for maintaining hemostasis. They help in wound healing and prevent bleeding. One physiological function of platelets may be to act as scavengers of circulating VEGF to restrict angiogenic activity to sites of wound healing. This may also be occurring in the pathological situation of neovascularization [24].

Slight increase is observed in sodium levels after the injection. Slight increase is noted in diastolic blood pressure. Insignificant increase is seen in systolic blood pressure. This increase in blood pressure may be associated with elevated level of sodium. Raiser *et al*, study supports our results, reporting that there is a risk of dysregulation of blood pressure or persistence of hypertension in hypertensive patients after intravitreal bevacizumab injections [25].

Mourad *et al.*, (2008) reported that bevacizumab treatment resulted in endothelial dysfunction and capillary rarefaction; both changes are closely associated and could be responsible for the rise in blood pressure observed in most patients [26].

The results of our study indicate that there may be bleeding tendency after bevacizumab because fibrinogen levels and platelet counts have decreased after chronic treatment, so careful monitoring is required in patients receiving this drug, as well as monitoring of blood pressure is required. In our study intravitreal administration of bevacizumab produced a slight increase in systolic and diastolic blood pressure. This work could be further extended to reassess the results with an increased sample size and also determine the effects in complicated patients having secondary problems.

REFERENCES:

1. Ferrara N. Vascular endothelial growth factor: molecular and biological aspects. *Curr Top Microbiol Immunol* 1999; 237:1-30.
2. Spaide RF, Fisher YL. Intravitreal bevacizumab (Avastin) treatment of proliferative diabetic retinopathy complicated by vitreous hemorrhage. *Retina* 2006 Mar; 26(3):275-8.
3. Rosenfeld PJ, Fung AE, Puliafito CA. Optical coherence tomography findings after an intravitreal injection of bevacizumab (avastin) for macular edema from central retinal vein occlusion. *Ophthalmic Surg Lasers Imaging* 2005; 36(4):336-9.

4. Caldwell RB, Bartoli M, Behzadian MA, El-Remessy AE, El-Shabrawey M, Platt DH, Caldwell RW. Vascular endothelial growth factor and diabetic retinopathy: pathophysiological mechanisms and treatment perspectives. *Diabetes Metab Res Rev* 2003; 19(6): 442-55.
5. Campochiaro PA. Retinal and choroidal neovascularization. *J Cell Physiol* 2000; 184 (3):301-10.
6. Witmer AN, Vrensen GF, Van Noorden CJ, Schlingemann RO. Vascular endothelial growth factors and angiogenesis in eye disease. *ProgRetin Eye Res* 2003 Jan;22(1):1-29.
7. Viores SA, Youssri AI, Luna JD, Chen YS, Bhargava S, Viores MA, Schoenfeld CL, Peng B, Chan CC, LaRochelle W, Green WR, Campochiaro PA. Upregulation of vascular endothelial growth factor in ischemic and non-ischemic human and experimental retinal disease. *HistolHistopathol* 1997;12(1):99-109.
8. Genentech, Inc. United States Securities and Exchange Commission. http://www.sec.gov/Archives/edgar/data/318771/000031877109000003/form10-k_2008.htm. accessed October6, 2009.
9. Bergers G & Benjamin LE. Tumorigenesis and the angiogenic switch. *Nat Rev Cancer* 2003; 3: 401-410.
10. Hicklin DJ, Ellis LM. Role of the vascular endothelial growth factor pathway in tumor growth and angiogenesis. *J ClinOncol* 2005;23(5):1011-27.
11. Presta LG, Chen H, O'Connor SJ, et al. Humanization of an anti-vascular endothelial growth factor monoclonal antibody for the therapy of solid tumors and other disorders. *Cancer Res* 1997;57(20):4593-9.
12. Mancuso MR, Davis R, Norberg SM, O'Brien S, Sennino B, Nakahara T, et al. Rapid vascular regrowth in tumors after reversal of VEGF inhibition. *J Clin Invest* 2006; 116(10):2610-21.
13. Vosseler S, Mirancea N, Bohlen P, Mueller MM, Fusenig NE. Angiogenesis inhibition by vascular endothelial growth factor receptor-2 blockade reduces stromal matrix metalloproteinase expression, normalizes stromal tissue, and reverts epithelial tumor phenotype in surface heterotransplants. *Cancer Res* 2005;65(4):1294-305.
14. Hurwitz H, Fehrenbacher L, Novotny W, Cartwright T, Hainsworth J, Heim W, et al. Bevacizumab plus irinotecan, fluorouracil, and leucovorin for metastatic colorectal cancer. *N Engl J Med* 2004; 350(23):2335-42.
15. Pollack, Andrew, FDA Panel supports Avastin to treat brain tumor. *New York Times* 2009.
16. Michels S, Rosenfeld JR, Puliafito CA, et al. Systemic bevacizumab (Avastin) therapy for neovascular age-related macular degeneration. Twelve-week results of an uncontrolled open-label clinical study. *Ophthalmology* 2005; 112:1035–1047.
17. Rosenfeld PJ, Moshfeghi AA, Puliafito CA, Optical coherence tomography findings after an intravitreal injection of bevacizumab (avastin) for neovascular age-related macular degeneration. *Ophthalmic Surg Lasers Imaging* 2005 Jul-Aug;36(4):331-5.
18. NCCLS Document H21-A3, Collection, transport and processing of blood specimens forcoagulationtestingand performance of coagulation assays. 1998; 18:20.
19. NCCLS Document H3-A5, Procedures for the collection of pecimens by venipuncture; approved standard. Sixth ed 2003; 23:32.
20. Langdell RD, Wagner RH &Brlnkhous KM. Effect of antihemophiic factor I on one-stage clotting tests. .1: *Lab. Clin. Med* 1953; 41:637-647.
21. Larrieu MJ and Weiland C, Use of cephalin in coagulation tests. *Rev Hematol* 1957; 12(2):199-210.
22. Schutz FA, Je Y, Azzi GR, Nguyen PL, Choueiri TK. Bevacizumab increases the risk of arterial ischemia. *Ann Oncol* 2011; 22(6): 1404- 12.
23. Koenig W. Fibrin(ogen) in cardiovascular disease: an update. *ThrombHaemost* 2003; 89(4):601-9.

24. Gunsilius E and Gast G. Platelets and VEGF blood levels in cancer patients. *Br J Cancer* 1999; 81(1): 185–186.
25. Rasier R, Artunay O, Yuzbasioglu E, Sengul A, Bahcecioglu H. The effect of intravitreal bevacizumab (avastin) administration on systemic hypertension. *Eye (Lond)* 2009; 23(8):1714-8.
26. Mourad JJ, des Guetz G, Debbabi H, Levy BI. Blood pressure rise following angiogenesis inhibition by bevacizumab. A crucial role for microcirculation. *Ann Oncol* 2008;19(5):927-34.