

# Evaluation of Progression of Ossification of Ligamentum Flavum in the Thoracic Spine Using Computed Tomography

Yan Wang, Chuiguo Sun, Zhongqiang Chen\* and Fabo Feng

Department of Orthopaedics, Peking University Third Hospital, No.49 North Garden Road, Beijing 100191, China

## Abstract

**Objective:** To evaluate the progression of Ossification of Ligamentum Flavum (OLF) in the thoracic spine based on cross-sectional Computed Tomography (CT) comparisons.

**Method:** OLF in spinal segments that did not require surgery because there were no cord compression of 17 patients who underwent laminectomies for treating symptomatic OLF were retrospectively reviewed (mean follow-up 6.3 years). Initial (preoperative or postoperative but before discharge) and final follow-up canal area unoccupied ratio (CAUR) of no-operated OLF were compared to evaluate the progression of OLF. Factors influencing OLF progression were also analyzed. Two-year follow-up and final follow-up results were assessed to evaluate the influence of OLF progression on long-term outcomes.

**Result:** Sixty OLF levels were compared between initial and final follow-up CT. The final follow up CAUR was significant lower than the initial in all OLF levels. Repeated measurement was used to reduce the effect of measurement error, and progression of OLF affected approximately 60% of patients and 33% of OLF segments, with annual growth rate in OLF area of 1.61%. CT mature/immature classification was an independent risk factor for the development of OLF. No patient exhibited neurological deterioration due to OLF progression.

**Conclusion:** Thoracic OLF that are not operated on still progress, and OLF classified as immature ossification on CT develop more significantly. Additionally, progression of OLF is not associated with neurologic regression in 5- 9 years follow-up, thus preventive laminectomy is unnecessary for OLF segments that do not compress the spinal cord.

**Keywords:** Ossification; Ligamentum flavum; Spiral computed tomography; Kyphosis; Progression

## Introduction

Thoracic spinal stenosis is mainly caused by ossification of the ligamentum flavum (OLF), ossification of the posterior longitudinal ligamentum (OPLL), and thoracic disk herniation [1-7]. Thoracic myelopathy induced by OPLL and OLF has been reported frequently in the Asian population [4,6,7]. Most studies of OPLL and OLF focus on the surgical technique and predictive factors of surgical outcomes [3,5,8,9], but the natural history of ossification of spinal ligaments is poorly understood. Progression of OPLL after decompressive surgery has been reported in a few studies [10-14], but a reasonable method to evaluate the growth of OLF, and evidence regarding whether OLF that do not compress the spinal cord should be scheduled or not for posterior surgery by laminectomy, are lacking. In this study we examined the computed tomography (CT) scans of non-operated thoracic OLF and evaluate the growth of OLF using a two-dimensional method. The potential influence of OLF progression on lower limb function was also assessed to provide clinical evidence for the extent of decompression.

## Materials and Methods

### Patients

Between January 2005 and December 2009, OLF in spinal segments that did not require surgery because there was no cord compression of 42 patients who underwent laminectomies for multiple ( $\geq 3$ ) symptomatic thoracic OLF were included; patients with OPLL, thoracic disk herniation, diffuse idiopathic skeletal hyperostosis (DISH), ankylosing spondylitis (AS), skeletal fluorosis, Kashin-Beck disease, and spine deformity were excluded.

### Measurement on radiography

We compared the initial (preoperative or postoperative but before discharge) thoracic X-ray scans with the final follow-up X-ray scans.

OLF levels were further classified as adjacent levels and no adjacent levels. The adjacent levels were defined as the three levels neighboring decompressed levels, and the kyphotic angle of adjacent levels means the Cobb angle between cephalic and caudal adjacent levels, but do not beyond the range from T4 to T12 owing to scapular occlusion on thoracic radiography (Figure 1). The adjacent levels in patients that underwent internal fixation were further defined as adjacent internal fixation levels. No adjacent levels, and adjacent levels but without internal fixation were defined as no adjacent internal fixation levels.

### Measurement on CT

Before 2010, CT examinations were performed using a 16-row CT system (Sensation 16; Siemens, Munich, Germany), with imaging conditions as follows: slice thickness, 3 mm; slice interval, 3 mm; collimation, 16 $\times$ 0.7. A 64-row CT system (SOMATOM Definition Flash; Siemens) was used from 2010, with imaging conditions as follows: slice thickness, 3 mm; slice interval, 3 mm; collimation: 64 $\times$ 2 $\times$ 0.6. Detector thickness in raw data was 0.7 mm in 16-row CT and 0.6 mm in 64-row CT. However, raw data prior to 2010 was deleted due to insufficient internal memory.

According to the scan position of no-operated OLF on the initial CT scan, the final follow-up CT cross-sectional scan was matched with the initial CT cross-sectional image using the axial 0.6-mm detector

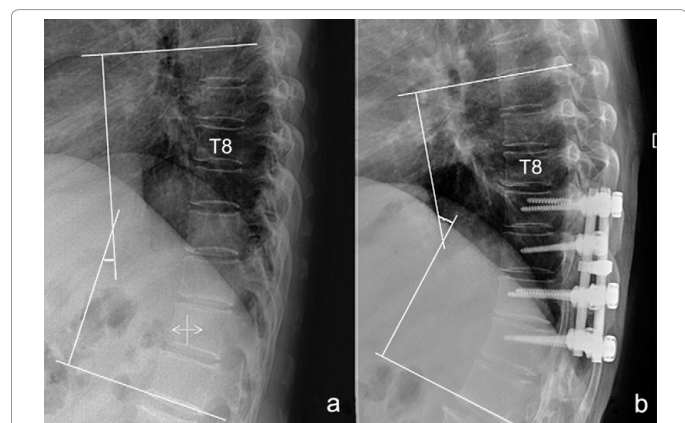
**\*Corresponding author:** Zhongqiang Chen, Professor, Department of Orthopaedics, Peking University Third Hospital, No.49 North Garden Road, Beijing 100191, China, Tel: +8610 82266391; Fax: +8610 62016928; E-mail: puh3\_czq@bjmu.edu.cn, zhongqiang0126@163.com

Received October 30, 2015; Accepted May 27, 2016; Published May 30, 2016

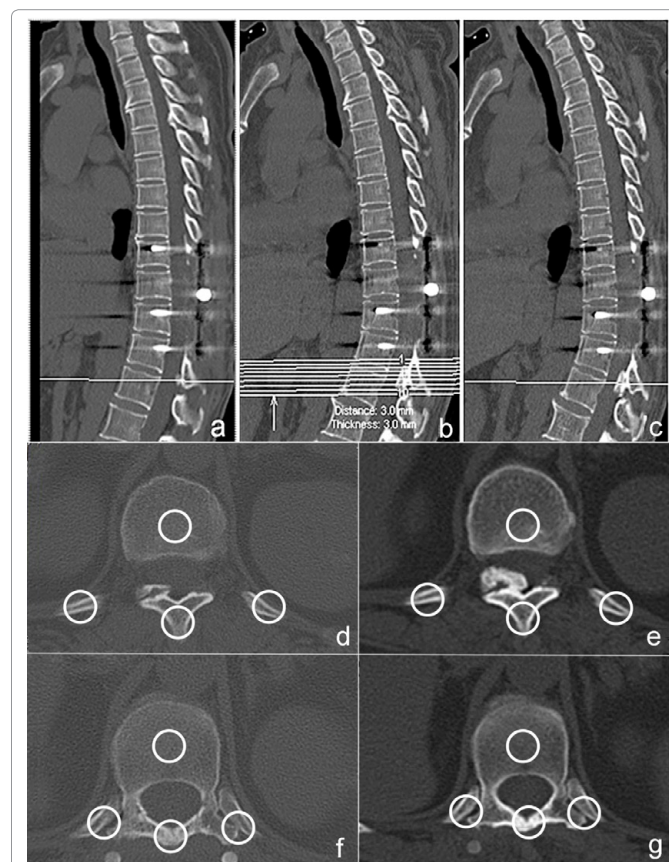
**Citation:** Wang Y, Sun C, Chen Z, Feng F (2016) Evaluation of Progression of Ossification of Ligamentum Flavum in the Thoracic Spine Using Computed Tomography. J Spine 5: 306. doi:10.4172/2165-7939.1000306

**Copyright:** © 2016 Wang Y, et al. This is an open-access article distributed under the terms of the Creative Commons Attribution License, which permits unrestricted use, distribution, and reproduction in any medium, provided the original author and source are credited.

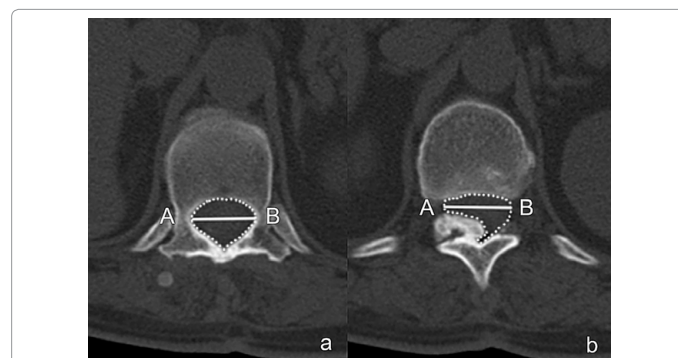
data reconstructed on a Syngo Multimodality Workplace (MMWP; Siemens) by 3-mm slice thickness and 3-mm interval (Figures 2a-2c). In the final follow-up cross-sectional reconstruction images, thoracic vertebrae, transverse process, lamina, spinous process, and ribs were used to create a match with the initial OLF cross-sectional images and obtain the comparable images of no-operated OLF scan (Figures 2d-2e) and pedicle scan corresponding to OLF in same level (Figures 2f-2g). OLF segment was divided into thoracic (T1–T9) and thoracolumbar segment (T10–L1).



**Figure 1:** Cobb angle of adjacent segments. (a) Preoperative Cobb angle of adjacent segments of T9–T12 OLF (ossification of ligamentum flavum). (b) Cobb angle of adjacent segments in final follow-up.



**Figure 2:** Obtain the comparable images. (a) Scan position of non-operated T12/L1 OLF in 2009. (b) Final follow-up CT scan was reconstructed to obtain the comparable images. (c) Location of final follow-up CT scan was same with Figure a. (d) T12/L1 OLF in 2009. (e) T12/L1 OLF in 2014. (f) Pedicle scan of T12/L1 OLF in 2009. (g) Pedicle scan of T12/L1 OLF in 2014.



**Figure 3:** Canal area was measured by Lasso Tool in Photoshop. (a) Developmental canal area. (b) AB was used to ascertain the boundary line to draw the unoccupied canal area. Canal area unoccupied ratio (CAUR) = area in b/area in a.

CT images of OLF were converted to computer-readable format (.tif), and the Lasso Tool in Adobe Photoshop version CS 5.0 (Adobe Systems, San Jose, CA) was used to measure the spinal canal area. The measurement parameters included (1) developmental canal area: the canal area was measured on the pedicle scan corresponding to OLF scan in same level; (2) unoccupied canal area: the canal area was measured on OLF scan, and the distance between the boundary lines of unoccupied canal area was equal to that of developmental canal area; and (3) canal area unoccupied ratio (CAUR), calculated as unoccupied canal area divided by developmental canal area (Figure 3). The difference in CAUR between initial and follow-up CT scans was calculated to evaluate the progression of OLF.

All measurements were obtained three times for each parameter at initial and final follow-up by a spine surgeon, and the average value of the three measurements was used. Two weeks later, 15 OLF segments were randomly selected and the CAUR was measured repeatedly by the same surgeon. The data of 15 OLF segments were compared with the first measurement results to evaluate the measurement deviation.

### Clinical data

CT mature/immature classification of OLF was characterized by the morphology of ossification on CT bone scan, which can be divided into mature and immature ossification [2,3,15]. Mature ossification was characterized by smooth ventral pattern, whereby the ossified part showed homogeneous high density and the unossified part was clearly visible underneath the ossified ligament with homogeneous low density (Figures 4e-4f). Immature ossification demonstrated inhomogeneous density without a clear boundary line between ossified and unossified areas (Figures 4a-4d). We also classified OLF into the following types according to the Sato classification: lateral, extended, enlarged, fused, and tuberosus [7].

Preoperative neurologic status, 2-year follow-up, and long-term outcomes were classified according to the modified Japanese Orthopaedic Association (JOA) score (11 points) for thoracic myelopathy.

### Statistical analysis

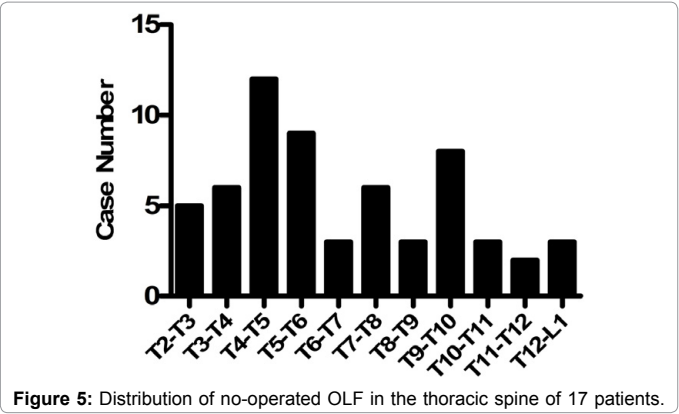
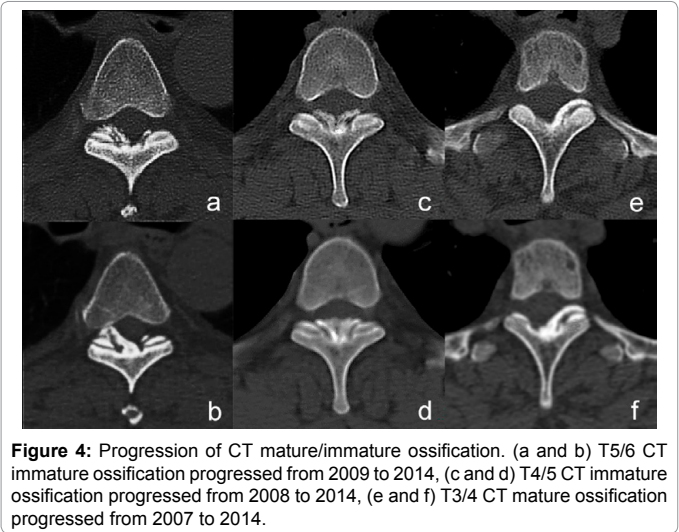
Continuous variables were described as means and standard deviations or ranges. Comparison between the initial and final follow-up CAUR was done by using paired *t* test. Student's *t* test and  $\chi^2$  test were used to evaluate the differences in the progression between mature ossification and immature ossification. Spearman rank correlation analysis was used to compare two sets of variables, such as increasing in Cobb angle and OLF progression. Binary logistic regression analysis

was used to identify the relationship between OLF progression and variable factors. Consistency of repeat measurement was evaluated by test-retest reliability.  $P < 0.05$  was considered as statistically significant. The software application used for the analysis was SPSS 18.0.

Results

Configuration of OLF

28 patients had a minimum follow-up period of 5 years, but



Parameter	Initial	Final follow-up	T value	P value	95% CI
CAUR	0.8635 ± 0.0940	0.8258 ± 0.1099	4.881	<0.001	0.0226–0.0505

Abbreviations: CAUR: Canal Area Unoccupied Ratio; CI: Confidence Interval.  
\*Values given are mean ± SD. Statistical significance was set at  $P < 0.05$

Table 1: Comparison of CAUR between the initial and final follow-up.

CT classification	Initial	Final follow-up	Difference	T value	P value
Mature OLF	0.8790 ± 0.0872	0.8575 ± 0.0984	0.0214 ± 0.0432	2.517	0.017
Immature OLF	0.8386 ± 0.1009	0.7747 ± 0.1102	0.0639 ± 0.0734		

Abbreviations: CAUR: Canal Area Unoccupied Ratio; CT: Computed Tomography; OLF: Ossification of Ligamentum Flavum.  
\*Values given are mean ± SD. Statistical significance was set at  $P < 0.05$

Table 2: Progression of CAUR in CT mature and immature ossification.

complete X-ray and CT history was available for 17 patients (8 men and 9 women), whose mean age was 54.6 years (range 40–67) at the time of operation. The mean follow-up period of these 17 patients was 6.3 years (range 5–9). We performed posterior decompression and internal fixation in 13 patients, including T7–T11(1), T9–T11(1), T10–T11(1), T8–T12(1), T9–T12(2), T10–T12(1), T11–T12(3), T9–L1, and T10–L1(2). Four patients were underwent simple decompression including T2–T7 (1), T2–T8 (1), T9–T11 (1), and T9–T12 (1).

A total of 60 OLF segments were matched to be measured on cross-sectional images. Sites of OLF that were not involved in laminectomy were T2/T3 (5), T3/T4 (6), T4/T5 (12), T5/T6 (9), T6/T7 (3), T7/T8 (6), T8/T9 (3), T9/T10 (8), T10/T11 (3), T11/T12 (2), and T12/L1 (3). Of these, 52 OLF were located in thoracic segment and 8 in thoracolumbar segment (Figure 5). Adjacent internal fixation levels and no adjacent internal fixation levels were 15 and 45, respectively. Based on the CT mature/immature classification, there were 34 mature ossifications and 26 immature ossifications. OLF categorized as lateral, extended, enlarged, fused, and tuberos types numbered 10, 19, 24, 5, and 2, respectively.

The final CAUR values were reduced in all OLF and were significantly lower than the initial values using paired  $t$  test ( $P < 0.05$ ) (Table 1). The progression of OLF was more significant in immature than in mature ossification, evaluated by the difference of CAUR between the initial and final follow-up results using Student's  $t$  test (Table 2).

Initial and final CAUR of 15 OLF segments were randomly selected for repeated measurement, and strong test-retest intraclass-correlations were observed (Pearson  $r = 0.993$ ,  $P < 0.05$ ). The average deviation of CAUR in repeated measurements was  $0.0120 \pm 0.0038$  ( $n = 30$ ). We defined the difference value of  $CAUR > 0.04$  between the initial and final follow-up, which was three times of the measurement deviation, as the evaluation standard for OLF progression. The results showed that 20 OLF developed in 10 cases, and the mean annual growth rate of area was 0.0161.

Using the evaluation standard defined as a difference value of  $CAUR > 0.04$ , a binary logistic regression analysis revealed that CT mature/immature classification was an independent risk factor for the development of OLF ( $P < 0.05$ ), while Sato classification, follow-up period, OLF segment, and adjacent levels classification were not ( $P > 0.05$ ) (Table 3).

The increase in Cobb angle of adjacent segments was  $9.11^\circ$  on average, and significantly correlated with decompression level numbers (Spearman  $r = 0.490$ ,  $P = 0.046$ ). There were 26 segments involved in adjacent segments, in which 9 OLF were observed to progress. Progression of OLF adjacent levels was not associated with increasing Cobb angle (Spearman  $r = 0.027$ ,  $P > 0.05$ ).

Clinical characteristics

The mean JOA score was  $6.82 \pm 1.81$  before surgery,  $8.58 \pm 1.62$  at 2 years' follow-up and  $8.53 \pm 1.62$  at the final follow-up visit. The lower limb motor function of modified JOA score was reduced from 3 to 2 in one patient, but this patient was not affected by OLF progression evaluated by the difference value of  $CAUR > 0.04$ . No patients exhibited any neurological deterioration due to OLF progression.

Discussion

Several investigators have reported the progression of OPLL after decompressive surgery. Onari [10], Kawaguchi [11], and Matsunaga [12] observed the progression of OPLL after laminoplasty

Variant	Factor	Classification		Variable assignment	$\beta$ value	OR value	P value
X1	CT classification	Immature (1)		1=23	2.182	8.863	0.005
		Mature (2)		2=37			
X2	Sato classification	Lateral (1)		1=10	-0.490	0.613	0.593
		Extended (2)		2=19	-1.212	0.298	0.171
		Fused (3)		3=5	-22.604	<0.001	0.999
		Tuberous (4)		4=2	-20.286	<0.001	0.999
		Enlarged (5)		5=24			
X3	Follow-up period				-0.423	0.655	0.244
X4	Adjacent level classification	adjacent fixation, (1)	internal	1=15	0.185	1.204	0.481
		No adjacent fixation(2)	internal	2=45			
X5	OLF segment	T1-T9 (1)		1=52	-1.596	0.203	0.177
		T10-L1 (2)		2=8			

Sato classification and adjacent segment classification were set by dummy coding and indicator method, and the last variable took the value of the reference group.

Abbreviations: CAUR: Canal Area Unoccupied Ratio; CT: Computed Tomography; OLF: Ossification of Ligamentum Flavum; OR: Odds Ratio.

Statistical significance was set at  $P < 0.05$

**Table 3:** Independent factors associated with OLF progression evaluated by CAUR difference  $> 0.04$ .

on radiographs. Using a novel CT-based three-dimensional analysis, Izumi [13] reported that an annual change in volume of OPLL of 3.33%. Sugita [14] demonstrated that the size of thoracic OPLL still increased on CT after spinal stabilization. Our study demonstrates for the first time the progression of thoracic OLF using two-dimensional measurement on cross-sectional CT.

### OLF progression on CT

OLF extends along the superficial layer of the hypertrophied ligament, arising from both the capsular and the interlaminar portion in which unossified tissue underneath the ossified lesions raises the ossified mass upward and toward the spinal canal [2,3]. There is no clear line between OLF and the facet joint and/or lamina, making direct measurement of OLF difficult on cross-sectional imaging. CT and MRI had been used to evaluate the grade of canal stenosis and predict surgical outcomes of OLF in several studies [1,4,16-18]. In this study, owing to the loss of historical data, a CT-based two-dimensional measurement was used to evaluate progression of OLF and we demonstrated non-operated OLF progressed. For the purpose of reducing the effect of measurement error, repeated measurement in 15 OLF was used to find the measurement deviation. Based on the principle that differences exceeding three times the deviation were statistically significant, we defined the difference value of CAUR  $> 0.04$  between the initial and final follow-up as the evaluation standard in OLF progression. Our results showed that the progression of OLF affected approximately 60% of patients and 33% of OLF segments, with an annual growth rate in OLF area of 1.61%.

Liu [17] and Feng [18] concluded that the residual area  $< 80\%$  can serve as a critical value for diagnosing OLF-induced myelopathy. In this study, the average value of CAUR being more than 80%, and it is possible that the progression of OLF is not enough to induce myelopathy for most patients in 5-9 years. An extensive search of the literature revealed only 2 previous well documented cases of late neurologic regression due to development of OLF in non-operated segments [5,6]. Sun [5] retrospectively reviewed 44 cases for average 8.3 years and found neurological deterioration in four cases due to the

growth of OLF at the adjacent levels, which occurred at 8,10,14,14 years after laminectomy respectively. Yonenobu [6] reported 7 in 26 cases became worse after laminectomy, in which 2 cases were caused by the progression of OLF and OPLL over more than 84 months. Nonetheless, our data suggested that OLF progression was a chronic and dynamic change, and no patient suffered from neurological deterioration due to OLF progression within 5-9 years. Although neurological regression was related with progression of non-operated OLF, it may experience a long period of time and show a rather low incidence [5,6]. As a result, we concluded that preventive decompression may be worthless, and it is unnecessary to perform laminectomy on OLF segments that do not compress the spinal cord, which prevent increasing the incidence of injury and operative complications, especially OLF almost affected the whole thoracic spine in some patients. However, progression of OLF should not be ignored, and a longer and regular follow-up is warranted.

### Factors influencing OLF progression

The pathogenesis and development of ossification in various spinal ligaments are diverse [19,20]. Patients with DISH, OPLL, AS, and skeletal fluorosis were not included in this study. Regarding pathologic characteristics, mature ossification consists of lamellar bone with homogeneous high density of ossified parts and homogeneous low density of unossified parts on CT [2,3,15], consistent with no signal on magnetic resonance imaging (MRI) [21]. Immature ossification is mainly composed of woven bone and has a poorly developed bone marrow structure, which displays inhomogeneous density without a clear boundary between ossified and unossified ossification on CT [2,3,15], corresponding to low and iso signals in MRI [21]. In our study, we found that CT mature/immature classification was an independent risk factor for the development of OLF, and immature ossification developed more significant than mature ossification. We consider the progression of ossification is associated with the activity of growth factors in the transition area of ossification [2,15,21].

Mechanical stress is an important etiologic factor in OLF, and local kyphosis and range of motion of the thoracic spine place stress on OLF [22,23]. Postoperative development of thoracic kyphosis is associated with destruction of the posterior element [6,8]. In our study, the mean increase in Cobb angle of adjacent segments was  $9.11^\circ$ , significantly correlating with the number of decompressed segments. Given that thoracic kyphosis might be influenced by changes in back extensor strength [24], we consider that back muscle damage may also aggravate the kyphosis, and that this may affect the adjacent levels as well as the decompressed segments. However, we did not find a significant effect of increasing Cobb angle and OLF segment on OLF progression. It is thought that development of OLF is slow and research with larger samples is required to improve the accuracy of our statistical analysis.

Our study has the following limitations: first, low incidence of OLF and long term follow-up result in small sample size. Second, it is difficult to directly measure OLF and to evaluate the continuity of OLF using a two-dimensional method. More accurate method of OLF measurement and larger samples are required in the future.

### Conclusion

Thoracic OLF still progress in non-operated segments, and OLF classified as immature on CT develop more significantly. Additionally, progression of OLF is not associated with neurologic regression in 5-9 years follow-up, and it is unnecessary to perform preventive laminectomy for OLF that do not compress the spinal cord.

### Financial and Material Support

None

## References

1. Sanghvi AV, Chhabra HS, Mascarenhas AA, Mittal VK, Sangondimath GM (2011) Thoracic myelopathy due to ossification of ligamentum flavum: a retrospective analysis of predictors of surgical outcome and factors affecting preoperative neurological status. *Eur Spine J* 20: 205-215.
2. Ono K, Yonenobu K, Miyamoto S, Okada K (1999) Pathology of ossification of the posterior longitudinal ligament and ligamentum flavum. *Clin Orthop Relat Res*: 18-26.
3. Okada K, Oka S, Tohge K, Ono K, Yonenobu K, et al. (1991) Thoracic myelopathy caused by ossification of the ligamentum flavum. *Clinicopathologic study and surgical treatment. Spine (Phila Pa 1986)* 16: 280-287.
4. Mori K, Kasahara T, Mimura T, Nishizawa K, Murakami Y, et al. (2013) Prevalence, distribution, and morphology of thoracic ossification of the yellow ligament in Japanese: results of CT-based cross-sectional study. *Spine (Phila Pa 1986)* 38: E1216-122.
5. Sun CG, Chen ZQ, Liu ZJ, Liu XG, Qi Q, et al. (2012) Longterm outcome after the decompressive surgery for thoracic myelopathy due to the ossification of the ligamentum flavum. *Zhonghua Wai Ke Za Zhi* 50: 426-429.
6. Yonenobu K, Ebara S, Fujiwara K, Yamashita K, Ono K, et al. (1987) Thoracic myelopathy secondary to ossification of the spinal ligament. *J Neurosurg* 66: 511-518.
7. Sato T, Kokubun S, Tanaka Y, Ishii Y (1998) Thoracic myelopathy in the Japanese: epidemiological and clinical observations on the cases in Miyagi Prefecture. *Tohoku J Exp Med* 184: 1-11.
8. Yu S, Wu D, Li F, Hou T (2013) Surgical results and prognostic factors for thoracic myelopathy caused by ossification of ligamentum flavum: posterior surgery by laminectomy. *Acta Neurochir (Wien)* 155: 1169-1177.
9. Yang Z, Xue Y, Dai Q, Zhang C, Zhou HF, et al. (2013) Upper facet joint en bloc resection for the treatment of thoracic myelopathy caused by ossification of the ligamentum flavum. *J Neurosurg Spine* 19: 81-89.
10. Onari K, Akiyama N, Kondo S, Toguchi A, Mihara H, et al. (2001) Long-term follow-up results of anterior interbody fusion applied for cervical myelopathy due to ossification of the posterior longitudinal ligament. *Spine (Phila Pa 1986)* 26: 488-449.
11. Kawaguchi Y, Kanamori M, Ishihara H, Nakamura H, Sugimori K, et al. (2001) Progression of ossification of the posterior longitudinal ligament following en bloc cervical laminoplasty. *J Bone Joint Surg Am* 83-83A: 1798-802.
12. Matsunaga S, Sakou T, Taketomi E, Nakanishi K (1996) Effects of strain distribution in the intervertebral discs on the progression of ossification of the posterior longitudinal ligaments. *Spine (Phila Pa 1986)* 21: 184-189.
13. Izumi T, Hirano T, Watanabe K, Sano A, Ito T, et al. (2013) Three-dimensional evaluation of volume change in ossification of the posterior longitudinal ligament of the cervical spine using computed tomography. *Eur Spine J* 22: 2569-2574.
14. Sugita S, Chikuda H, Takeshita K, Seichi A, Tanaka S (2014) Progression of ossification of the posterior longitudinal ligament of the thoracic spine following posterior decompression and stabilization. *J Neurosurg Spine* 21: 773-777.
15. Zhou F, Dang GT (2014) The matched control study between medical imaging and pathologic findings in ossification of the ligamentum flavum of the thoracic spine. *Chin J Orthop* 6: 346-349.
16. Yoon SH, Kim WH, Chung SB, Jin YJ, Park KW, et al. (2011) Clinical analysis of thoracic ossified ligamentum flavum without ventral compressive lesion. *Eur Spine J* 20: 216-222.
17. Liu N, Chen ZQ, Qi Q (2007) Correlation between spinal canal encroachment and neurologic deficits in thoracic ossification of ligamentum flavum. *Chin J Orthop* 7: 481-484.
18. Feng F, Sun C, Chen Z (2015) A diagnostic study of thoracic myelopathy due to ossification of ligamentum flavum. *Eur Spine J* 24: 947-954.
19. Ehara S, Shimamura T, Nakamura R, Yamazaki K (1998) Paravertebral ligamentous ossification: DISH, OPLL and OLF. *Eur J Radiol* 27: 196-205.
20. Kassem M, Mosekilde L, Eriksen EF (1994) Effects of fluoride on human bone cells in vitro: differences in responsiveness between stromal osteoblast precursors and mature osteoblasts. *Eur J Endocrinol* 130: 381-386.
21. Sakamoto R, Ikata T, Murase M, Hasegawa T, Fukushima T, et al. (1991) Comparative study between magnetic resonance imaging and histopathologic findings in ossification or calcification of ligaments. *Spine (Phila Pa 1986)* 16: 1253-1256.
22. Otani K, Aihara T, Tanaka A, Shibasaki K (1986) Ossification of the ligamentum flavum of the thoracic spine in adult kyphosis. *Int Orthop* 10: 135-139.
23. Cai HX, Yayama T, Uchida K, Nakajima H, Sugita D, et al. (2012) Cyclic tensile strain facilitates the ossification of ligamentum flavum through  $\beta$ -Catenin, signaling pathway. *Spine (Phila Pa 1986)* 37: E639-E646.
24. Mika A, Unnithan VB, Mika P (2005) Differences in thoracic kyphosis and in back muscle strength in women with bone loss due to osteoporosis. *Spine (Phila Pa 1976)* 30: 241-246.