

Fatal Tension Pneumopericardium in an Extremely Low Birth Weight Infant to Identify the Perforation Site of the Pericardium

Daisuke Muto, Hiroki Kakita*, Satoru Takeshita, Hiroko Ueda, Tatenobu Goto and Yasumasa Yamada

Department of Perinatal and Neonatal Medicine, Aichi Medical University, Japan

*Corresponding author: Hiroki Kakita, Department of Perinatal and Neonatal Medicine, Aichi Medical University, 1-1 Yazako, Karimata, Nagakute, Aichi 480-1195, Japan, Tel: 81 561 62 3311; Fax: 81 561 61 1864; E-mail: hkaki1019@yahoo.co.jp, kakita.hiroki.898@mail.aichi-med-u.ac.jp

Rec date: Jan 27, 2016, Acc date: Feb 11, 2016, Pub date: Feb 15, 2016

Copyright: © 2016 Muto D, et al. This is an open-access article distributed under the terms of the Creative Commons Attribution License, which permits unrestricted use, distribution, and reproduction in any medium, provided the original author and source are credited.

Abstract

A pneumopericardium is a very rare condition and is the least common form of air leak in neonates. A tension pneumopericardium is associated with very high mortality. Neonatal pneumopericardium is usually a complication of mechanical ventilation in premature infants with respiratory distress syndrome. The mechanism of this rare condition and the perforation site of the pericardium have largely been speculative. This case report documents an extremely low birth weight infant who developed fatal tension pneumopericardium, and the autopsy revealed airflow into the pericardial sac through a perforation site of the pericardium near the ostia of the right pulmonary vein. This is a valuable case in which the perforation site of the pericardium was confirmed.

Keywords: Air leak syndrome; Pneumopericardium; Extremely low birth weight infant

Abbreviation

RDS: Respiratory Distress Syndrome

Introduction

Pneumopericardium is a very rare condition and is the least common form of air leak in neonates. A tension pneumopericardium is associated with very high mortality [1,2]. Neonatal pneumopericardium is usually a complication of mechanical ventilation in premature infants with respiratory distress syndrome (RDS). The mechanism of this rare condition and the perforation site of the pericardium have largely been speculative. The case of an extremely low birth weight infant who developed fatal tension pneumopericardium, in which the mechanism was suggested by identification of the perforation site of the pericardium, is described.

Case Report

An 848-g male was born at a gestational age of 25 weeks by emergency caesarean section following threatened premature delivery and premature rupture of the membranes. Antenatal maternal steroids had not been given. His Apgar scores were 7 and 8 at 1 and 5 min, respectively. The infant was intubated immediately after birth, followed by intratracheal administration of surfactant due to RDS. After stabilizing his cardiopulmonary condition, during transportation of the infant from the operating room to the Neonatal Intensive Care Unit with bag and mask ventilation adjusted by manometer, he suddenly deteriorated with profound hypoxemia and bradycardia. The cardiorespiratory deterioration was unresponsive to ventilator adjustment, catecholamines, and prolonged cardiopulmonary resuscitation. A chest X-ray showed an extensive pneumopericardium (Figure 1). Pericardiocentesis was performed under ultrasound guidance, and air drained with transient restoration of blood pressure

and saturation. At the age of 7 hours, he died, after repeated exacerbation and remission of his cardiorespiratory status.

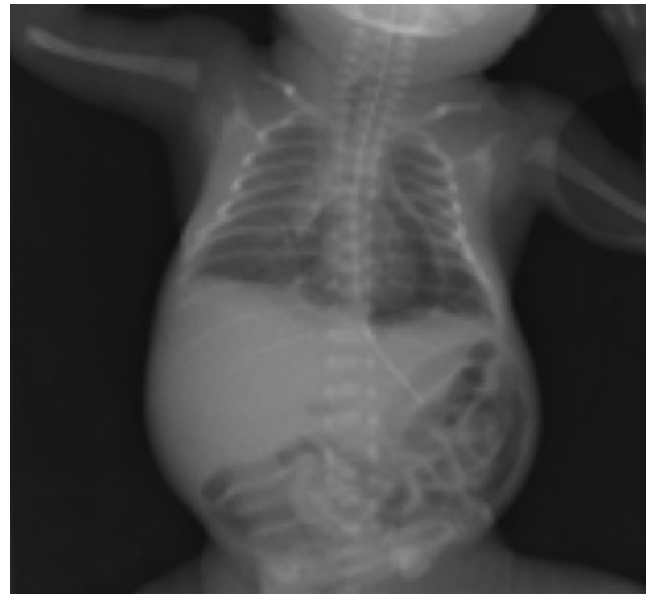


Figure 1: Chest radiograph.

An autopsy was performed. Macroscopically, there were two structurally normal lungs and a significantly expanded heart (Figure 2A). No perforation was found in the upper airway tract. The pericardial cavity was full of foamy air, with no pericardial effusion. To identify the inflow site of the air, we injected air into the trachea, and there was airflow into the pericardial sac through the perforation site (2 mm) of the pericardium near the ostia of the right pulmonary vein (Figure 2B). Microscopic examination showed extensive interstitial pulmonary emphysema with acute hyaline membranes.

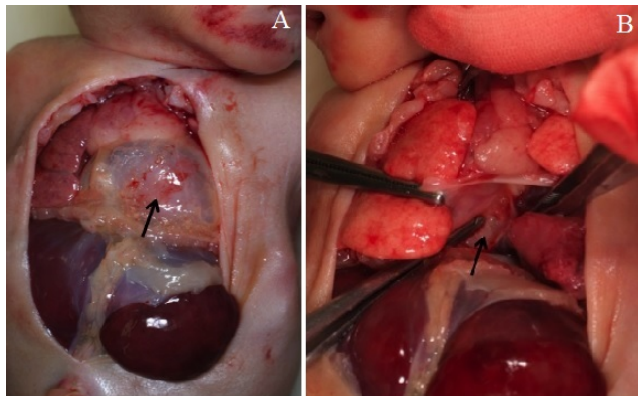


Figure 2: Pneumopericardium at postmortem analysis. 2A. Expanded heart (arrow). 2B. The perforation site of the pericardium (arrow) perforation.

Discussion

Air leak syndrome occurs in 1% to 2% of all newborns [1,2]. It is a well-known complication of positive pressure ventilation in the fragile and immature lung. Therefore, air leak syndrome occurs more commonly during the neonatal period than at any other age, and the incidence is inversely related to birthweight [1,2]. Air leak syndrome is defined as the phenomenon in which air escapes from the tracheobronchial tract and collects in various spaces where it is not normally present. The escaping air tracks along various pathways and localizes in different body spaces leading to different types of air leaks, including pulmonary intestinal emphysema, pneumothorax, pneumomediastinum, pneumopericardium, pneumoperitoneum, subcutaneous emphysema, and systemic air embolism [1-3]. Pneumopericardium is the least common form of air leak syndrome, but it is nevertheless associated with high mortality [1-3]. Preterm infants in particular in comparison with fullterm infants are not enough for cardiac function, a pulmonary function [4]. Prompt identification and treatment are extremely important to reduce morbidity and mortality, especially in preterm infants.

Pneumopericardium in the present case could have been due to mask and bag ventilation for RDS, and ineffective pericardial drainage might have led to the patient's death. Most cases of pneumopericardium are secondary to rupture of pulmonary alveoli bordering pulmonary vessels due to mechanical ventilation. The air

dissects to the hilum along the peribronchovascular sheaths and spreads into the mediastinum and further to the pericardium [2,3]. The inflow site of air into the pericardium has been speculative. Mansfield et al. demonstrated a site of potential weakness at the reflection of the parietal onto the visceral pericardium, near the ostia of the pulmonary veins in histological preparations [5]. They suggested indirectly that air or other substances that dissected through the appropriate layer of the perivascular sheaths could enter the pericardial sac with relative ease at this site of reflection [5,6]. However, there have been no reports that demonstrated the inflow site of air into the pericardium. The autopsy revealed the perforation site near the ostia of the right pulmonary veins, as previously reported [5], and the air injected into the trachea went into the pericardium through this perforation site. In the present case, although the site of pulmonary alveolus rupture could not be confirmed, the air went from the pulmonary alveolus rupture into the mediastinum and then entered the pericardium through this potential site of weakness. To the best of our knowledge, this is the first report to identify the perforation site of the pericardium in a case of pneumopericardium on autopsy.

In conclusion, the pericardial perforation site in an extremely low birth weight infant who developed fatal tension pneumopericardium was demonstrated. This is an important case because the perforation site of the pericardium was confirmed and thus improves our understanding of the pathology of pneumopericardium.

References

1. Jeng MJ, Lee YS, Tsao PC, Soong WJ (2012) Neonatal air leak syndrome and the role of high-frequency ventilation in its prevention. *J Chin Med Assoc* 75: 551-559.
2. Kyle A, Veldtman G, Stanton M, Weeden D, Baral V (2012) Barotrauma-associated posterior tension pneumomediastinum, a rare cause of cardiac tamponade in a ventilated neonate: a case report and review of the literature. *Acta Paediatr* 101: e142-e144.
3. Heckmann M, Lindner W, Pohlandt F (1998) Tension pneumopericardium in a preterm infant without mechanical ventilation: a rare cause of cardiac arrest. *Acta Paediatr* 87: 346-348.
4. Ciccone MM, Scicchitano P, Zito A, Gesualdo M, Sassara M, et al. (2011) Different functional cardiac characteristics observed in term/preterm neonates by echocardiography and tissue doppler imaging. *Early Hum Dev* 87: 555-558.
5. Mansfield PB, Graham CB, Beckwith JB, Hall DG, Sauvage LR (1973) Pneumopericardium and pneumomediastinum in infants and children. *J Pediatr Surg* 8: 691-699.
6. el Gamel A, Barrett P, Kopff G (1994) Pneumopericardium: a rare cause of cardiac tamponade in an infant on a positive pressure ventilation. *Acta Paediatr* 83: 1220-1221.