

## Fenestrated Duodenal Membrane in a Girl with Down Syndrome and Celiac Disease

Virtut Velmishi<sup>1\*</sup>, Saimir Heta<sup>2</sup>, Adnan Demrozi<sup>2</sup>, Marjeta Tanka<sup>3</sup> and Spiro Sila<sup>2</sup>

<sup>1</sup>Service of Pediatric Gastroenterology, Mother Teresa Hospital, Tirana, Albania

<sup>2</sup>Service of Pediatric Surgery, Mother Teresa Hospital, Tirana, Albania

<sup>3</sup>Service of Imagery, Mother Teresa Hospital, Tirana, Albania

\*Corresponding author: Virtut Velmishi, Department of Pediatric Gastroenterology, Mother Teresa Hospital, Dibra Street, Nr 370, Tirana, Albania, Tel: 00355672057335; E-mail: [tutimodh@yahoo.com](mailto:tutimodh@yahoo.com)

Rec date: Mar 16, 2016, Acc date: Apr 11, 2016, Pub date: Apr 13, 2016

Copyright: © 2016 Velmishi V, et al. This is an open-access article distributed under the terms of the Creative Commons Attribution License, which permits unrestricted use, distribution and reproduction in any medium, provided the original author and source are credited.

### Abstract

**Background:** Fenestrated duodenal membrane is a form of congenital duodenal webs in whom the diagnosis is missed or delayed often.

**Case presentation:** We will present the case of a two-year-old girl diagnosed at birth with Down syndrome and 12 month old she was diagnosed with celiac disease. After gluten free diet this girl presented a good weight gain but her mother referred that last months she was vomiting frequently. Her mother denied to have seen bilious vomiting but she noticed in vomiting some kind of foods swallowing one or two weeks ago. Radiological images were confident with duodenal obstruction. After surgical laparotomy we noticed a fenestrated duodenal membrane.

**Discussion:** Fenestrated duodenal membrane is a rare congenital disorder. Sometimes the diagnostic may be delayed when the symptoms are not characteristic or dedicated to a different pathology. In our case nonbilious vomiting and celiac disease made us to underestimate initially this congenital anomaly.

**Conclusion:** Every child with Down syndrome should be evaluated for rare digestive disorder despite of no characteristic signs or the presence of another digestive pathology. Surgery remains the gold standard of therapy.

**Keywords:** Fenestrated duodenal membrane; Down syndrome; Celiac disease

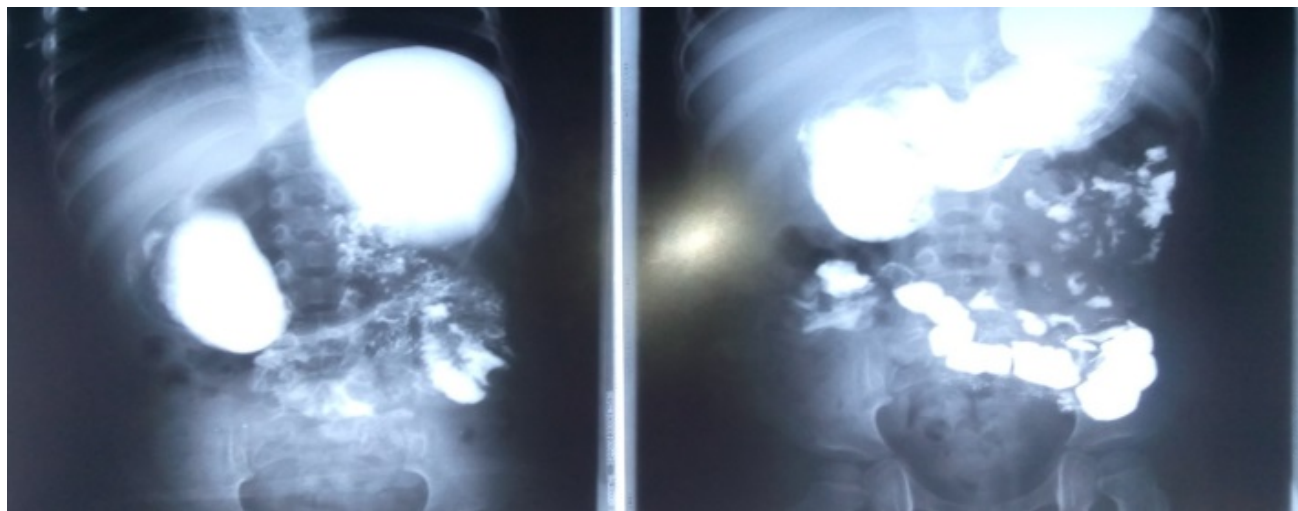
### Introduction

The incidence of duodenal obstruction has been reported as 1 in 6000-1000 live births by various authors. In a series of congenital intrinsic duodenal obstructions by Fronkalsurd et al., atresia was reported in 49%, membranes in 41% and stenosis in 10% of cases [1]. Reports of different authors vary quoting the incidence of duodenal membranes from 0.8 % to 92% [2-4].

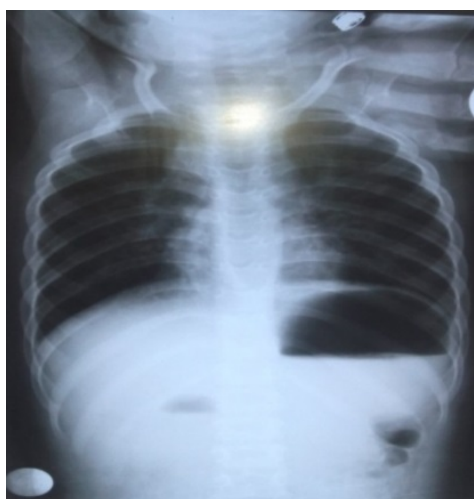### Case Presentation

We would like to present a two-year-old girl diagnosed at birth with Down syndrome. She was the second child. Her mother referred a normal pregnancy and a normal delivery. She was breast fed for six months. After this period of time she presented vomiting and diarrhoea time by time. She was admitted to therapy intensive care at age of 12 months because of severe dehydration. She had not heart anomaly but we noticed a severe malnutrition. After stabilisation in therapy intensive unit she was transferred to our service of paediatric gastroenterology. Blood count showed anaemia Hb = 7, 4 g/dl; ferritin level was low, albumine was 2, 4 mg/dl. Thyroid function was normal. Abdominal ultrasonography was inconclusive. Liver and kidney tests

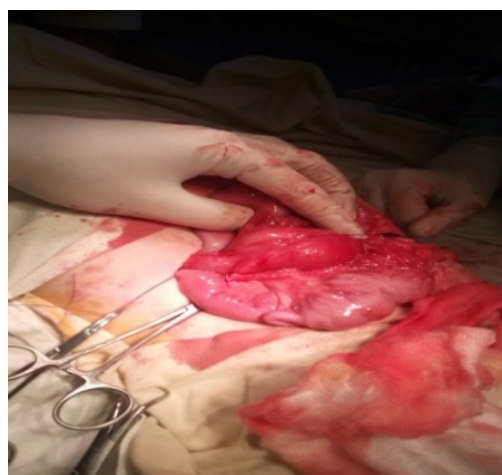were also uneventful. Serology for celiac disease was 10 fold upper the normal limit. We started immediately gluten free diet. Amelioration of symptoms and a good weight gain make us to discharge that girl at home. We have followed her for six months in frequents appointments confirming a good weight gain, a normal level of hemoglobin, decreased level of antitransglutaminase and reduction of symptoms like diarrhoea and vomiting. Last three months according to her mother she presented non bilious vomiting. The most interesting thing was that her mother has noticed in her vomits foods like cherry core consummated a week ago. We hospitalised again this girl continuing with specific examination. An abdominal ultrasonography showed a large stomach. An abdominal X-ray showed a minimal hydro level mimicking a double bubble (Figure 1). We decided to perform also an upper GI contrast study which showed a large stomach and dilatation of upper part of duodenum (Figure 2). In consultation with our surgeons we decide to perform a laparotomy. During laparotomy we have seen a large stomach continuing to a large D1, D2 separated by a zone to a normal part of duodenum (Figure 3). After a lateral duodenotomy, we have seen a large membrane 6 mm in front of papilla vater with a small space confirming fenestrated duodenal membrane (Figure 4). The duodenotomy was closed transversely. After surgery this girl did not require supportive intensive care. We started oral feeding after 5 days. She was perfect without fever, nausea or vomiting. She was discharged at home 10 days after intervention.



**Figure 1:** Dilatation of upper part of duodenum in an upper GI contrast study (windssock sign).



**Figure 2:** Small hydrolevel giving double bubble image.



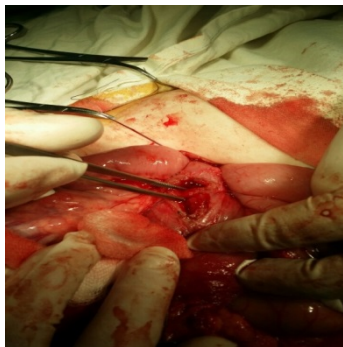
**Figure 3:** Images of large part of duodenum and the continuing part.

## Discussion

As you have seen in this case report fenestrated duodenal membranes may present as late infancy or childhood or occasionally even adulthood [5]. The fenestrated membrane may be choked with food residue or foreign body. In our case her mother noticed in her vomits foods eaten by her daughter one week ago like cherry core. Some of the symptoms of this girl were underestimated due to another digestive pathology as celiac disease. When we had a normal level of transglutaminin which means a good control of celiac disease we had a deterioration of vomiting. This made us to check a contrast study casting a doubt for duodenal obstruction.

Some studies have reported non bilious vomiting as the most common presenting feature [6-8]. In our case the lack of bilious vomiting was one cause of delayed diagnosis but this occurs when the location of anomaly is preampullary [9,10]. The most common site of location is the first and second parts [7,8].

The duodenotomy should be made in the lateral wall in the distal segment near the membrane. The membrane should be excised with electrocautery leaving the medial part in order to avoid injury to the Papilla of Vater. A proximal "mega-duodenum" (duodenal diameter of 5 cm or more) may require imbrications or a tapering duodenoplasty procedure to avoid prolonged duodenal ileus [11].



**Figure 4:** Image of a large duodenal membrane 6-7 mm with a small fenestrated part.

The use of trans anastomotic tube for enteral feeding is controversial with no advantage being noted by some authors. In our case we didn't use this kind of feeding and the postoperative period was without complications. We had not use also prokinetic agents because their value is also doubtful in most patients.

## Conclusion

Every child with Down syndrome should be evaluated for rare digestive disorder despite of noncharacteristic signs or the presence of another digestive pathology. Surgery remains the gold standard of therapy.

## References

1. Fonkalsrud EW, DeLorimier AA, Hays DM (1969) Congenital atresia and stenosis of the duodenum. A review compiled from the members of the Surgical Section of the American Academy of Pediatrics. *Pediatrics* 43: 79-83.
2. Escobar MA, Ladd AP, Grosfeld JL, West KW, Rescorla FJ, et al. (2004) Duodenal atresia and stenosis: longterm follow-up over 30 years. *J Pediatr Surg* 39: 867-871.
3. Waever E, Neilsen OH, Arnbjornsson E, Kullendorff CM (1995) Operative management of duodenal atresia. *Pediatr Surg Int* 10: 322-324.
4. Krieg EG (1937) Duodenal diaphragm. *Ann Surg* 106: 33-41.
5. Ferraris VA, McPhail JF (1984) Adult duodenal web associated with peptic ulcer disease. *Surg Gynecol Obstet* 158: 461-463.
6. Mikaelsson C, Arnbjörnsson E, Kullendorff CM (1997) Membranous duodenal stenosis. *Acta Paediatr* 86: 953-955.
7. Applebaum H, Lee SL, Puapong DP (2006) Duodenal Atresia and Stenosis. *Pediatric Surgery* 6: 1260-687.
8. Richardson WR, Martin LW (1969) Pitfalls in the surgical management of the incomplete duodenal diaphragm. *J Pediatr Surg* 4: 303-312.
9. Rowe MI, Buckner D, Clatworthy HW Jr (1968) Wind sock web of the duodenum. *Am J Surg* 116: 444-449.
10. Adzick NS, Harrison MR, deLorimier AA (1986) Tapering duodenoplasty for megaduodenum associated with duodenal atresia. *J Pediatr Surg* 21: 311-312.
11. Sarkar S, Apte A, Sarkar N, Sarkar D, Longia S (2011) Vomiting and food refusal causing failure to thrive in a 2 year old: an unusual and late manifestation of congenital duodenal web. *BMJ Case Rep*.