

Fine Needle Aspirate and Cytology (FNAC) as Useful Tool in the Diagnosis of Suspected Tuberculous Lymphadenitis in Rwanda, 2009

Uwimana I¹, Gatabazi JB¹, Mukabayire O¹, Bigirimana V², Ngendahayo L³, Mubako TVK⁴ and Stevens MH⁵

¹Rwanda Biomedical Center/National Reference Laboratory, Kigali, Kigali City, Rwanda

²King Faisal Hospital, Kigali/Rwanda

³University Teaching Hospital (CHUB)/Butare-Rwanda

⁴University of Maryland School of Medicine-Institute of Human Virology (UMSOM-IHV), Rwanda Program

⁵IMA (ASCP), University of Maryland School of Medicine-Institute of Human Virology (UMSOM-IHV), Rwanda Program

*Corresponding author: Innocent Uwimana, Rwanda Biomedical Center/National Reference Laboratory, Kigali, Kigali City, Rwanda, Tel: 250 7883119545; E-mail: uwinnocent@gmail.com

Received date: January 31, 2016 Accepted date: March 8, 2016; Published date: March 20, 2016

Copyright: © 2016 Uwimana I, et al. This is an open-access article distributed under the terms of the Creative Commons Attribution License, which permits unrestricted use, distribution, and reproduction in any medium, provided the original author and source are credited

Abstract

Background: The number of people infected with tuberculosis is gradually increasing in Rwanda. The diagnosis of suspected Tuberculous Lymphadenitis (TL) is still difficult to diagnose and remain expensive when applying surgical procedures.

Objective: To study the usefulness of fine needle aspirates in diagnosis of TL in patients from a low income country.

Methods: Triplicate smears from lymph node aspirates were prepared. Air-dried smears were stained by hot ZN staining technique for AFB examination, and Gram staining technique for exclusion of any bacterial infection and Papanicolaou staining technique was done for cytological to detect malignant cells and other pathology. Slides were examined by laboratory technologist and pathologist respectively.

Results: A total number of 138 specimens from suspected TL patients were analyzed, of which 14 (10.1%) were ZN positive while cytology revealed 25 (18.1%) cases of TB lymphadenitis. From Papanicolaou stain 25 (18.1%) cases were either supportive for TB (7.2%) cases or suspicious for TB (10.9%) while 113 (81.9%) there was no features for TB. Among 25 cases which were supportive or suspicious for TB only 6 cases (4.3%) were also ZN positive and 19 (13.8%) were ZN negative. Cytology revealed also 19 (13.8%) cases of reactive nodes, 25 (18.1%) accounted for other pathologies and 33 (23.9%) were inadequate samples for analysis and interpretation. Gram stain showed 2 (2.7%) cases of Gram positive cocci.

Conclusion: In low income countries, the use of FNA cytology with more training should be considered as a useful tool in diagnosis of TL instead of biopsy applying surgical procedures.

Introduction

Tuberculosis (TB) is an infectious disease caused by various strains of mycobacterium, mainly by *Mycobacterium tuberculosis* in humans, it has been present in humans since antiquity [1]. TB is a chronic, progressive infectious with a period of latency following initial infectious. It occurs most commonly in the lungs. Pulmonary symptoms include productive cough, chest pain, and dyspnea. Tuberculosis is the leading infectious cause of morbidity and mortality in adults worldwide, killing about 2 million people every year [2]. Sub-Saharan Africa is disproportionately burdened by tuberculosis and multidrug resistant tuberculosis infection. Extra-pulmonary Tuberculosis is common in patients with HIV/AIDS [3].

Tuberculous lymphadenitis (TL) is a chronic specific granulomatous inflammation with caseation necrosis of the lymph node. Suspected TL is difficult to diagnose and remains expensive when applying surgical procedures and becomes easier to diagnose and less traumatic when applying fine needle aspiration and cytology technique [4].

In Rwanda, the number of people infected with tuberculosis is increasing. In 2009, the Ministry of health through the National Reference Laboratory in collaboration with University of Maryland, School of Medicine (UMSOM) introduced a new technique; the fine needle aspiration and cytology (FNAC) to help in the diagnosis of suspected TL one form of the extra-pulmonary tuberculosis. The technique applies a fine gauge needle which is inserted into a nodule to withdraw material and cells. The cells are studied under microscope [5, 6]. The fine needle aspiration and cytology technique is quick, safe, cheap and effective for the diagnosis of TL. The technique is less traumatic than an open surgical biopsy, and significant complications are usually rare, depending on the body site [7]. We aimed to evaluate the usefulness of the fine needle aspirates to diagnose TL in patients from a low-income country.

Keywords Fine needle aspirate and cytology (FNAC); Extrapulmonary tuberculosis; Tuberculous Lymphadenitis; Ziehl Neelsen stain; Papanicolaou stain

Materials and Methods

Fine needle aspiration and cytology technique: The technique uses a needle gauge of 23-25 G that is inserted into the lymph node and a certain amount of material is withdrawn. The cells are studied under the microscope by a cytologist or a pathologist. This method is commonly used to determine whether a nodule in the mass is benign or malignant[8]. In this technique, a thin, hollow needle is inserted into the mass of a lymph node to extract cells that, after being stained, will be examined under a microscope.

Inclusion and exclusion criteria: All patients presenting with any mass including lymph node, axial or inguinal mass was included and complying with TB signs and symptoms such as night sweat, fatigue, weight loss and or presenting other signs that is likely to be TB suspect. Were excluded any case without the above-mentioned signs and symptoms especially absence of lymph node, inguinal or axial mass nodes.

Specimens collection, laboratory techniques and results interpretation: We collected lymph node fluid from suspected patients and made smears on separate slides. A total number of 138 specimens were collected from the lymph nodes of suspected patients to have TL. Specimens were collected from out patients attending District Hospitals in TB Department, seeking for TB treatment and presenting any enlarged mass including lymph nodes, inguinal or axial masses. Triplicate smears were prepared from lymph node aspirates for each specimen and from each patient. All smears were air-dried and stained with hot Ziehl Neelsen (ZN) stain for acid-alcohol fast bacilli (AAFBs) examination by a laboratory technologist. To exclude any bacterial infection, if pus was present on site of sample collection, Gram stain was performed while Papanicolaou stain for cytology was used to detect features of TL, malignant cells and other pathologies. All laboratory procedures were performed as described previously elsewhere[9, 10].

Triplicate smears were labeled and stained as follow: Slide #1, slide #2, and slide #3. On the slide number one, we applied hot ZN method to identify acid-alcohol fast bacilli (AAFBs). With the slide number two, we used Papanicolaou staining technique to identify tuberculous lymphadenitis features and other pathology[11]. Finally, slide number three was stained with Gram stain technique to exclude other bacterial infections if pus was present at the time of sample collection. The ZN and Gram stained slides were screened under microscope at 100x by a laboratory technologist while the slides stained by Papanicolaou technique were examined under microscope at 10x and 40x by a pathologist.

Results

The majority of the patients tested were aged between 10 to 40 years old. The age group of 10 to 25 years represent 27.5% while the age group of 26 to 40 years represent 30.4%.

Ziehl Neelsen stain results: A total number of 138 fine needle aspiration and cytology (FNAC) have been collected, processed and stained using ZN staining technique. Among 138 specimens, ZN stain yields positive results in 14 cases which represent 10.1% for Acid Alcohol Fast Bacilli (AAFBs). In 116 (84.1%) cases a ZN stain was done and yielded negative results for AAFBs. In 8 (5.8%) cases either ZN was not done or it could not be ascertained whether a ZN stain was done Figure 1.

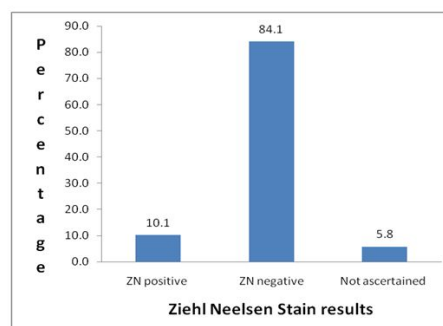


Figure 1: Results of smear microscopy by Ziehl Neelsen staining technique

Gram stain results: Out of 138 specimens collected, only 73 (52.9%) specimens contained pus at the site specimen collection and were analyzed after Gram stain was done. Among 73 specimens where pus was present, the Gram stain results showed only 2 cases (2.7%) that were positive and the two samples contained Gram positive cocci and Gram negative bacilli respectively. In 71 (97.3%) cases, the Gram stain yield a negative result Figure 2.

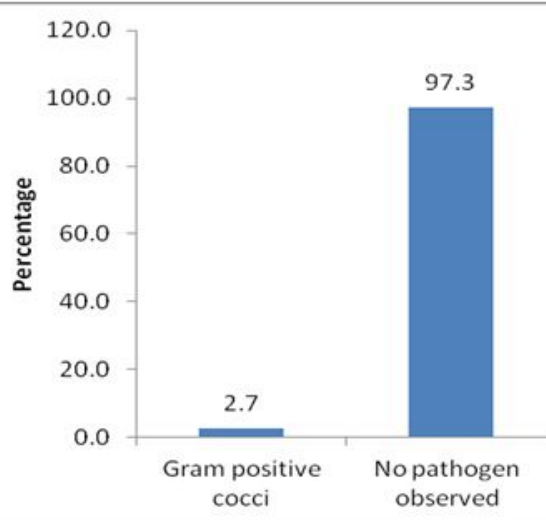


Figure 2: Results of smear microscopy by Gram staining technique

Fine needle aspiration and cytology (FNAC) on lymph node results: Among 138 FNAC specimens collected, 25 (18.1%) cases are TL. A total number of 19 (13.8%) cases show reactive node or inflammatory features in the lymph node. Inadequate samples for any diagnostic interpretation were observed in 33 (23.9%) cases while 20 (14.5%) cases were indeterminate. A total number of 25 (18.1%) cases show evidence of other pathology outside tuberculosis (including lymphoma, other malignancy benign masses and abscess). The category of "other pathologies" included 3 cases of breast carcinomas, 8 cases of lymphomas, 9 other malignancies, 2 abscesses, 3 benign

lesions including (probable salivary gland cysts, and epidermal inclusion cysts Table 1.

Cytology features	n	%
Tuberculous Lymphadenitis	25	18.1
Reactive node	19	13.8
Inadequate samples	33	23.9
Indeterminate	20	14.5
Unremarkable lymphoid tissue	16	11.6
Other pathologies	25	18.1
Breast carcinomas	-3	-
Lymphomas	-8	-
Abscesses	-2	-
Benign lesions (probable salivary gland cysts, and epidermal inclusion cysts)	-3	-
Other malignancies	-9	-
Total	138	100

Table 1: Overall Fine Needle Aspirate and Cytology (FNAC) results

Cytology features of Tuberculous Lymphadenitis: To confirm a patient as having tuberculosis, the presence of acid fast bacilli (AFBs) on smear is compulsory. However, on the FNA Cytology we considered some features that are associated with tuberculosis on cytology interpretation. Among those features, include: caseous necrosis, presence of Langerhans giant cells and granulomas on a necrotic background. A diagnosis of tuberculous lymphadenitis was made when

smears showed all the three characteristics of tuberculous lymphadenitis (caseous necrosis, presence of Langerhans giant cells and granulomas on a necrotic background). All the above features if present on smear, we considered a case to be supportive or consistent with TL. A case was considered as highly consistent with tuberculosis or definitive for tuberculosis if all those features were present and if we observed AAFBs on the smear. The sample was qualified as suspicious if the two of the three features were present. Finally, a negative slide was considered if there were no features for TL when there was any feature of the three characteristics mentioned above. A total number of 10 (7.2%) cases were supportive for TL while 15 (10.9%) cases were suspicious for TL. There were no features for tuberculosis in 113 (81.9%) cases Table 2. Similar results were found elsewhere in the world with in the studies conducted to diagnose TL [12-15]

Features for tuberculosis	n	%
Supportive for tuberculosis	10	7.2
Suspicious for tuberculosis	15	10.9
No features for tuberculosis	113	81.9

Table 2: Cytology features of tuberculous lymphadenitis

Papanicolaou results vs. Ziehl Neelsen results: In 6 (4.3%) cases, Papanicolaou stain was supportive to the definitive diagnosis of tuberculosis in the presence of a Ziehl Neelsen positive result. In 19 (13.8%) cases the diagnosis is TL through cytology examination by Papanicolaou stain was raised by cytological features on Papanicolaou stain in the presence of a negative ZN result. A total number of 105 (76.0%) cases on Papanicolaou stain did not show any features of tuberculous lymphadenitis and the ZN was also negative. Only 8 (5.7%) cases were positive with Ziehl Neelsen while negative on the basis of Papanicolou stain features Table 3.

Papanicolaou Results	ZN Positive	ZN Negative	Total
	n(%)	n(%)	n(%)
Tuberculous	6(4.3)	19(13.8)	25(18.1)
Non tuberculous lymphadenitis	8(5.7)	105(76.0)	113(81.9)

Table 3: Papanicolaou results compared to Ziehl Neelsen (ZN) results

Discussion

The age distribution among tested patients shows that the active age is more represented 10 to 40 years (57.9%). The Fine needle aspiration and cytology is important technique, and is useful for patient who cannot provide sputum. The fine needle aspiration and cytology is helpful in the diagnosis of one form of extra-pulmonary tuberculosis, tuberculous lymphadenitis.

The ZN staining technique reveals 10.1% while Papanicolaou shows 18.1% of positive results taken separately. The Gram stain results help to exclude or confirm bacterial infection. When we compared the FNAC technique to the ZN staining technique, the FNAC is a complementary technique. The cytology results complement ZN results. The FNAC provides more information while compared to ZN staining technique since it reveals other pathologies such as breast

carcinomas, lymphomas, benign and malignant lesions, abscesses, and other malignancies (table 4). Only the presence of acid fast bacilli (AFBs) confirms tuberculosis, however, features observed on the fine needle aspirates and cytology that are associated with tuberculosis are helpful to diagnose tuberculosis. Those features include: caseous necrosis, presence of Langerhans giant cells and granulomas on a necrotic background as described previously [16]. To qualify a smear as TL, or to diagnosis tuberculosis while using Fine needle Aspirate and cytology, one should consider the following four features: (1) Tuberculosis: Acid Alcohol Fast Bacilli (AAFBs) must be present, (2) Consistent with tuberculosis: AAFBs may not be seen but multiple features of tuberculosis at least three of them, (3) Suggestive or supportive for tuberculosis: No AAFBs seen but few features at least two features of tuberculosis, (4) Negative for tuberculosis: No AAFBs seen and no features of tuberculosis (table 4).

Diagnosis	Features
Tuberculosis	AAFBs seen
Consistent with tuberculosis	No AAFBs seen but multiple features of tuberculosis at least three of them.
Suggestive or supportive for tuberculosis	No AAFBs seen but few features at least two features of tuberculosis.
Negative for tuberculosis	No AAFBs seen and no features of tuberculosis.

Table 4: Features qualification supporting tuberculosis diagnosis

Other pathology diagnosed by FNAC: The cytology analysis was also able to diagnose other pathologies other than tuberculosis such as malignant or benign cells and reactive nodes. The cytology provides more information from one single sample. For the patient who cannot provide sputum, the FNAC is indicated as cheap and quick technique to be used in the country with low resources-income. Increased number of inadequate samples (23.9%) might be due to inadequate training of nurses and/or clinicians who collected samples and performed the smearing technique (table 1).

Study limitation: Bacterial culture technique using Lowenstein Jensen (LJ) is considered as gold standard even though it takes several weeks to months to get results[17, 18]. In the present study, solid culture using Lowenstein Jensen (LJ) was not performed on all samples which prevent us to compute sensitivity, specificity, positive and negative predictive values for all samples.

Conclusion and recommendations

In low-income countries Fine needle aspiration and cytology is useful to diagnose TL instead of biopsy applying surgical procedures. The technique is less expensive, quick, safe and effective while compared to the biopsy that requires expensive material, equipment, and more time and pathologist specialist for the interpretation. It can be recommended to the District Hospital testing package as routine technique in low settings. However, more training is needed to reduce the number of inadequate samples on collection time which might interfere with results interpretation. We recommend further study with large sample size with emphasis on sensitivity, specificity positive and negative predictive to assess the performance of FNAC against Smear microscopy using either Ziehl Neelsen or Fluorescence Microscopy in the diagnosis of Tuberculous Lymphadenitis.

Acknowledgement

University of Maryland School of Medicine ,Ministry of Health/Rwanda,NationalReference Laboratory, King Faysal Hospital, University Teaching Hospital/Kigali, University Teaching Hospital/Butare,District hospitals (all)

References

- Crofton J, Horne N, Miller F (1993) Tuberculose clinique. *UICTMR*: 150-164.
- Beers M.H (2006) The Merck Manual of Diagnosis and Therapy (18th ed.). Merck & Co Inc.
- Mbuayang AP (1999) Epidemiology and proposed diagnosis of tuberculosis in Africa : the case of Cameroon.Edited by: Vrije Universiteit Brussel, thesis of Master degree, Faculty of Medicine & Pharmacy.
- Nayak S, Mani R, Kavatkar AN, Puranik SC, Holla VV (2003) Fineneedle aspiration cytology in lymphadenopathy of HIV-positive patients. *Diagn Cytopathol* 29: 146-148.
- Medici M, Liu X, Kwong N, Angell TE, Marqusee E, et al. (2016) Long-versus short-interval follow-up of cytologically benign thyroid nodules: a prospective cohort study. *BMC Med* 14: 11.
- Prasad R, Garg SK, Mukerji PK, Agarwal PK (1993) Role of fine needle aspiration cytology in the diagnosis of lymphadenopathy. *Indian J Chest Dis Allied Sci* 35: 27-29.
- Saboorian MH, Ashfaq R (2001) The use of fine needle aspiration biopsy in the evaluation of lymphadenopathy. *Semin Diagn Pathol* 18: 110-123.
- Roskell DE, Buley ID (2004) Fine needle aspiration cytology in cancer diagnosis. *BMJ* 329: 244-245.
- Getachew A, Tesfahunegn Z (1999) Is fine needle aspiration cytology a useful tool for the diagnosis of tuberculous lymphadenitis? *East Afr Med J* 76: 260-263.
- Gupta RK, Naran S, Lallu S, Fauck R (2003) The diagnostic value of fine needle aspiration cytology (FNAC) in the assessment of palpable supraclavicular lymph nodes: a study of 218 cases. *Cytopathology* 14: 201-207.
- Lakhey M, Bhatta CP, Mishra S (2009) Diagnosis of tubercular lymphadenopathy by fine needle aspiration cytology, acid-fast staining and mantoux test. *JNMA J Nepal Med Assoc* 48: 230-233.
- Nayak S, Mani R, Kavatkar AN, Puranik SC, Holla VV (2003) Fineneedle aspiration cytology in lymphadenopathy of HIV-positive patients. *Diagn Cytopathol* 29: 146-148.
- Sarma PK, Chowhan AK, Agrawal V, Agarwal V (2010) Fine needle aspiration cytology in HIV-related lymphadenopathy: experience at a single centre in north India. *Cytopathology* 21: 234-9.
- Bezabih M, Mariam DW, Selassie SG (2002) Fine needle aspiration cytology of suspected tuberculous lymphadenitis. *Cytopathology* 13: 284-290.
- Perenboom RM, Richter C, Swai AB, Kitinya J, Mtoni I, et al. (1994) Diagnosis of tuberculous lymphadenitis in an area of HIV infection and limited diagnostic facilities. *Trop Geogr Med* 46: 288-292.
- Haque MA, Talukder SI (2003) Evaluation of fine needle aspiration cytology (FNAC) of lymph node in Mymensingh. *Mymensingh Med J* 12: 33-35.
- Laifangbam S, Singh HL, Singh NB, Devi KM, Singh NT (2009) A comparative study of fluorescent microscopy with Ziehl-Neelsen staining and culture for the diagnosis of pulmonary tuberculosis. *Kathmandu Univ Med J (KUMJ)* 7: 226-230.
- Srisuwanvilai LO, Monkongdee P, Podewils LJ, Ngamlert K, Pobkeeree V, et al. (2008) Performance of the BACTEC MGIT 960 compared with solid media for detection of Mycobacterium in Bangkok, Thailand. *Diagn Microbiol Infect Dis* 61: 402-407.