

## Focal Fibrous Hyperplasia

Hector R Martinez Menchaca<sup>1</sup> and Gerardo Rivera Silva<sup>2\*</sup>

<sup>1</sup>Department of Orthodontics, Pediatric Dentistry and Special Care, University of Louisville, USA

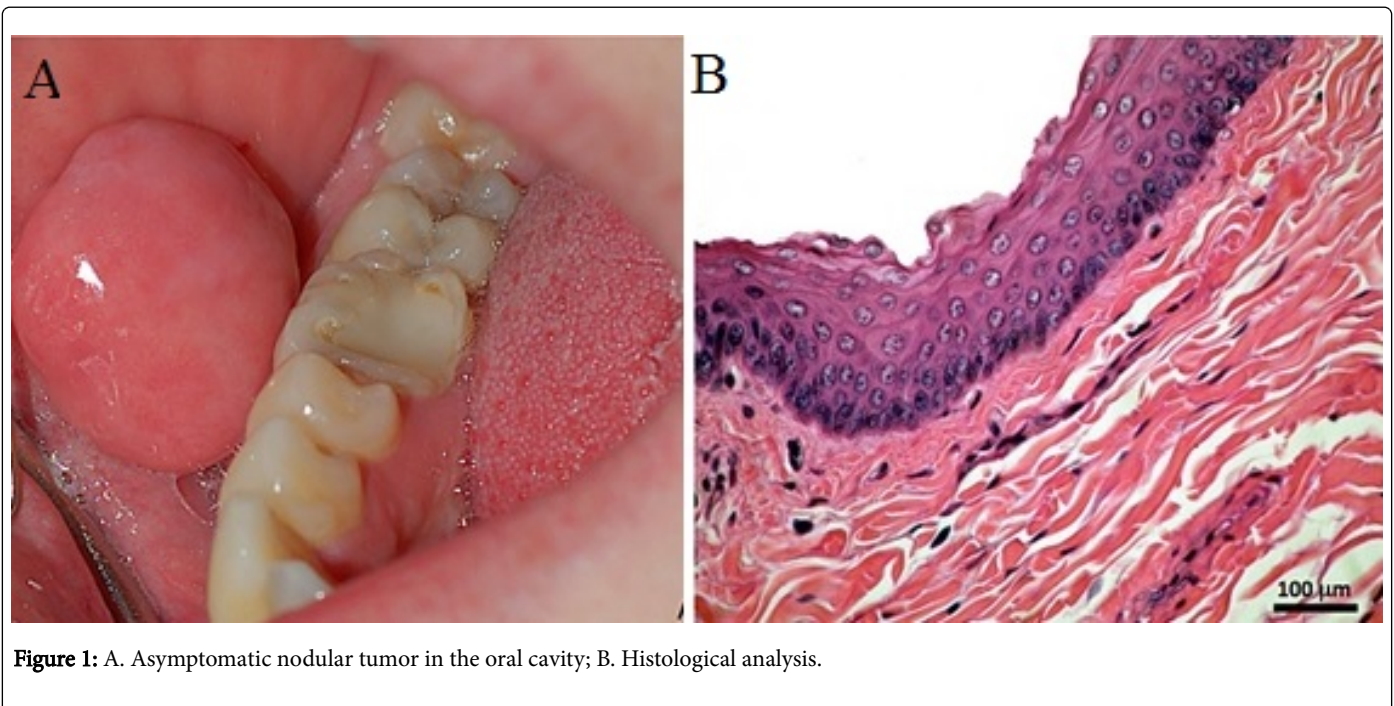
<sup>2</sup>Department of Health Sciences, University of Monterrey, Mexico

\*Corresponding author: Gerardo Rivera Silva, Department of Health Sciences, University of Monterrey, Av. I. Morones Prieto # 4500 Pte, San Pedro Garza Garcia, 66238, NL, Mexico, Tel: 52 81 8215-1446; E-mail: [gerardo.rivera@udem.edu](mailto:gerardo.rivera@udem.edu)

Rec date: Feb 11, 2016, Acc date: Feb 29, 2016, Pub date: Mar 02, 2016

Copyright: © 2016 Martinez Menchaca HR, et al. This is an open-access article distributed under the terms of the Creative Commons Attribution License, which permits unrestricted use, distribution, and reproduction in any medium, provided the original author and source are credited.

### Clinical Image



**Figure 1:** A. Asymptomatic nodular tumor in the oral cavity; B. Histological analysis.

A 16-year-old male presented with an asymptomatic nodular tumor in the oral cavity. Patient history revealed the spontaneous appearance of a mass, with exponential growth, 1 year prior to examination. Oral examination revealed a nodular tumor, soft and painless to palpation, similar in colour to the normal buccal mucosa. Mass location was alongside patient bite line (Figure 1A). Preoperative oral cancer

examination using a three distinct colour wavelength fluorescence and reflectance technology system resulted negative. Histological analysis showed a nodular mass of fibrous tissue covered by stratified squamous epithelium (Figure 1B). The clinical diagnosis resulted in a focal fibrous hyperplasia. Surgical removal of oral fibroma was performed using a Er; Cr: YSGG, 2780 nm laser.