

Follicular Mucinosis developing in a patient with Folliculitis Decalvans

Rolfe HM^{1*}, Myint M¹, Kim Y^{2,3} and Weedon D⁴

¹Department of Dermatology, Princess Alexandra Hospital, Woolloongabba, Australia

²Specialist Connect, Woolloongabba, Australia

³Queensland Institute of Dermatology, Greenslopes, Australia

⁴Sullivan and Nicolaides Pathology, Indooroopilly, Australia

Case Report

Folliculitis Decalvans (FD) is a form of inflammatory scarring alopecia; its causative mechanism is not well understood. It affects both sexes, may start in adolescence or adulthood and occurs more commonly in African Americans compared to Caucasians [1]. *Staphylococcus aureus* can be isolated from the pustules in most cases, but whether this is a primary or secondary process is unknown. It has been postulated that it is the interaction of *Staphylococcus Aureus* with the immune system that is significant. FD is mainly a neutrophilic inflammatory infiltrate in early lesions, with lymphocytes and plasma cells additionally in advanced lesions [2].

Follicular Mucinosis (called alopecia mucinosa by Pinkus [3]) involves accumulation of an abnormal amount of mucin. Mucin, called hyaluronic acid, occurs as part of the connective tissue in the dermis or mid-layer of the skin [4]. Follicular mucinosis is an uncommon inflammatory condition more frequent in adults in the third and fourth decades of life [5]. It is a tissue reaction in which there is a perifollicular and perivascular inflammatory cell infiltrate involving lymphocytes, histiocytes and a few eosinophils [5]. Histology shows mucin in the pilosebaceous unit [6]. Clinically Follicular Mucinosis (FM) appears as follicular papules and can have scarring alopecia but alopecia however is not always present [7]. The cause is not well understood but it is thought to be related to circulating immune complexes and cell-mediated immunity. It may progress to Mycosis fungoides and cutaneous T-cell lymphoma [8]. and there is usually a milder mucin infiltrate in FM associated with lymphomas [5].

A 44 year old man presented with scarring alopecia with erythematous papules and pustules on the right posterior occipital scalp. He was diagnosed with tinea capitis by another Dermatologist and was treated with oral Griseofulvin. He presented to us for a second opinion since his condition did not improve after two months of treatment with oral Griseofulvin. The neck lesion of Folliculitis Decalvans is shown in Figure 1.

The histopathologic findings from the punch biopsy showed ruptured folliculitis with heavy perifollicular chronic inflammation as shown in Figure 2. Foreign body giant cells were present surrounding the deepest portion of the ruptured follicle. Periodic acid-Schiff stain preparation showed no fungal elements and skin scrapings did not isolate fungi. A diagnosis of Folliculitis Decalvans was made.

He also had a thick, erythematous plaque with loss of hair over his right eyebrow, as shown in Figure 2. The eyebrow lesion was noted on presentation to us and it had developed within a few months of the FD developing on his neck.

A histology slide from the biopsy of his right eyebrow lesion is shown in Figure 3. Histology showed well developed follicular mucinosis with a moderately heavy inflammatory cell infiltrate. The interstitial infiltrate was heavy and composed of lymphocytes and eosinophils and a few neutrophils, well below the epidermis with no epidermotropism.

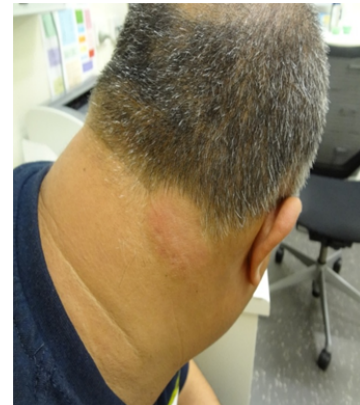

Figure 1: Folliculitis Decalvans over the right posterior neck.

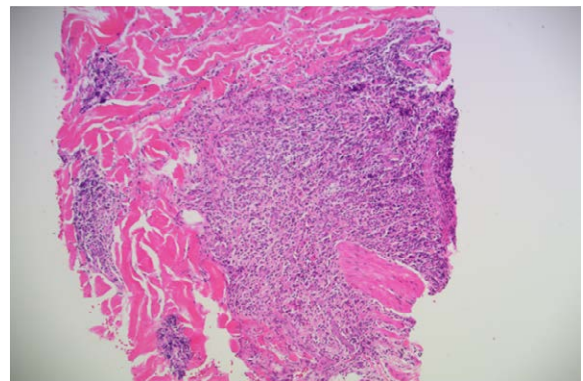


Figure 2: Histology slide showing Follicular Decalvans: heavy perifollicular chronic inflammation and ruptured folliculitis.

The patient was treated with 100 mg of doxycycline daily. His FD responded well but his FM did not respond after three months of treatment. Potent topical steroids were then tried on the FM lesion for two months but it enlarged despite the treatment. Weekly intralesional corticosteroid injections were then started and his FM is improving slowly after three treatments (Figure 4).

*Corresponding author: Heidi Rolfe, Department of Dermatology, Princess Alexandra Hospital, Woolloongabba, 9/35 Belgrave St, Balmoral, QLD, 4171, Australia, Tel: 0421472943; E-mail: heidimargaretrolfe@gmail.com

Received September 20, 2013; Accepted October 15, 2013; Published October 20, 2013

Citation: Rolfe HM, Myint M, Kim Y, Weedon D (2013) Follicular Mucinosis developing in a patient with Folliculitis Decalvans. Hair Ther Transplant 3: 112. doi:10.4172/2167-0951.1000112

Copyright: © 2013 Rolfe HM, et al. This is an open-access article distributed under the terms of the Creative Commons Attribution License, which permits unrestricted use, distribution, and reproduction in any medium, provided the original author and source are credited.

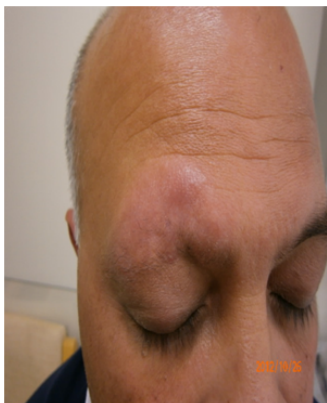

Figure 3: Follicular Mucinosis over the right eyebrow.

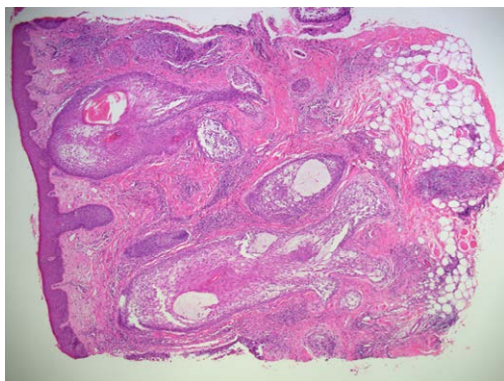


Figure 4: Histology slide showing Follicular Mucinosis; Periodic acid-Schiff stain shows well developed follicular mucinosis with a heavy inflammatory cell infiltrate.

There has been no reported case of Folliculitis Decalvans and Follicular Mucinosis developing in different locations in the same patient at similar times. Both these conditions have causative mechanisms that are not well understood and their similar timing of onset may indicate a related causative mediator.

References

1. Tan E, Martinka M, Ball N, Shapiro J (2004) Primary cicatricial alopecias: clinicopathology of 112 cases. *J Am Acad Dermatol* 50: 25-32.
2. Otberg N, Kang H, Alzolibani AA, Shapiro J (2008) Folliculitis decalvans. *Dermatol Ther* 21: 238-244.
3. Pinkus H (1983) Centennial Paper. Alopecia mucinosa. Inflammatory plaques with alopecia characterized by root-sheath mucinosis. By Hermann Pinkus, M.D., *Arch Dermatol* 1957. *Arch Dermatol* 119: 690-697.
4. Weedon D (2010) *Weedon's Skin Pathology*. (3rd edn), Churchill Livingstone, section 4.
5. <http://dermnetnz.org/immune/mucinoses.html>.
6. Kim R, Winkelmann RK (1962) Follicular mucinosis (alopecia mucinosa). *Arch Dermatol* 85: 490-498.
7. Snyder RA, Crain WR, McNutt NS (1984) Alopecia mucinosa. Report of a case with diffuse alopecia and normal-appearing scalp skin. *Arch Dermatol* 120: 496-498.
8. Cerroni L, Fink-Puches R, Bäck B, Kerl H (2002) Follicular mucinosis: a critical reappraisal of clinicopathologic features and association with mycosis fungoides and Sézary syndrome. *Arch Dermatol* 138: 182-189.