

Gastric Diverticulum: A Rare Endoscopic Finding

Hernández GH^{1*}, Soto ICF² and García CAJ³

¹Gastrointestinal Endoscopy Service, Medical Institute of Social Security of the State of Mexico and Municipalities (ISSEMyM), Toluca de Lerdo, Mexico

²Medical Endoscopy Department, Toluca Regional Hospital, ISSEMyM, Toluca de Lerdo, Mexico

³Toluca Regional Hospital, ISSEMyM, Toluca de Lerdo, Mexico

*Corresponding author: Guillermo Hernandez Hernandez, Medical resident Gastrointestinal Endoscopy Service, Medical Institute of Social Security of the State of Mexico and Municipalities (ISSEMyM), Toluca de Lerdo, Mexico, Tel: 01 52 7223687921; E-mail: winspang@hotmail.com

Received date: April 7, 2016; Accepted date: May 10, 2016; Published date: May 17, 2016

Copyright: © 2016 Hernandez GH, et al. This is an open-access article distributed under the terms of the Creative Commons Attribution License, which permits unrestricted use, distribution, and reproduction in any medium, provided the original author and source are credited.

Abstract

Gastric diverticulum is a rare disease, is a pouch protruding from the gastric wall. Usually gastric diverticulum is detected incidentally by gastrointestinal study, when the gastric diverticulum has symptoms surgical resection is recommended being open or laparoscopic resection with excellent results. There is no medical therapy for this disease; however the use of PPIs can improve some symptoms. A 40 year-old female presented a possible gastric diverticulum seen on CT scan. Her symptoms are epigastric pain and heart burn, she received proton-pump inhibitors with partial improvement, and an upper endoscopy was performed on January 2016 which showed the presence of a gastric diverticulum.

Keywords: Diverticulum, Stomach, Finding, Epigastric pain

Introduction

Gastric diverticulum is a rare condition with a prevalence of 0.02% in autopsies studies and 0.04% through imaging studies of the upper gastrointestinal tract, its distribution is the same for both men and women, gastric diverticulum are classified into congenital and acquired types, of which, congenital types are more common. Congenital gastric diverticulum, located in the retroperitoneal space, may be explained by embryogenesis. Acquired gastric diverticulum's are pseudo diverticula and are typically located in the gastric antrum. The most common age of presentation is between the fifth and sixth decades of life, however there are cases reported in children at 9 years-old [1]. There is no pathognomonic clinical data to suspect this disease, patients usually present with dyspepsia, gastro-esophageal reflux disease even upper gastrointestinal bleeding, it represents a challenge for the physician [2].

Case Report

A 40 year-old female was referred by her family doctor to the endoscopy unit in Regional Hospital of ISSEMyM (Social Security Institute of the State of Mexico and Municipalities) in Toluca, Estado de México because of lack of improvement of symptoms and of a possible gastric diverticulum seen on a CT scan. Her medical history includes occasional heart burn and epigastric pain for which she received proton-pump inhibitors (PPIs) with partial improvement. Apparently the symptoms did not resolve completely because the patient did not follow the low irritant diet, it means, a diet with low intake of chili, alcohol and some condiments. An upper endoscopy was performed on January 2016 which showed the presence of a diverticulum on the posterior wall of the gastric fundus. The diverticulum inlet measured approximately 4 cm. Some food remains were also found inside the diverticulum. The patient is currently on PPIs and irritating free diet which have apparently controlled her symptoms.

Pathophysiology

The most common site of gastric diverticulum is the posterior wall of gastric fundus, 2 cm below the gastro esophageal junction and 3 cm of the lesser curvature, usually measured 4 cm with a range of 3-11 cm [3]. There are congenital and acquired diverticula, the former being the most frequent and location on the posterior wall of gastric fundus, where it is embryological origin, it is believed is due to a defect in fusion with the dorsal mesentery and the ventral mesentery with the consequent formation of diverticulum, which are acquired location generally in antrum, they have one different etiopathogenesis which is associated with inflammatory processes such as surrounding peptic ulcer, malignant disease, pancreatitis, gastric outlet obstruction, it has been observed in patients who undergo to a bypass with Roux-Y gastric they can develop gastric diverticula (Figures 1 and 2) [1].

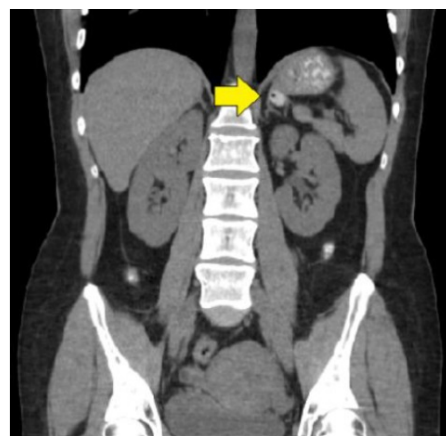


Figure 1: CT-scan-coronal section where saccular image is observed with contrast medium and air inside.

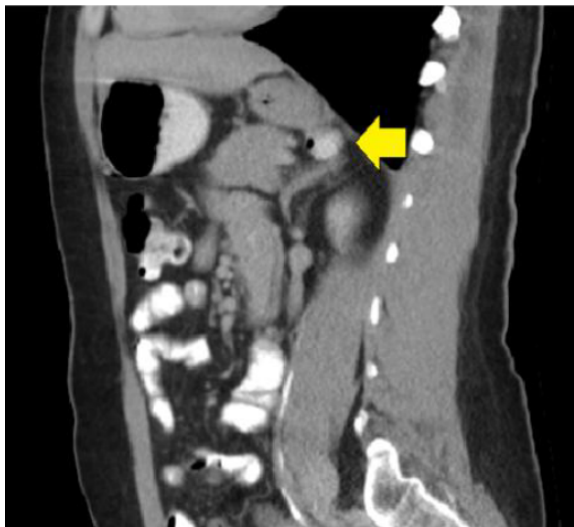

Figure 2: CT-scan-sagittal section observing diverticulum on the posterior wall of the stomach containing contrast medium and air.

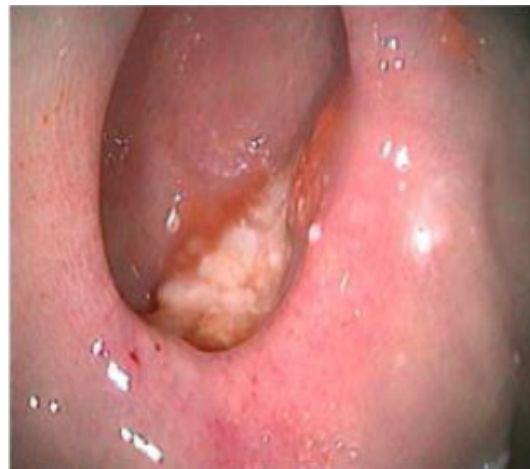

Figure 4: Endoscopic image of the diverticulum with remains of food inside.

Treatment

In the case of an asymptomatic gastric diverticulum there is no specific treatment, it is related to the degree of symptoms of the patient has and could be attributed to the diverticulum. PPI therapy for a few weeks can resolve symptoms in some cases, however in some patient's symptoms such as dyspepsia and epigastric pain will be refractory to inhibition of acid secretion [4]. Surgical treatment is recommended for long, symptomatic diverticula and complicated with perforation, bleeding or suspected of malignancy, laparoscopic and open resection has been successful [5]. Surgical treatment of gastric diverticulum through laparoscopy was described since 1998 with excellent results (Figures 3 and 4) [6,7].

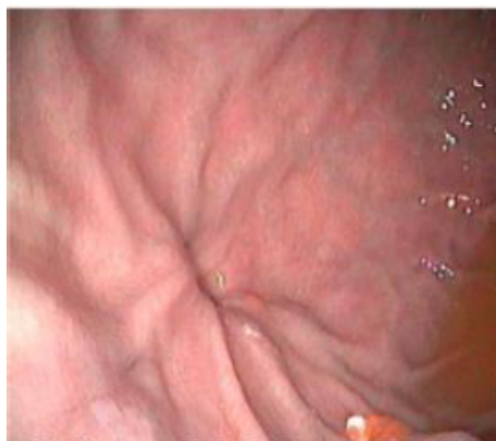

Figure 3: Endoscopic image of gastric fundus and mouth of the diverticulum.

Discussion

In this case report in which a patient otherwise healthy, is presented with clinical data from heartburn and epigastric pain, the primary care physician decides to perform a CT scan, perhaps no indication for such a study, however gratifying was the tomographic to administer oral contrast where it appeared a sacular image in the posterior wall of gastric fundus, the patient was referred to a secondary hospital care where all medical history is decided to perform an upper endoscopy, the finding was of a diverticulum in the posterior wall of the gastric fundus.

A through medical history can guide the physician about this disease, which definitely diagnosis will be always incidental to perform imaging studies, the importance of detecting it is for the potential adverse events that may occur in the short, medium and long time, such as bleeding, perforation and ultimately risk of malignancy, PPI therapy may be a reasonable option in a patient with high surgical risk, remembering that this entity occurs most often between the 5th and 6th decades of life, surgical treatment has proven to be a completely curative option with low morbidity and either laparoscopically or open surgery.

Conclusion

Gastric diverticulum represents a diagnostic challenge for the physician, must make a deliberate search of this entity in imaging studies, because it can be overlooked, proper diagnosis and treatment avoid major complications such as bleeding, perforation and malignancy. The disease has no specific symptoms and usually do suspect it is through imaging studies is observed. We have keep in mind this diagnosed possibility.

References

1. Rashid F, Aber A, Iftikhar SY (2012) A reviews on gastric diverticulum. World J Emer 7: 1.
2. Gockel I, Thomschke D, Lorenz D (2004) Gastrointestinal: Gastric diverticula. J Gastroenterol Hepatol 19: 227.

-
3. Rodeberg DA, Zaheer S, Moir CR (2002) Gastric diverticulum: a series of four pediatric patients. *J Pediatr Gastroenterol Nutr* 34: 564-567.
 4. MaCauley M, Bollard E (2010) Gastric Diverticulum: A rare cause of refractory epigastric pain. *Am J Med* 123: 5-6.
 5. Palmer ED (1973) Gastric Diverticulosis. *Am Fam Phys* 7: 114-117.
 6. Fine A (1998) Laparoscopic resection of a large proximal gastric diverticulum. *Gastrointest Endosc* 48: 93-95.
 7. Ye F, Zhe Z (2015) Gastric diverticulum simulating a left adrenal mass: A case report and review of the literature. *Oncology Letters* 10: 2477-2480.