

Glycyrrhizic Acid Mitigates 2nd Round Radiotherapy-Induced Severe Lung Injury: A Case Report

Zhang W¹, Hong J¹, Lin J¹, Okunieff P² and Zhang L^{1,2,*}

¹Fujian Platform for Medical Research at First Affiliated Hospital; Fujian key Lab of ; Individualized Active Immunotherapy; Key Lab of Radiation Biology of Fujian Province Universities, Fuzhou, China

²Department of Radiation Oncology, University of Florida, Gainesville, FL, USA

*Corresponding author: Lurong Zhang, Fujian Platform for Medical Research at First Affiliated Hospital; Fujian key Lab of ; Individualized Active Immunotherapy; Key Lab of Radiation Biology of Fujian Province Universities, Fuzhou, China, E-mail: lz8506@163.com or lurongzhang@ufl.edu

Rec date: June 19, 2017; Acc date: June 23, 2017; Pub date: July 07, 2017

Copyright: © 2017 Zhang W, et al. This is an open-access article distributed under the terms of the Creative Commons Attribution License, which permits unrestricted use, distribution, and reproduction in any medium, provided the original author and source are credited.

Abstract

Irradiation (IR) has become more important and effective therapeutic approach for cancer in chest (lung, breast and esophagus), however, IR-induced pneumonitis/fibrosis is still the bottle-neck for using higher IR dose to more effectively eradicate cancer cells, since there is no drug to treat the companion IR-injury toxicity. Glycyrrhizic Acid (GLA) has been used to treat hepatitis and liver fibrosis for almost 3 decades in Asia. It has no lethal dose in animal and no obvious side effect in human, which allows for 2 to 3 month use to imitate chronic fibrosis. Here we report for the first time that while GLA was used to treat the liver damage caused by chemotherapy, it presented a surprising mitigation effect on a 2nd round IR treatment-induced severe lung injury in a recurrent stage B (T2N3M0) lung cancer patient who had severe pneumonitis during the 1st round IR therapy. Combined with the fact that GLA effectively mitigates IR induced pneumonitis/fibrosis in animal model, we conclude that GLA is a potential good candidate to be developed as anti-IR lung injury drug.

Keywords: Glycyrrhizic acid; Mitigation; Lung Radiation toxicity; Cancer in chest

Introduction

IR-induced pneumonitis/fibrosis is a major dose-limiting factor during radiotherapy for lung cancer or other cancers in the chest. Prevention of lung radio toxicity will not only allow patients to tolerate higher IR doses for more effective treatment but also improve patients' quality of life following IR. Unfortunately, there is no approved drug that can be safely used over a long period in order to effectively mitigate IR-induced chronic lung injury without side effects. Great effects have being made to seek for drugs that prevent and/or mitigate IR-induced lung injury. Glycyrrhizic Acid (GLA), a traditional Chinese medicine, purified from licorice that was approved in Asia as an anti-hepatitis/liver fibrosis drug for almost 3 decades. When it was used on-label for a patient who had chemo drug-induced liver damage, it was found that the IR-induced lung toxicity was surprisingly relieved, suggesting that GLA might possess activity of anti-IR lung injury.

Case Report

A 55-year old man diagnosed with left lung central type differentiated squamous carcinoma associated with mediastinal and left supraclavicular lymph node metastasis at stage B (T2N3M0) according to AJCC 6th Edition Cancer Staging Manual criteria [1]. He was initially treated with 2 cycles of chemotherapy 40 mg of Navelbine on days 1 and 7; 40 mg of cisplatin on days 2-6 and then subjected to three-dimensional conformal radiation therapy (50 Gy/25 fractions, 2 Gy/day). Two weeks after IR, a Computed Tomography (CT) scan showed that the tumor size had decreased significantly with no obvious inflammation of the lung (Figure 1A). However, 3 months later, he suffered from IR-induced severe pneumonitis (CT evidence in Figure

1B) and had to be treated with dexamethasone (10 mg/day for 7 days) to relieve the symptoms of cough, fever, and shortness of breath; 5 months later, he still suffered from late IR toxicity (early fibrosis, Figure 1C). Nine months after the 1st round of radiotherapy, the cancer recurred (Figure 1D), and the patient requested a 2nd round of radiotherapy. Due to the patient's high level of alanine aminotransferase (ALT), GLA (150 mg/day) was used as an on-label drug for ALT-reduction/liver protection starting from beginning of second round of radiotherapy (45 Gy/18 fractions, 2.5 Gy/day) for 2 months. Surprisingly, the anticipated IR-induced pneumonitis/fibrosis was greatly suppressed by GLA, as observed by CT at 3-5 months after 2nd round of radiotherapy [Figure 1D- 1F].

Discussion

Although the underlying mechanism of IR-induced lung injury is unclear [2]. Ding et al. and Han et al. suspected that it might be related to immunoreaction to IR [3,4]. As with our case, IR-induced pneumonitis usually occurs after the treatment course (lasting 25-30 days at 2-2.5 Gy/day) is complete (1-1.5 months after the end of radiotherapy for 3 months), which is the time necessary for priming and sensitizing the immunoreaction. The severe area of IR-induced lung injury in the imaging is mostly within the irradiated areas, indicating that the antigens are induced directly by IR. It is well known that IR breaks DNA. The infidelity repair of damaged DNA could cause gene mutations, leading to the production of new proteins that are unseen by host immune cells and trigger a sterile local inflammation as IR pneumonitis. If pneumonitis is not controlled by immuno-suppressor drugs, such as dexamethasone (which cannot be used for a month, as is necessary for a long-lasting immunoreaction in the irradiated lung), then the sterile immune-inflammation could continue until the mutated cells are destroyed and replaced by fibrosis. This occurs far beyond the last IR dose, indicating that the IR damage

occurred months ago are recorded in mutated DNA (i.e., the “wrong DNA” generating the “wrong protein” recognized by immune cells that keep attacking the mutated cells). The memory immune cells can initiate stronger immune reaction if IR insult comes 2nd time.

Therefore, it is expected a stronger inflammation reaction upon the 2nd round radiotherapy if IR-induced pneumonitis/fibrosis occurs in the 1st round radiotherapy.

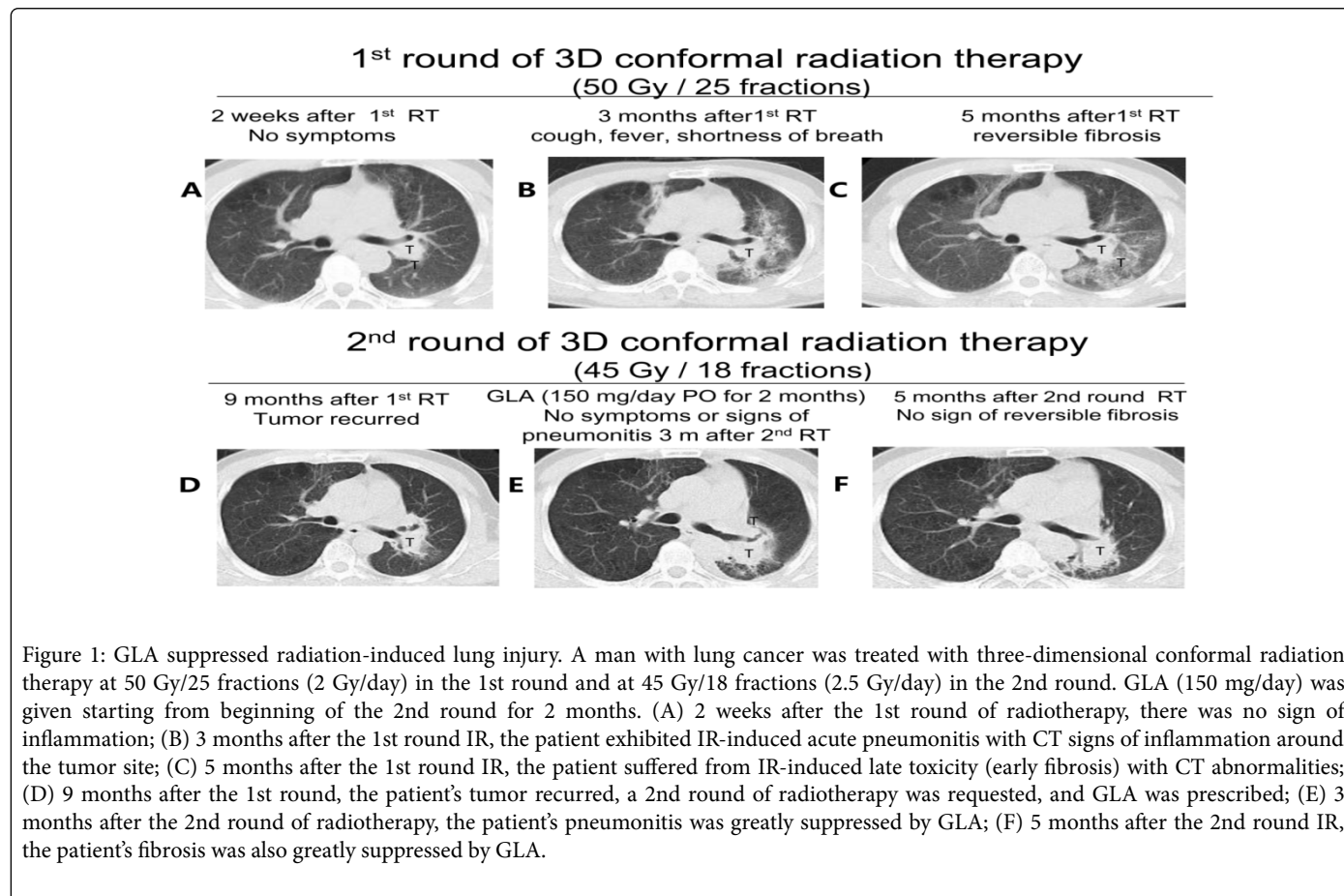


Figure 1: GLA suppressed radiation-induced lung injury. A man with lung cancer was treated with three-dimensional conformal radiation therapy at 50 Gy/25 fractions (2 Gy/day) in the 1st round and at 45 Gy/18 fractions (2.5 Gy/day) in the 2nd round. GLA (150 mg/day) was given starting from beginning of the 2nd round for 2 months. (A) 2 weeks after the 1st round of radiotherapy, there was no sign of inflammation; (B) 3 months after the 1st round IR, the patient exhibited IR-induced acute pneumonitis with CT signs of inflammation around the tumor site; (C) 5 months after the 1st round IR, the patient suffered from IR-induced late toxicity (early fibrosis) with CT abnormalities; (D) 9 months after the 1st round, the patient's tumor recurred, a 2nd round of radiotherapy was requested, and GLA was prescribed; (E) 3 months after the 2nd round of radiotherapy, the patient's pneumonitis was greatly suppressed by GLA; (F) 5 months after the 2nd round IR, the patient's fibrosis was also greatly suppressed by GLA.

The IR-induced long-lasting inflammation requires a drug that can be used for at least 2-3 months in order to control the sterile IR immunoreaction, which might last for years if the cascade of immune reaction is not blocked at the beginning. However, steroid hormone drugs (such as dexamethasone), despite being good immunosuppressors, are not suitable for long-term treatment due to their severe side effects. GLA, an effective component of licorice-based herbal medicine, has been used in Asia as an anti-liver fibrosis drug for almost 3 decades. It is a very safe drug with a large therapeutic window (no lethal dose has been determined in animals or humans) and can be used continuously for 2-3 month anti-inflammation without obvious side effects.

Since DNA mutations start from the beginning of radiotherapy and the immunoreaction occurs after the “wrong protein” is produced, GLA should begin immediately following the first IR treatment. Our studies in animal models (unpublished data) suggest that starting GLA within 1-7 days could effectively prevent IR-induced lung acute and later toxicities. In this case, the patient was given GLA starting on day 1 of the 2nd round of radiotherapy for 2 months. He experienced good relieve of IR side effects, which is expected to be worse than that after his 1st round radiotherapy.

Lung cancer has the highest incidence worldwide. Approximately 2/3 of lung cancer patients receive radiotherapy; 10-30% of these

patients may suffer from severe IR-induced lung injury, which not only requires additional medical treatment but also substantially reduces quality of life. In addition to lung cancer, radiotherapy is also used to treat breast cancer, esophageal cancer, mediastina lymphoma, and other tumors in the chest, oftentimes leading to IR-induced lung injury [5]. While no currently approved drugs effectively prevent/mitigate IR-induced fibrosis, GLA could potentially fill that gap. It is a good candidate for drug development and necessitates further clinical investigation.

Conflict of Interest Statement

Weijian Zhang and Lurong Zhang are the inventors of patents (US12/862,980 and ZL200910111974.6) for this agent. Other authors have no conflict of interest to declare.

Acknowledgement

We thank Kate Casey-Sawicki and Shimin Zhang for editing this manuscript for publication.

References

1. <https://cancerstaging.org/references-tools/deskreferences/Documents/AJCC6thEdCancerStagingManualPart1.pdf>

-
2. Giridhar P, Mallick S, Rath GK, Julka PK (2015) Radiation induced lung injury: prediction, assessment and management. *Asian Pac J Cancer Prev* 16: 2613-2617.
 3. Ding NH, Li JJ, Sun LQ (2013) Molecular mechanisms and treatment of radiation-induced lung fibrosis. *Curr Drug Targets* 14: 1347-1356.
 4. Han G, Zhang H, Xie CH, Zhou YF (2011) Th2-like immune response in radiation-induced lung fibrosis. *Oncol Rep* 26: 383-388.
 5. Chargari C, Riet F, Mazevet M, Morel E, Lepechoux C, et al. (2013) Complications of thoracic radiotherapy. *Presse Med* 42: e342-e351.