

Case Report

Open Access

Headache in a Patient with an Extracranial Lipoma: Report of a New Case

Escuti N*

Department of Neurology, University of Miami School of Medicine, Miami, Florida, P.O. Box: 33136, USA

Abstract

Lipomas are very common benign tumors; however, only four cases of headaches caused by extracranial lipomas have been reported. Moreover, the headache phenotypes and clinical course have been poorly described. Herein, we describe a case of 50 year-old-man who developed new onset predominately right-sided frontotemporal cluster-like headache since age 48. In 2005, he had generalized headaches that improved after a resection of an occipital lipoma. Imaging showed regrowth of the lipoma at the C1-C2 spinal level. Treatment with Excedrin tabs and sumatriptan injections helped within 20 minutes. His symptoms were worse in the summer and spring. He spontaneously improved after a few months. We review cases of lipoma-induced headaches in the literature, several of which resemble a trigeminal autonomic cephalalgias and are associated with compression of trigeminal or cervical peripheral nociceptors. This case offers the opportunity to discuss the possible pathophysiological mechanisms underlying cluster-like headaches symptoms and the relation with pain referral from cervical structures to the head.

Keywords: Primary headache; Cluster headache; Extracranial lipoma; Trigemino-cervical complex

Introduction

In the literature, symptomatic cluster-like or trigeminal autonomic cephalalgias (TAC) like headaches are reported more commonly due to intracranial abnormalities than extracranial ones [1-5]. Headaches caused by extracranial lipomas are rare in the adult population with the exception of four cases that have been reported [6-8] including a case of symptomatic cluster-like headache triggered by forehead lipoma. With exception of two cases, the clinical features of the headache pain were not described in detail however there is an implication that compressive lesions can be the mechanism triggering the pain.

Here in, we describe a case of a patient with right sided frontotemporal cluster-like headache symptoms related to suboccipital lipoma. Interestingly, prior to his initial visit, the patient experienced more generalized headaches which improved after the surgical resection of a lipoma located in the occipital region. Therefore, this is one of few headache cases secondary to extracranial lipoma described allowing the opportunity to discuss its implications on IHS classification and the possible pathophysiological underlying mechanisms causing the headache.

Case Report

A 50 year-old man with history of sleep apnea and sinus congestion presented to the Headache Clinic on August 2014 for evaluation of headaches that started at age 48 and progressively became a burden. In 2005 he had occipital lipoma-related headaches which improved upon resection but they did not completely subside. At that time headaches were more generalized and were not associated with photophobia, phonophobia, nausea, vomiting or cranial autonomic symptoms. Since age 48 he has experienced severe episodes of right-sided frontotemporal headaches. The initial headache frequency was 2 attacks/ month for approximately six months, but it worsened up to 10 attacks/ month for approximately four months. The mean duration of the pain was 30 minutes. Pain was right-sided frontotemporal and usually dull, becoming throbbing when severity increased. Attacks occurred 1-2/ day and often awakened the patient at night. The attacks were associated with phonophobia and osmophobia but he did not experience any auras. At times, he experienced bilateral conjunctival injections, lacrimation, with right-sided nasal congestion and attacks were more severe in the spring and early summer. He became restless and agitated during the

attacks. He was not able to identify any triggers other than smoking and possible compression of the back of the head/neck extension, which he noticed when he was at the barber. Acetaminophen-aspirin-caffeine combination tablets sometimes helped him somewhat within 15-20 minutes. For prevention we explained he may benefit from a trial of Indomethacin or Verapamil but he preferred to be off medications. He did agree to take Melatonin 3 MG tablet to reduce attacks at night but he stopped taking it shortly after prescribed as it was causing him to be restless.

For acute attacks we suggested a trial of Sumatriptan injection (6 MG/0.5 mL up to 3 times/ week) and Oxygen. Patient was explained the risks of Sumatriptan and he agreed to take it upon clearance from his cardiologist. His other medications included lidocaine-hydrocortisone ace, alprazolam and diphenhydramine; diphenhydramine was discontinued. On physical exam a palpable subcutaneous mass in the left suboccipital/upper cervical region was revealed consistent with CT of the neck findings on May 2014 (Figures 1 and 2). On exam the palpable subcutaneous mass did not show any pulsation or tenderness and the overlying skin appeared normal, i.e., without signs of discoloration or abnormal vascularization. Patient had family history of migraine headaches in his mother. Patient never tried oxygen but abortive treatment with Excedrin and Sumatriptan injections helped within 20 minutes. Headaches persisted; however, they decreased to a frequency of 1/month. He associated the improvement to a 35 pound weight loss. Five month after his initial visit headaches persisted however they decreased to a frequency of 1/month which patient attributes to a thirty five pounds weight loss. Patient will consider lipoma resection if headaches worsen again.

Discussion and Literature Review

Symptomatic cluster-like headaches or trigeminal autonomic

*Corresponding author: Natalia Escuti, Department of Neurology, University of Miami School of Medicine, Miami, Florida, P.O. Box: 33136, USA, Tel: 8184812248; E-mail: nataliaescuti@hotmail.com

Received August 17, 2015; Accepted August 27, 2015; Published August 31, 2015

Citation: Escuti N (2015) Headache in a Patient with an Extracranial Lipoma: Report of a New Case. J Neurol Disord 3: 250. doi:10.4172/2329-6895.1000250

Copyright: © 2015 Escuti N. This is an open-access article distributed under the terms of the Creative Commons Attribution License, which permits unrestricted use, distribution, and reproduction in any medium, provided the original author and source are credited.

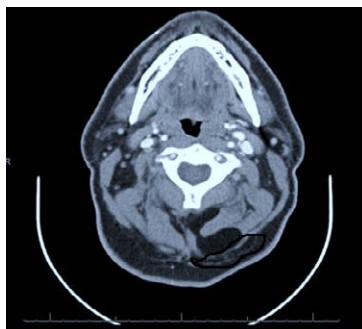


Figure 1: CT neck with contrast shows bilobular fat-containing lesion within the left paravertebral space measuring approximately 3.7 × 3.3 cm (arrow). The lesion is located at the level of C1-C2 in the suboccipital region.

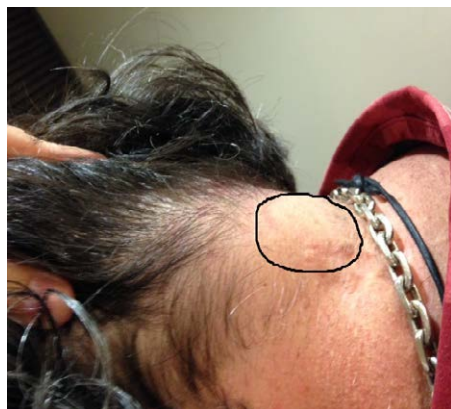

Figure 2: Subcutaneous mass in left occipital and upper cervical regions.

cephalalgias (TAC) like headaches are reported more commonly due to intracranial abnormalities such as vascular malformations, benign and malignant tumors followed by MS, head trauma and infectious diseases [1-5] than extracranial lesions (cervical meningioma, nasopharyngeal carcinoma, syringomyelia, etc). Moreover, the extracranial abnormalities described as responsible for cluster headaches (CH) and cluster-like headaches are not limited in their location and nature, and may stem from vascular and neoplastic lesions to infectious and traumatic ones in various regions of the head and the neck [6].

Only four cases of extracranial lipoma producing headaches have been reported including a case of symptomatic cluster-like headaches triggered by forehead lipoma [9]. In one case a 34 year old man had two episodes of thunderclap headache irradiating to the neck and lasting several hours. A radiological work up to detect intracranial aneurism was negative. Two months later he started to complain of a continuous, dull headache in the left frontal and temporal regions. MRI revealed a subcutaneous angiolipoma in the left temporal region. After one year of continuous left hemicrania, indomethacin was prescribed and headaches disappeared within two weeks [6]. In the other two cases a subcutaneous lipoma of the scalp in the left parietal region in a 41 year old female and a subcutaneous lipoma of the scalp in the left temporal region in a 61 year old male, was responsible for non-specific headaches and its removal caused disappearance of pain in both [7-8]. Similarly a fourth case of a forehead lipoma in the right fronto-temporal region in a 42 year old male was causing right-sided paroxysmal headaches mimicking cluster-like headaches, which improved after surgical excision. It was conceivable that mechanical irritation from lipoma on

the nerve terminals of the ophthalmic division of the trigeminal nerve in the forehead activated the trigeminal-autonomic reflex responsible for the autonomic features [9].

The last three cases in particular had some similarities with our case report in the relation between headache pain and lipoma location and the headache reduction or disappearance with lipoma excision. This implies that the headache was probably secondary to the lesion. However there is no detailed description of the clinical features of the headache pain and only in Tach's case the author suggested that compressive lesions can be the cause of the headache pain.

The exact pathophysiology in cases of symptomatic cluster-like headaches is unknown. A structural lesion may cause autonomic imbalance leading to an attack-wise presentation of the symptoms [10]. Differences in individual threshold for triggering the parasympathetic trigeminal reflexes may also play a role [11]. The pain mechanism in secondary CH seems attributable to irritation of pain-sensitive-structures and activation of trigeminal nerve endings [12].

The trigeminocervical nucleus is a region of the upper cervical spinal cord where sensory nerve fibers from the trigeminal ganglion (in the descending tract of the trigeminal nerve) are believed to interact with sensory nerve fibers from the upper cervical root ganglion at the trigeminal nucleus caudalis (responsible for transmission of pain and temperature from the head). Nerve fibers involved in the localization of pain ascend from the trigeminal nucleus to the thalamus and then to the sensory cortex. This convergence of upper cervical and trigeminal sensory pathways allows a bidirectional "referred pain" between the neck and trigeminal sensory receptive fields of the face and head [13]. Pain-producing intracranial structures, such as the dura matter and large intracranial vessels, also project into trigeminal nucleus caudalis and dorsal horns of C1 and C2 forming a unit the TCC [14-16]. This also explains why symptomatic cluster-like headaches are more commonly associated intracranial lesions rather than extracranial ones [1-5].

A study showed that stimulation of the greater occipital nerve, a branch of C2 root, produces excitation of second-order neurons in the trigeminocervical complex. Given that neck pain is common in primary headache disorders this convergent excitation may play a role in pain referral from cervical structures, such as the occipital muscles, to the head [17]. The study showed that there is an extensive convergence of afferents from the face, teeth, neck and oral mucosa onto neurons of the trigeminal nucleus caudalis [18].

Headache syndromes often involve occipital and neck symptoms, suggesting a functional connectivity between nociceptive trigeminal and cervical afferents [19]. The most likely mechanism for this observation is 'referred pain' originating from structures of the neck and projecting to facial areas and viceversa at the level of second-order neurons from the brainstem, which receive convergent input from both trigeminal and cervical territories [20]. Based on experimental study findings electrical stimulation of the greater occipital nerve (GON) in animals has shown to have an effect on dural nociceptive stimulation [21-23] suggesting sensitization on second-order neurons receiving cervical and trigeminal input. Certainly GON activation leads to frontal head pain in humans [24] and GON injection has been used therapeutically in a range of primary headaches [25].

In addition, the tendency to develop a lipoma is not necessarily hereditary, although hereditary conditions such as familial multiple lipomatosis, may include lipoma development [26,27]. Cases have been reported where minor injuries are alleged to have triggered the growth of a lipoma, called "post-traumatic lipomas" [28]. However, the link

between trauma and the development of lipomas is controversial [29]. Lipomas are rarely life-threatening and the common subcutaneous lipomas are not a serious condition. Lipomas are usually relatively small with diameters of about 1–3 cm but they can grow over the years into bigger ones. Deep lipomas have a greater tendency to recur than superficial lipomas, because complete surgical removal of deep lipomas is not always possible [30,31]. This could explain a possible recurrence of the lipoma in our patient and therefore the recurrence of the new onset of headaches. It has also been speculated that lipomas may enlarge with obesity or altered endocrine status [32]. Although lipomas do not regress even with starvation [33,34] weight loss could help assume that in our patient's case lipoma did not continue to grow and in turn symptoms improved.

Conclusion

Our case report and additional cases in the literature suggest that compressive extracranial lipomas of upper cervical or trigeminal nerve regions can produce cluster-like headaches, hemicrania continua or other headache types. Possible mechanisms include sensitization of extracranial cervical nociceptors and convergence of afferent signals to the trigeminocervical complex. Our patient's headaches most resemble CH by clinical description in their seasonal variation with cranial autonomic activation. Although we did not find a clear circannual pattern patient did experience worsening of his pain during the spring and early summer. He also experienced agitation and right nasal congestion during the attacks. In addition the patient is best characterized as a probable external-compression headache (4.6.3) according to the ICHD-3-beta [35].

This case and review preliminarily supports extracranial compressive lesions caused by abnormalities within the scalp as a type of secondary headache. We suggest that external compression headaches may be more insidious when there is compression by abnormal growth of pericranial soft tissues at C1-C2 level. These findings support the role of cervical imaging in atypical cases of TAC-like headaches.

References

- Mani S, Deeter J (1982) Arteriovenous malformation of the brain presenting as a cluster headache- a case report. *Headache* 22: 184-185.
- Milos P, Havelius U, Hindfelt B (1996) Clusterlike headache in a patient with a pituitary adenoma. With a review of the literature. *Headache* 36: 184-188.
- Davey R, Al-Din A (2004) Secondary trigeminal autonomic cephalgia associated with multiple sclerosis. *Cephalalgia* 24: 605-607.
- Formisano R, Angelini A, De Vuono G, Calisse P, Fiocco F, et al. (1990) Cluster-like headache and head injury: case report. *Ital J Neurol Sci* 11: 303-305.
- Heidegger S, Mattfeldt T, Rieber A, Wikstroem M, Kern P, et al. (1997) Orbito-sphenoidal Aspergillus infection mimicking cluster headache: a case report. *Cephalalgia* 17: 676-679.
- D'Alessio C, Ambrosini A, Colonnese C, Pompeo F, Vandenheede M, et al. (2004) Indomethacin-responsive hemicrania associated with an extracranial vascular malformation: report of two cases. *Cephalalgia* 24: 997-1000.
- Tach JR (1981) Lipoma-induced headache. *Headache* 21: 186.
- Ban M, Kitajima Y (2002) Intramuscular lipoma within the temporal muscle. *Int J Dermatol* 41: 689-690.
- Cologno D, Buzzi MG, Cicinelli P, Caltagirone C, Spalletta G (2008) Symptomatic cluster-like headache triggered by forehead lipoma: a case report and review of the literature. *Neurol Sci* 29: 331-335.
- Wilbrink LA, Ferrari MD, Kruit MC, Haan J (2009) Neuroimaging in trigeminal autonomic cephalgias: when, how, and of what? *Curr Opin Neurol* 22: 247-253.
- Straube A, Freilinger T, R  ther T, Padovan C (2007) Two cases of symptomatic cluster-like headache suggest the importance of sympathetic/parasympathetic balance. *Cephalalgia* 27: 1069-1073.
- Leone M, Bussone G (2009) Pathophysiology of trigeminal autonomic cephalalgias. *Lancet Neurol* 8: 755-764.
- Bogduk N (1992) The anatomical basis for cervicogenic headache. *J Manipulative Physiol Ther* 15: 67-70.
- Goadsby PJ, Hoskin KL (1997) The distribution of trigeminovascular afferents in the nonhuman primate brain *Macaca nemestrina*: a c-fos immunocytochemical study. *J Anat* 190: 367-375.
- Hoskin KL, Zagami AS, Goadsby PJ (1999) Stimulation of the middle meningeal artery leads to Fos expression in the trigeminocervical nucleus: a comparative study of monkey and cat. *J Anat* 194: 579-588.
- Kaube H, Keay KA, Hoskin KL, Bandler R, Goadsby PJ (1993) Expression of c-Fos-like immunoreactivity in the caudal medulla and upper cervical spinal cord following stimulation of the superior sagittal sinus in the cat. *Brain Res* 629: 95-102.
- Le Doare K, Akerman S, Holland PR, Lasalandra MP, Bergerot A, et al. (2006) Occipital afferent activation of second order neurons in the trigeminocervical complex in rat. *Neuroscience letters* 403: 73-77.
- Sessle BJ, Hu JW, Amano N, Zhong G (1986) Convergence of cutaneous, tooth pulp, visceral, neck and muscle afferents onto nociceptive and non-nociceptive neurones in trigeminal subnucleus caudalis (medullary dorsal horn) and its implications for referred pain. *Pain* 27: 219-235.
- Busch V, Jakob W, Juergens T, Schulte-Mattler W, Kaube H, et al. (2007) Occipital nerve blockade in chronic cluster headache patients and functional connectivity between trigeminal and occipital nerves. *Cephalalgia* 27: 1206-1214.
- Hoskin KL, Zagami AS, Goadsby PJ (1999) Stimulation of the middle meningeal artery leads to Fos expression in the trigeminocervical nucleus: a comparative study of monkey and cat. *J Anat* 194: 579-588.
- Hu JW, Sessle BJ, Raboisson P, Dallel R, Woda A (1992) Stimulation of craniofacial muscle afferents induces prolonged facilitatory effects in trigeminal nociceptive brain-stem neurones. *Pain* 48: 53-60.
- Hu JW, Vernon H, Tatourian I (1995) Changes in neck electromyography associated with meningeal noxious stimulation. *J Manipulative Physiol Ther* 18: 577-581.
- Bartsch T, Goadsby PJ (2003) Increased responses in trigeminocervical nociceptive neurons to cervical input after stimulation of the dura mater. *Brain* 126: 1801-1813.
- Piovesan EJ, Kowacs PA, Tatsui CE, Lange MC, Ribas LC, et al. (2001) Referred pain after painful stimulation of the greater occipital nerve in humans: evidence of convergence of cervical afferences on trigeminal nuclei. *Cephalalgia* 21: 107-109.
- Anthony M (1992) Headache and the greater occipital nerve. *Clin Neurol Neurosurg* 94: 297-301.
- Leffell DJ, Braverman IM (1986) Familial multiple lipomatosis. Report of a case and a review of the literature. *J Am Acad Dermatol* 15: 275-279.
- Toy BR (2003) Familial multiple lipomatosis. *Dermatol Online J* 9: 9.
- Signorini M, Campiglio GL (1998) Posttraumatic lipomas: where do they really come from? *Plast Reconstr Surg* 101: 699-705.
- Sheridan F, Scharf D, Henderson VW, Miller CA (1990) Lipomas of the mesencephalic tectum and rostral pons associated with sleep apnea syndrome. *Clin Neuropathol* 9: 152-156.
- <http://pathologyoutlines.com/>
- Aust MC, Spies M, Kall S, Jokuszies A, Gohritz A, et al. (2007) Posttraumatic lipoma: fact or fiction? *Skinmed* 6: 266-270.
- Wilbrink LA, Ferrari MD, Kruit MC, Haan J (2009) Neuroimaging in trigeminal autonomic cephalgias: when, how, and of what? *Curr Opin Neurol* 22: 247-253.
- Straube A, Freilinger T, R  ther T, Padovan C (2007) Two cases of symptomatic cluster-like headache suggest the importance of sympathetic/parasympathetic balance. *Cephalalgia* 27: 1069-1073.
- Fletcher CDM, Unni KK, Mertens F (2002) Pathology and Genetics of Tumours of Soft Tissue and Bone. World Health Organization Classification of Tumours, Lyon: IARC Press.
- Headache Classification Committee of the International Headache Society (2013) The International Classification of Headache Disorders. *Cephalalgia* 33: 629-808.