

Homicidal Attempt by Injection of an Organophosphate Insecticide in a Seven Month-Old Baby

Laila M El- Zalabany and Ahmed R Ragab*

Department of Forensic Medicine and Clinical Toxicology, Mansoura University, Egypt

Abstract

The present case reports the first ever case of homicidal poisoning due to injection of an organophosphate insecticide with successful resuscitation and reporting.

Case: A 7-month-old baby presented to the emergency department with a history of insect bite since 5 hours by his relatives with a main complaint of irritability, disturbed conscious level, irregular respiration and wheezy chest. The injection site has appeared as oval area of redness and swelling at right elbow region that were noticed by the pediatric emergency department physician, with a medical history of resistance to medications for suspected insect bite (antihistaminic and corticosteroids in pediatric dosage) from referral hospital. By toxicological consultation, we revealed disturbed conscious level (GCS 10), pinpoint pupils and increase all body secretions, salivation, bronchorrhea and incontinence in urine and stools. The clinical toxicology consultant suspected a case of acute anticholine esterase toxicity and recommended a plasma pseudocholinesterase level that appeared to be very low, consistent with acute intoxication with organophosphate insecticide. The management of organophosphate poisoning was started, as airway management, administration of oxygen and fluids, as well as atropine in increasing doses and pralidoxime. Our case report emphasizes the necessity of a detailed history taken and careful smart medical examination for the possibility of homicide in such cases. Although injection sites may be the expected results of insect bite, medical treatment, dermal lesions also may be associated with injections of toxic substances.

Keywords: Homicidal injection; Plasma pseudocholinesterase; Insecticides; Intoxication; Organophosphorus compound; Child

Introduction

Organophosphate (OP) poisoning is common in developing countries, especially in Egypt. Organophosphate insecticides are widely used in rural areas. Intentional exposure of organophosphates is associated with a high mortality rate [1].

OP poisoning by parenteral route has been described by very few authors [2-4]. If the history of parenteral administration of the compound is not available, diagnosis becomes difficult.

Organophosphate Intoxication (OI) induces irreversible inhibition of acetylcholinesterase. Organophosphates phosphorylate the serine hydroxyl group of acetylcholine, leading to accumulation of acetylcholine at the cholinergic synapses [5]. This accumulation leads to weakness and fasciculation of the muscle. In the central nervous system, neural transmission is disrupted. If this blockade is not reversed within 24 h, large amounts of acetylcholinesterase are permanently destroyed [6].

Acetylcholinesterase is found in red blood cells as well as in nicotinic and muscarinic receptors. To determine the severity and/or the elimination time of OI, one should measure cholinesterase in blood, either by measuring plasma pseudocholinesterase (PCE) or by measuring the cholinesterase in erythrocytes (which is thought to reflect the cholinesterase in neurons and neuromuscular junctions). The first method is widely available and therefore commonly used [6,7].

Herein, we report a case of a 7 month male baby who, upon being injected "homicidal attempt" with an organophosphate insecticides solution, developed severe OI associated with Central Nervous System (CNS) depression.

Case Report

A 7-month-old previously healthy boy was brought to the emergency department with redness and swelling in the right antecubital fossa. He had been in good health until he was found, 5 hours prior to admission, crying in his bed with a suspected history of

insect bite in his right elbow region. The mother was not able to provide more information.

At admission, the pediatrician received a medical report from the referral health care personnel that the child had a history of unknown insect bite with a resistance to anti-allergic medications (antihistaminic and corticosteroids). The pediatrician consulted the clinical toxicologist for further opinion.

The physical examination of the baby by the clinical toxicologist showed, pinpoint pupils (less than 1 mm in diameter), sialorrhea, disturbed conscious level (his Glasgow Coma Scale (GCS) score was 10). Upon presentation, his vital signs included a rectal temperature of 36.1°C; heart rate, 132 beats/min; respiratory rate, 46 breaths/min; blood pressure, 85/45 mmHg; and haemoglobin saturation, 94%. Lung auscultation revealed bilateral basal non-consonating crepitations and ronchi. He had no abdominal tenderness, distension or hepatosplenomegaly. The skin was warm and clammy with Capillary Refill (CR) of less than two seconds. By local examination to the suspected area, there was found a widespread redness and swelling at the injection site of the right antecubital region of the studied case with a very tiny injection mark in the center of the inflammatory region (Figure 2). After oxygen tent and atropine administration (0.02 mg/kg every 5 min), the patient's condition stabilized. Earlier atropine (0.02 mg/kg) was given to prevent further decline.

***Corresponding author:** Ahmed R Ragab, Department of Forensic Medicine and Clinical Toxicology, Faculty of Medicine, Mansoura University, Egypt, E-mail: ahmedrefat1973@yahoo.com

Received November 24, 2012; **Accepted** December 18, 2012; **Published** December 20, 2012

Citation: El- Zalabany LM, Ragab AR (2012) Homicidal Attempt by Injection of an Organophosphate Insecticide in a Seven Month-Old Baby. J Clin Case Rep 2:232. doi:[10.4172/2165-7920.1000232](https://doi.org/10.4172/2165-7920.1000232)

Copyright: © 2012 El- Zalabany LM, et al. This is an open-access article distributed under the terms of the Creative Commons Attribution License, which permits unrestricted use, distribution, and reproduction in any medium, provided the original author and source are credited.

The cause of the symptoms was unclear, but intoxication with an Organophosphorus Compound (OC) was considered [8]. The patient's symptoms and signs, the recovery after atropine administration indicated probable organophosphate intoxication.

The baby was transferred to The Pediatric Intensive Care Unit (PICU). All laboratory values were normal, except for a decreased Pseudocholesterase Enzyme (PCE). The baby's PCE was 412 IU/L (laboratory reference range: 1900-3800 IU/L). These clinical and laboratory findings confirmed our diagnosis of organophosphate intoxication. We registered this case in medico legal registry and notification was sent to the police [9].

Admission laboratory values were haemoglobin 13.5 g/dL (12.5-14.5), haematocrit 37% (35-50), white blood cell count 3.5 K/uL (4.5-11), platelet count 390 K/uL (150-400), glucose 150 mg/dL (76-110), urea 26 mg/dL (17-50), creatinine 0.72 mg/dL (<1.2), calcium 10.1 mg/dL (8.5-10.7), serum glutamic-oxaloacetic transaminase (sGOT) 31 U/L (<40), serum glutamic pyruvic transaminase (sGPT) 31 U/L (<40), gamma-glutamyl transferase (GGT) 21 U/L (<50) and lactate dehydrogenase (LDH) 411 U/L (<490).

The baby was kept on oxygen tent for the next 24 h. He was treated with plenty fluid infusions, atropine (0.02 mg/kg every 15 min) and obidoxime (7 mg/kg every 12 h). The frequency of atropine administration was reduced and finally stopped when symptoms as hypersecretion and bronchospams disappeared. Baby improved considerably. After atropine treatment had been stopped, obidoxime was slowly decreased and stopped after 3 days. His PCE level was 1150 IU/L on the 6th day (Figure 1).

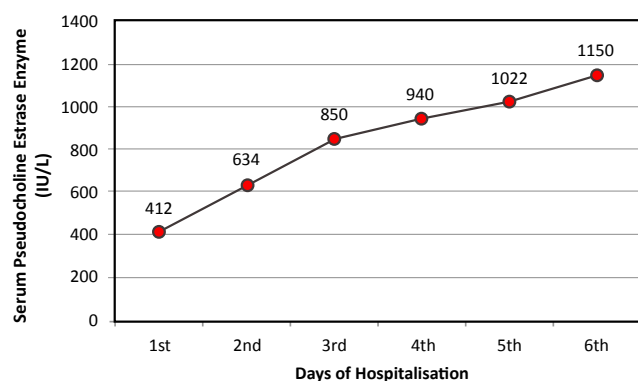


Figure 1: Serum Pseudocholesterase Enzyme level in the studied case during hospitalization period.

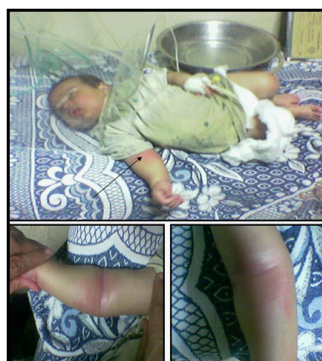

Figure 2: Widespread redness and swelling at the injection site of the right antecubital region regarding the studied case.

The baby was discharged from the PICU on the 4th day and from the hospital on 6th day without any sequelae. Further evaluation of the baby 2 weeks later showed normal clinical findings and the PCE values were within the normal range.

Dementon was detected in blood and urine samples. No toxic agent was found in baby formula and medicines obtained from the crime scene. Dementon was also detected; insect sprayer bottle at bathroom of the baby's home and syringe remainings in the kitchen basketball were found. Gas Chromatography Mass Spectrophotometry (GCMS) was the method used for toxicological analysis. Based on the history, clinical findings and toxicological analysis, the cause of reported case was documented as dementon intoxication due to injection of insecticide to the right arm. The member of parquet decided that the case is a homicide attempt but could not convict any patient relatives as murderer because of lack of evidence. The file is still open.

Discussion

Egypt is a predominantly agrarian country with large rural population. Organophosphate pesticides are used commonly for suicidal purpose. Although ingestion with suicidal intent is a common mode, occupational exposure while spraying in fields is an important modality of poisoning. Finally, a homicidal attempt via organophosphate poisoning is a rare situation and only one reported case all over the world by parenteral homicidal injection [10]. The clinical presentations and outcome of organophosphate poisoning depend not only on the pesticide but also on the dose, the route of administration, the time between poisoning and start of treatment, and patient's age [4,11,12]. Signs of intoxication may be seen lately in subcutaneous and intramuscular route of poisoning [13].

Unlike adults, infants mainly present with acute CNS depression and do not demonstrate the typical muscarinic effects. Symptoms such as increased body secretion, fasciculation and acute respiratory failure are more common in children. Tachycardia, rather than bradycardia, has been noted upon presentation in 49% of children presenting with organophosphate intoxication [14].

Organophosphate intoxications mostly occur in suicidal intent or by accident. Deaths due to injection of organophosphate are unusual [15]. Only a small number of cases of homicides by mixing the insecticide with the food of victims are reported [16]. In the literature, homicides by injection of toxic agents seem to be based on health care professionals [17] and a few homicide-suicide cases [15], except the case of intramuscular paraquat injection [18]. According to our knowledge, this is the first report of homicidal poisoning by injection of insecticides poisoning with complete recovery from toxicity.

Accidental organophosphate ingestions are mostly seen in active and exploratory period of childhood, in which they tend to take everything into their mouth, when parents are careless, neglectful or also when interfamilial conflicts are present [19]. Meadow mentioned the increased risk of deliberate poisoning in children especially under the age of 2½ years [20]. These poisonings may also be seen in the form of Munchausen syndrome by proxy [21]. Our case report emphasizes the necessity of a detailed history taken, circumstance evidence investigations and careful laboratory investigations for the possibility of homicide in such cases.

Although injection sites may be the expected results of medical treatment, dermal lesions also may be associated with injections of toxic substances [22]. Poisoning with organophosphates are the most common causes of intoxications in Egypt [23]. The routes of the

intoxication were gastrointestinal system, respiratory tract system and skin, however, it should be realized that parenteral intoxication may occur even with small amounts of the poison. Since the intoxication occurred by parentral injection, therapy was given earlier as a result of earlier symptoms and signs.

In this case report, we document a parental use of an organophosphate substance for homicidal purposes. Therefore signs such as miosis, increased secretion, bronchospasm, incontinence in urine and stool appeared after a short period. Atropine and the enzyme reactivator obidoxime were given as antidotal therapy for this poisoning. Eventually the baby got better after the fourth day of therapy.

On performing a careful and thorough history taken, meticulous medical examination and accurate toxicological laboratory test, it was clear that cause of illness was organophosphate intoxication by injection and it was a homicide attempt. Our case emphasizes the importance of careful medical examination and toxicological analysis in such cases.

References

- Eddleston M, Buckley NA, Eyer P, Dawson AH (2008) Management of acute organophosphorus pesticide poisoning. *Lancet* 371: 597-607.
- Badhe A, Sudhakar S (2006) An intravenous organophosphate poisoning with intermediate syndrome An unusual way of intoxication. *Indian J Crit Care Med* 10: 191-192.
- Raina S, Mahesh DM, Sood V, Kaushal SS, Gupta D (2008) Self injection of dichlorvos, an organophosphorus compound. *Online J Health Allied Sci* Vol. 7
- Güven M, Unluhizarci K, Goktas Z, Kurtoglu S (1997) Intravenous organophosphate injection: An unusual way of intoxication. *Hum Exp Toxicol* 16: 279-280.
- Aygun D, Doganay Z, Altinop L, Güven H, Onar M, et al. (2002) Serum acetylcholinesterase and prognosis of acute organophosphate poisoning. *J Toxicol Clin Toxicol* 40: 903-910.
- Leibson T, Lifshitz M (2008) Organophosphate and carbamate poisoning. Review of the current literature and summary of clinical and laboratory experience in southern Israel. *IMAJ* Nov.;10
- Aygun D (2004) Diagnosis in an acute organophosphate poisoning: report of three interesting cases and review of the literature. *Eur J Emerg Med* 11: 55-58.
- Lee P, Tai DY (2001) Clinical features of patients with acute organophosphate poisoning requiring intensive care. *Intensive Care Med* 27: 694-699.
- Reddy KS (2009) Toxicology general consideration. In: Reddy KS, editor. *The essentials of forensic medicine and toxicology*. 20th ed. Hyderabad: Suguna Devi 437-457.
- Caglar O, Hakan K, Yasar B, Cokhan Batuk, Hulya I (2009) Homicidal poisoning by injection of methidathion: The first ever report. *Hum Exp Toxicol* 8: 521.
- Premaratna R, Tilakaratna Y, Fonseka MM, Gunatilake SB, de Silva HJ (2001) Parasuicide by self-injection of an organophosphate insecticide. *Hum Exp Toxicol* 20: 377-378.
- Yurumez Y, Durukan P, Yavuz Y, Ikizceli I, Avsarogullari L, et al. (2007) Acute organophosphate poisoning in university hospital emergency room patients. *Intern Med* 46: 965-969.
- Nishioka Sde A (1994) Parenteral injection of organophosphate insecticide. Apropos of two cases. *Sao Paulo Med J* 112: 561-563.
- El-Naggar Ael-R, Abdalla MS, El-Sebaey AS, Badawy SM (2009) Clinical findings and cholinesterase levels in children of organophosphates and carbamates poisoning. *Eur J Pediatr* 168: 951-956.
- Peschel O, Betz P, Eisenmenger W (1995) Injection of toxic agents: an unusual cause of death. *Forensic Sci Int* 75: 95-100.
- Stephens BG, Moormeister SK (1997) Homicidal poisoning by paraquat. *Am J Forensic Med Pathol* 18: 33-39.
- Yorker BC, Kizer KW, Lampe P, Forrest AR, Lannan JM, et al. (2006) Serial murder by healthcare professionals. *J Forensic Sci* 51: 1362-1371.
- Chandrasiri N (1999) The first ever report of homicidal poisoning by intramuscular injection of Gramoxone (paraquat). *Ceylon Med J* 44: 36-39.
- Casey PB, Thompson JP, Vale JP (1994) Suspected paediatric pesticide poisoning in the UK. I-Home accident surveillance system 1982-1988. *Hum Exp Toxicol* 13: 529-533.
- Meadow R (1989) ABC of child abuse. Poisoning. *BMJ* 298: 1445-1446.
- Venneman B, Bajanowski T, Karger B, Pfeiffer H, Kohler H, et al. (2005) Suffocation and poisoning-the hard-hitting side of Munchausen syndrome by proxy. *Int J Legal Med* 119: 98-102.
- Buchman MT (2000) Upper extremity injection of household insecticide: a report of five cases. *J Hand Surg Am* 25: 764-767.
- Mahmoud K, Elguindi1, Heba M Halawa, Iman M Bayoumy (2008) Electroneurophysiological Monitoring as an Early Severity Predictor in Acute Anticholinesterase Poisoned Patient and the Effect of Oxime Therapy Manipulation. *Egypt J Neurol Psychiat Neurosurg* 45: 2.