

# Hybrid Therapy Using a Surgical Thrombectomy with a Balloon Angioplasty to Regain Thrombosed Dialysis Vascular Access-Clinical Case Series

Mehdi Davoodi<sup>1</sup>, Hossein Farsavian<sup>1\*</sup> and Ali Asghar Farsavian<sup>2</sup><sup>1</sup>Department of Vascular Surgery, Mazandaran University of Medical Sciences, Sari, Iran<sup>2</sup>Department of Cardiology, Mazandaran University of Medical Sciences, Sari, Iran

## Abstract

**Introduction:** Thrombectomy is the most common surgical method used to re-establish thrombosed vascular access, particularly in hemodialysis patients. To achieve better patient outcomes and to improve the prognosis for surgical thrombectomy, fistulography with balloon angioplasty to assist during surgery has been introduced in recent years.

**Methods:** In this study, the results of hybrid therapy in 53 patients with thrombosed vascular access were examined. The success rate for re-opening vascular access and dialysis success were recorded, immediately, and at 1 m and 6 m after the surgical procedure.

**Results:** Of 53 patients, 40 patients underwent balloon angioplasty. The success rate in the first session of dialysis after surgery was 85%. At 1 m and 6 m, the dialysis success rates were 75% and 55%, respectively.

**Conclusion:** The use of hybrid method to re-establish vascular access in hemodialysis patients was not only quite effective but also showed several advantages over other conventional methods. Using this method, possible thrombotic lesions were evaluated and corrected with balloon angioplasty. In addition to reducing the risk of recurrent path failure, all these procedures can be performed during one session in the operating room, which led to reductions in surgical and recovery time and costs for both the surgeons and the patients.

**Keywords:** Dialysis vascular access; Hybrid therapy; Surgical thrombectomy; Balloon angioplasty

## Introduction

Failure of vascular access in hemodialysis patients is one of the most common referrals that vascular surgeons encounter. Because of the poor patient outcomes due to vascular access thrombosis, several treatment methods have been developed to deal with this problem [1]. Traditionally, surgical thrombectomy, with or without revision surgery, was the primary method employed by vascular surgeons to re-establish vascular access [2,3]. Other less invasive methods, such as thrombolytic therapy or percutaneous mechanical thrombectomy also were introduced [4], and each of these methods have their advantages and disadvantages. Maintaining an open track within vascular access is important, because using a temporary catheter for dialysis is associated with many complications. In addition, a secondary surgery to establish a new access route requires more time and cost. To obtain better results and reduced failure risk, surgical thrombectomy, in association with balloon angioplasty, has been introduced in recent years.

In this clinical case series, we retrospectively presented the results of balloon angioplasty in combination with surgical thrombectomy as a hybrid therapy in 53 patients who had vascular access failure in the Imam hospital, in Sari, Iran, over a period from 2013-2014.

## Methods

Out of 53 patients, 13 patients had an anti-cubital arteriovenous fistula (AVF), 15 patients had basilica vein transposition (BVT), and 25 patients had arm arteriovenous grafts. After local anesthesia with or without IV sedation, in AVF and BVT patients, an incision was made across the skin on the dilated vein with no exploration, while in cases of AV graft, a transverse incision over the graft and 1-2 cm exploration was performed. Thrombectomy was performed by placing a Fogarty 3 or 4 catheter within the proximal and distal tract. Then both sides of the track were heparinized, by administering a single dose of 2500 IU intravenous heparin. In the cases with AV grafts, vascular clamps were

used for proximal control. In AVF and BVT cases, distal and proximal controls were performed by the surgical aid's hand. The graft's surgical site used a 6-0 suture.

In successful thrombectomy cases, a 4 Fr sheath was placed, and the upper extremity and central venous venography were performed. To evaluate arterial anastomosis, an area distal to the graft was pressed and blood flow was examined. After determining the location of any lesions, sheaths 6 Fr or 7 Fr were embedded, and the guidewire was passed through. Next, the balloon angioplasty with a 6-8 mm high-pressure catheter with 5 minutes inflation time was performed. In central lesions, a 12-14 mm catheter was used. If the first attempt was not successful, balloon angioplasty was repeated with a longer inflation time. The incision was closed using a silk skin purse technique and packed with finger pressure for 10 min.

Surgery and angiography results were recorded for each patient. Patient's follow-up was employed to gauge the success of the surgery for dialysis and vascular access patency immediately after balloon angioplasty and at 1 m and 6 m after the surgery.

## Results

The success rate of the initial thrombectomy was 75.4% (n=40), which included 22 graft, 7 AVF, and 11 BVT patients. The unsuccessful

**\*Corresponding author:** Hossein Farsavian, Assistant Professor of Vascular Surgery, Mazandaran University of Medical Sciences, Sari, Iran, Tel: +98 912 143 0086; E-mail: [h.farsavian@yahoo.com](mailto:h.farsavian@yahoo.com)

**Received** November 15, 2016; **Accepted** December 30, 2016; **Published** January 06, 2017

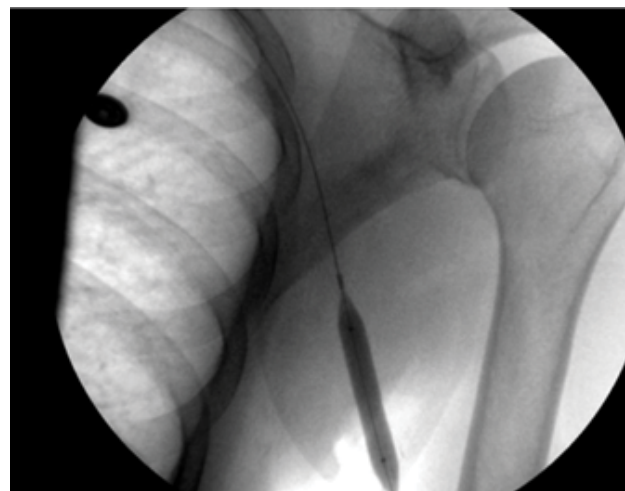
**Citation:** Davoodi M, Farsavian H, Farsavian AA (2016) Hybrid Therapy Using a Surgical Thrombectomy with a Balloon Angioplasty to Regain Thrombosed Dialysis Vascular Access-Clinical Case Series. *Surgery Curr Res* 7: 283. doi: [10.4172/2161-1076.1000283](https://doi.org/10.4172/2161-1076.1000283)

**Copyright:** © 2016 Davoodi M, et al. This is an open-access article distributed under the terms of the Creative Commons Attribution License, which permits unrestricted use, distribution, and reproduction in any medium, provided the original author and source are credited.

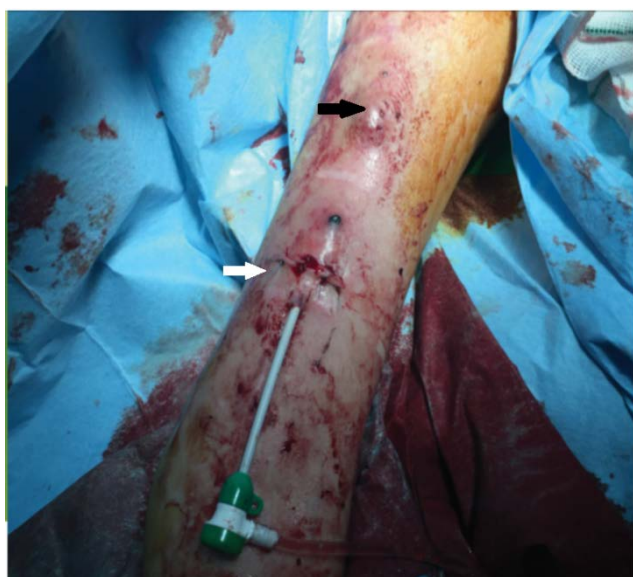
thrombectomy rate was 24.6% (n=13), including 6 AVF, 7 BVT, and 3 graft patients. The surgical thrombectomy procedure duration was  $15 \pm 4$  minutes. Angiography was performed in the successful thrombectomy cases (n=40), and 10 inflow stenoses, 22 outflow stenoses, and 2 both-tract stenoses were observed. For these patients, balloon angioplasty was performed, and the overall immediate success rate was 85%. The balloon angioplasty success rate in the correction of lesions in grafts (19 cases), AVF (6 cases) and BVT (9 cases) was 86.3%, 85.7% and 81.8%, respectively. The average surgical procedure duration for angioplasty was  $25 \pm 8$  minutes.

At 1 m after angioplasty, among 34 patients, 30 patients still had an active access path, for a 75% success rate. In 4 patients with vascular access thrombosis, surgical thrombectomy was performed and re-establishment was successful in 2 patients.

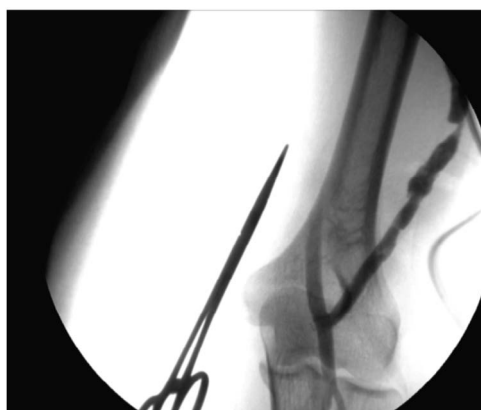At the 6 m follow-up, among 32 patients, 4 patients had died due to cardiovascular underlying problems. Among the remaining 28 patients, 22 patients still had a working vascular access route, for an overall 55% success rate at 6 m (Figures 1-3).



**Figure 3:** Balloon angioplasty.



**Figure 1:** Thrombectomy site (black arrow), Angioplasty sheath (white arrow).



**Figure 2:** Axillary vein stenosis after thrombectomy.

## Discussion

There are several methods used by vascular surgeons to deal with the failure of vascular access in hemodialysis patients, including surgical procedures, such as thrombectomy with or without revision, or less invasive approaches, such as thrombolytic therapy or mechanical thrombectomy. Each of these methods has their advantages and disadvantages [5]. The preservation of clear vascular access is crucial, because a temporary catheter used for dialysis is associated with many complications. Vascular access failure also requires another surgery to create an access route, resulting in additional time and costs for both the surgeon and the patient. Surgical thrombectomy and patch angioplasty were common treatments for vascular access failure in hemodialysis patients, which can be performed in a short time and are very effective [6]. These methods were the most effective in treating segmental lesions, but in multilevel and central lesions, due to possibly undiagnosed lesions in the vascular tract, no good prognoses were reported [6].

Therefore, surgeons perform thrombectomy along with other procedures to increase the immediate and long term prognosis [7]. Revision surgery remains one of the chosen methods, which surgeons perform in association with thrombectomy. However, revision surgeries require extra deep exploration, which can lead to potential nerve damage, increased risk of infection, and hematoma, as well as patient discomfort and a longer recovery time. In addition, possible future surgeries would be very difficult at the site [7]. Using less invasive approaches, such as thrombolytic therapy or mechanical thrombectomy, required longer surgical times and were more expensive. In addition, these methods usually were not as effective as thrombotic surgery and may have caused systemic thrombolytic complications, such as bleeding that required the patient to be hospitalized in the ICU. Furthermore, these methods were also associated with more technical errors, while requiring patients to use a temporary dialysis catheter for their first hemodialysis session [8,9]. The performance of a balloon angioplasty after surgical thrombectomy not only created better diagnosis and treatment of multilevel thrombosed lesions but also led to preserving a potential future surgical site while saving time and cost for patients.

In this clinical case series for patients with vascular access failure,

Study	Vascular access patency rate				
	1 month	2 month	4 month	5 month	6 month
Bortman et al. [10] (thrombectomy alone)	30%		10%		
Bortman et al. [10] (with revision)	59%		25%		
Bitar et al. [18] (with revision)	86%	45%			17%
Dapunt et al. [19] (with revision)	64.10%			28.90%	

**Table 1:** Vascular access patency rate after surgical thrombectomy alone or with revision surgery.

Study	Patients number	Vascular access patency rate				
		Immediately	1 month	3 month	5 month	6 month
Smith et al. [20]	19				58%	
Bitar et al. [18]	22		77%	40%		28%
Anin et al. [21]	48		45%	45%		33%
Po Jun et al. [11]	13		77%	62%		38%
Z.H et al. [22]						23%
Current study	53	85%	75%			55%

**Table 2:** Vascular access patency rate after hybrid procedure.

balloon angioplasty was performed after surgical thrombectomy (hybrid procedure) and thrombosed or stenotic lesions were corrected. The success rate of balloon angioplasty in the first session of dialysis after surgery was 85%, and at 1 m and 6 m after surgery was 75% and 55%, respectively. These results were much better than those for surgical thrombectomy alone [10,11]. In addition, the results of the hybrid method were much better than thrombolytic therapy alone [12-15]. Lee et al. studied the practice of mechanical thrombectomy, with or without thrombolytic agents, and reported an immediate success rate of 89.3%, but at 4 m follow-up, the vascular access patency declined to 25.6% [16]. Hybrid procedure also reported results comparable to or better than surgical thrombectomy with revision surgery [10,17] (Tables 1 and 2).

## Conclusion

According to our experience, surgical thrombectomy and balloon angioplasty, when used as a hybrid method in restoring vascular access in dialysis patients not only is quite effective but also provides several advantages over other conventional methods. In this study's proposed method, possible vascular tract thrombotic lesions and stenoses were evaluated and modified during a one-time operation, which led to reduced recurrent vascular failures, saving time and costs for patients.

## References

- Miller PE, Carlton D, Deierhoi MH, Redden DT, Allon M (2000) Natural history of arteriovenous grafts in hemodialysis patients. *Am J Kidney Dis* 36: 68-74.
- Wellington JL (1983) Salvage of thrombosed polytetrafluoroethylene dialysis fistulas by interposition grafting. *Can J Surg* 26: 463-465.
- Bell DD, Rosental JJ (1988) Arteriovenous graft life in chronic hemodialysis: A need for prolongation. *Arch Surg* 123: 1169-1172.
- Himmelfarb J, Saad T (1966) Hemodialysis vascular access: emerging concepts. *Curr Opin Nephrol Hypertens* 5: 485-491.
- Turmel-Rodrigues L, Sapoval M, Pengloan J, Billaux L, Testou D, et al. (1997) Manual thromboaspiration and dilation of thrombosed dialysis access: mid-term results of a simple concept. *J Vasc Interv Radiol* 8: 813-824.
- Marston WA, Criado E, Jaques PF, Mauro MA, Burnham SJ, et al. (1997) Prospective randomized comparison of surgical versus endovascular management of thrombosed dialysis access grafts. *J Vasc Surg* 26: 373-380.
- Bakran A, McWilliams RG (2001) Arteriovenous graft stenosis: an overview of treatment alternatives. *J Endovasc Ther* 8: 173-176.
- Dougherty MJ, Calligaro KD, Schindler N, Raviola CA, Ntoso A (1999) Endovascular versus surgical treatment for thrombosed hemodialysis grafts: A prospective, randomized study. *J Vasc Surg* 30: 1016-1023.
- Lombardi JV, Dougherty MJ, Veitia N, Somal J, Calligaro KD (2002) A comparison of patch angioplasty and stenting for axillary venous stenoses of thrombosed hemodialysis grafts. *Vasc Endovascular Surg* 36: 223-229.
- Brotman DN, Fandos L, Faust GR, Doscher W, Cohen JR (1994) Hemodialysis graft salvage. *J Am Coll Surg* 178: 431-434.
- Ko PJ, Liu YH, Hsieh HC, Chu JJ, Lin PJ (2003) Initial experience during balloon angioplasty assisted surgical thrombectomy for thrombosed hemodialysis grafts. *Chang Gung Med J* 26: 178-183.
- Uflacker R, Rajagopalan PR, Vujic I, Stutley JE (1996) Treatment of thrombosed dialysis access grafts: randomized trial of surgical thrombectomy versus mechanical thrombectomy with the Amplatz device. *J Vasc Interv Radiol* 7: 185-192.
- Summers S, Drazan K, Gomes A, Freischlag J (1993) Urokinase therapy for thrombosed hemodialysis access grafts. *Surg Gynecol Obstet* 176: 534-538.
- Vesely TM, Idso MC, Audrain J, Windus DW, Lowell JA (1996) Thrombolysis versus surgical thrombectomy for the treatment of dialysis graft thrombosis: pilot study comparing costs. *J Vasc Interv Radiol* 7: 507-512.
- Barth KH, Gosnell MR, Palestrant AM, Martin LG, Siegel JB, et al. (2000) Hydrodynamic thrombectomy system versus pulse-spray thrombolysis for thrombosed hemodialysis grafts: a multicenter prospective randomized comparison. *Radiology* 217: 678-684.
- Lee HS, Park PJ (2014) Clinical outcome of percutaneous thrombectomy of dialysis access thrombosis by an interventional nephrologist. *Kidney Res Clin Pract* 33: 204-209.
- Schwartz CI, McBrayer CV, Sloan JH, Meneses P, Ennis WJ (1995) Thrombosed dialysis grafts: comparison of treatment with transluminal angioplasty and surgical revision. *Radiology* 194: 337-341.
- Bitar G, Yang S, Badosa F (1997) Balloon versus patch angioplasty as an adjuvant treatment to surgical thrombectomy of hemodialysis grafts. *Am J Surg* 174: 140-142.
- Dapunt O, Feurstein M, Rendl KH, Prenner K (1987) Transluminal angioplasty versus conventional operation in the treatment of haemodialysis fistula stenosis: results from a 5-year study. *Br J Surg* 74: 1004-1005.
- Smith TP, Cragg AH, Castaneda F, Hunter DW (1989) Thrombosed polytetrafluoroethylene hemodialysis fistulas: salvage with combined thrombectomy and angioplasty. *Radiology* 171: 507-508.
- Anain P, Shenoy S, O'Brien-Irr M, Harris LM, Dryjski M (2001) Balloon angioplasty for arteriovenous graft stenosis. *J Endovasc Ther* 8: 167-172.
- Haskal ZJ, Trerotola S, Dolmatch B, Schuman E, Altman S, et al. (2010) Stent graft versus balloon angioplasty for failing dialysis-access grafts. *N Engl J Med* 362: 494-503.