

## IgG Monoclonal Immunoglobulin (M-protein) as Factor V Inhibitor in Multiple Myeloma Patient: Case Report and Discussion

Lewandowski Krzysztof<sup>1\*</sup>, Szczepaniak Tomasz<sup>1\*</sup>, Dytfeld Dominik<sup>1</sup>, Wojtasińska Ewelina<sup>1</sup>, Dziatkiewicz Paulina<sup>1</sup>, Przysiecka Łucja<sup>2</sup>, Borowczyk Martyna<sup>1</sup>, Popławski Dariusz<sup>3</sup> and Komarnicki Mieczysław<sup>1</sup>

<sup>1</sup>Department of Hematology and Bone Marrow Transplantation, Poznan University of Medical Sciences, Szamarzewskiego 82/84, Poznan, Poland

<sup>2</sup>Nanobiomedical Centre, Adam Mickiewicz University, Umultowska 85, Poznan, Poland

<sup>3</sup>Department of Radiology, University Lord's Transfiguration Hospital, Szamarzewskiego 82/82, Poznan, Poland

\*Authors are equally contributed to this study

\*Corresponding author: Lewandowski Krzysztof, Department of Hematology and Bone Marrow Transplantation, Poznan University of Medical Sciences, Szamarzewskiego 82/84, Poznan, Poland, Tel: +48618549356; E-mail: [krzysztof.lewandowski@skpp.edu.pl](mailto:krzysztof.lewandowski@skpp.edu.pl)

Received date: February 11, 2016; Accepted date: April 18, 2016; Published date: April 25, 2016

Copyright: © 2016 Lewandowski K, et al. This is an open-access article distributed under the terms of the Creative Commons Attribution License, which permits unrestricted use, distribution, and reproduction in any medium, provided the original author and source are credited.

### Abstract

We present a case of a 53-year-old male with a symptomatic relapse of IgG $\lambda$  multiple myeloma who was readmitted to the hospital with clinical symptoms of retroperitoneal hematoma. Laboratory tests revealed high concentration of monoclonal immunoglobulin G (32 g/l, 91.6% of total IgG) in the serum, prolongation of activated partial thromboplastin time (aPTT), prothrombin time (PT), and thrombin time (TT), significantly decreased factor V procoagulant activity and the presence of factor V inhibitor. After successful retreatment with the use of six cycles of bortezomib, adriamycin and dexamethasone, the monoclonal IgG concentration in the patient's serum significantly decreased (up to 1.3 g/l). At that time, also the normalization of the results of aPTT, PT and TT was stated. Therefore, the presence of factor V inhibitor in monoclonal immunoglobulin fraction was suspected. To confirm this, the monoclonal immunoglobulin G from the patient's initial blood sample was isolated, a series of dilutions of it in standard human plasma was prepared and the activity of factor II, factor V and aPTT, PT and TT in the prepared plasma samples were measured. The results of *ex vivo* studies matched those obtained *in vivo*, proving that the monoclonal immunoglobulin G produced by multiple myeloma cells acted as a factor V inhibitor.

**Keywords:** Multiple myeloma; Factor V deficiency; Factor V inhibitor; M protein; Bleeding complications

### Introduction

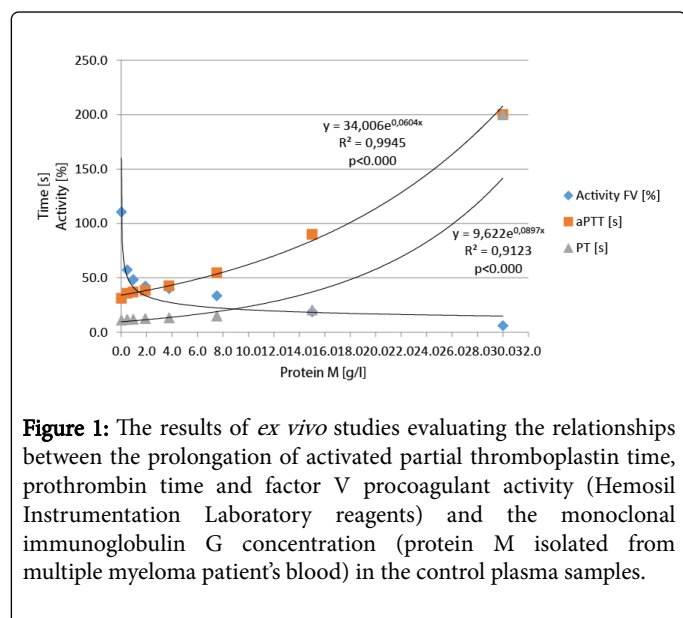
Multiple myeloma (MM) is a genetically heterogeneous tumour of transformed plasma cells, terminally differentiated effectors of the B cell lineage, specialized in producing large amounts of monoclonal immunoglobulins (M-protein) [1]. Irrespectively of typical symptoms, MM patients present a broad spectrum of uncommon disease signs, among which coagulation abnormalities constitute an important clinical problem [2]. Unlike venous thromboembolism, which is relatively frequent, major bleeding remains uncommon, ranging from 0-7% in patients newly diagnosed with MM [3,4]. Due to its infrequency, the management of bleeding complications is often symptomatic and based on standard recommendations. Due to complex pathogenesis of the bleeding predisposition in MM, the lack of access to experienced hemostasis laboratory differential diagnosis remains challenging [5]. Until today, only a few cases of bleeding manifestation of relapsed MM have been reported [6,7].

### Case

Herein, we present a case of 53-years-old Caucasian male patient with symptomatic IgG $\lambda$  multiple myeloma, stage IIIA according to Durie-Salmon classification. The initial treatment with thalidomide and dexamethasone (TD) resulted in a very good partial response (VGPR). At the time of autologous hematopoietic stem cell transplantation (autoHSCT), routine coagulation tests were normal.

After autoHSCT he did not receive any maintenance therapy. The patient was readmitted to our department with malaise and abdominal pain of moderate intensity two years after autoHSCT. During hospitalization the pain deteriorated, peritoneal pressure symptoms became positive and nasal bleeding appeared. The abdominal ultrasonography (USG) showed a little amount of fluid in the right lower part of the peritoneal cavity and thickening of the intestinal wall. Computed tomography image showed enlargement of the right iliopsoas muscle. At the time of the admission, the laboratory tests revealed high concentration of monoclonal immunoglobulin G (32 g/l, 91.6% of total IgG) in the serum. The coagulation tests results showed prolongation of activated partial thromboplastin time (aPTT), prothrombin time (PT) and thrombin time (TT). The PT and the aPTT were not corrected with an equal volume plasma mixing test, which is indicative for circulating anticoagulant. Additionally performed coagulation tests confirmed significantly decreased factor V procoagulant activity and the presence of factor V inhibitor (5 Bethesda Units/ml). Screening tests for lupus-like inhibitor (LA) performed according to the manufacturer's instruction (Lupus anticoagulant testing, Siemens) were negative (LA1/LA2-1.01; aPTT with Actin-32.7 sec.). Based on both the clinical signs of appendicitis, a decision to perform an appendectomy was made. During the procedure, a retroperitoneal hematoma was found and evacuated. There were no signs of appendicitis. After treatment with tranexamic acid and fresh frozen plasma the bleeding subsided. Thereafter, due to disease progression, six cycles of bortezomib, doxorubicin, and dexamethasone (PAD) were given. During the PAD treatment, the monoclonal IgG concentration in patient's serum significantly

decreased (up to 1.3 g/l). Finally, also normalization of the results of aPTT, PT and TT was stated. Therefore, the presence of factor V inhibitor in monoclonal immunoglobulin fraction was suspected. To confirm this, the retrospective, more detailed coagulation system analysis was undertaken. Activity of factor II, V, VIII and X was determined with the help of coagulometric methods and Helena BioSciences reagents. Coagulation system *ex vivo* studies were performed in normal human plasma after addition of lyophilized monoclonal IgG, isolated with the help of thiophilic adsorption method from 20 ml of the patient's blood collected at the time admission [8-10]. Thereafter, the activity of factor II, factor V and aPTT, PT and TT in the prepared plasma samples (a series of dilutions of monoclonal IgG in standard human plasma at final concentration of 0, 0.468, 0.937, 1.875, 3.75, 7.5, 15 and 30 g/l, respectively) were measured. Results of the coagulation system evaluation before and during the treatment with PAD are presented in Table 1. The results of the performed *ex vivo* studies showed close relationship between the monoclonal immunoglobulin G plasma content and the degree of prolongation of PT and aPTT (Figure 1).



**Figure 1:** The results of *ex vivo* studies evaluating the relationships between the prolongation of activated partial thromboplastin time, prothrombin time and factor V procoagulant activity (Hemosil Instrumentation Laboratory reagents) and the monoclonal immunoglobulin G concentration (protein M isolated from multiple myeloma patient's blood) in the control plasma samples.

Interestingly, it matched those obtained *in vivo*. This may prove the concept that the monoclonal immunoglobulin G produced by multiple myeloma cells may act as a factor V inhibitor.

The impact of isolated M protein on factor II procoagulant activity was also studied in the *ex vivo* assay. The decrease of factor II activity was only observed at very high concentration of M protein in the plasma sample. In our opinion, this phenomenon is the effect of inhibition of factor V by M protein, which is a very important player in the prothrombinase complex. To support this hypothesis, additional *ex vivo* studies were performed, examining the inhibitory effect of M protein on thrombin time. They confirmed only a slight prolongation of thrombin time at high concentration of M protein in the plasma sample (Supplementary Figure 1). Also 2D crossed electrophoresis studies did not confirm M protein and thrombin (bovine) cross reactivity (data not shown).

Tests	Normal value	Bortezomib- based therapy		
		Before	After	
			3 courses	6 courses
PT [s]	11.7-13.4	32.5	27.6	18.4
aPTT [s]	28.0-35.0	48	35.9	30.4
aPTT (1+1)	ND	No correction	No correction	ND
TT [s]	12.0-17.0	>300	45.5	10.8
FII activity [%of normal value]	50-150%	50.1	ND	ND
FV activity [% of normal value]	62-139	16.2	35	48.9
FVIII activity [% of normal value]	50-150	199	ND	ND
FX activity [% of normal value]	77-131	75.8	ND	ND
Fibrinogen concentration [g/l]	1.8-3.5	4.9	ND	ND
vWf: Ag [% of normal value, blood group non-O]	66.1-176.3	140	ND	ND
LA1/LA2 [ratio]	<1.30	1.01	ND	ND
MCF [mm]	50-72	97	ND	ND
<b>Serum concentration</b>				
Monoclonal IgG (protein M) (g/l)		32.0	20	1.3
Total IgG (g/l)		34.9	24.3	6.1
Total lambda free light chain (mg/l)		0.562	0.262	0.314
<b>Abbreviations:</b> PT- prothrombin time, aPTT- Activated Partial Thromboplastin Time, TT- Thrombin Time, (1+1) - Equal Plasma Volume Mixing Test, FII- Factor II, FV- Factor V, FVIII- Factor VIII, FX- Factor X, vWf:Ag- von Willebrand Factor Antigen, LA- Lupus Anticoagulant, MCF- Maximal Clot Firmness (EXTEM mode), ND- Not Done				

**Table 1:** The results of coagulation system evaluation in patient with recurrent multiple myeloma and retroperitoneal hematoma during treatment with bortezomib - based therapy. Bottom part of the Table shown the results of periodic monitoring of monoclonal protein concentration in the serum

**Discussion**

Patients with MM are a high-risk group as far as the emergence of unexpected events is concerned, and therefore there very frequently arises the need for immediate medical intervention [3]. In the presented case, USG imaging was not able to identify the bleeding episode, in contrast to angio-CT. However, it should be remembered that the diagnostic algorithm of hemoglobin and hematocrit drop in a patient with abdominal pain requires a customized procedure, including detailed laboratory evaluation of hemostasis

The pathogenesis of the observed clotting abnormalities in the presented patient is probably complex [11,12]. The increased fibrinogen concentration at the disease relapse is the result of disease activity and/or the coexistence of damaged muscle tissue. The high blood concentration of the M protein, with its impact on fibrin polymerization process, may be the cause of the prolongation of not only aPTT and PT, but also TT [13]. Interestingly, the results of equal volume plasma mixing test, before and during PAD treatment, showed no significant correction of the TT value in the beginning. However, later rapid normalization of abnormal test value was observed. The instant shortening of the TT right after the dilution of the M protein plasma content with fresh frozen plasma, supports the thesis that high concentration of monoclonal protein nonspecifically inhibits the fibrinogen polymerization. The value of PT and the aPTT was normalized when the factor V activity reached the level of 35%. The time for normalization of the PT and the aPTT was longer than in the case of TT. There was, however, close association between PT and aPTT values and the concentration of monoclonal immunoglobulin in the patient's serum. Also, the results of periodically performed equal volume mix tests in case of PT and aPTT documented the normalization of abnormal coagulation tests results when chemotherapy related reduction of the monoclonal IgG serum content was noted. These facts, along with the result of the inhibitor titer measurement (Bethesda assay), suggested the presence of cross reacting factor V inhibitor in monoclonal immunoglobulin fraction. This was confirmed by our *ex vivo* studies.

## Conclusion

To the best of our knowledge, the literature provides for only one reported case of factor V inhibitor in a MM patient with inherited factor V deficiency. Interestingly, the inhibitor completely disappeared after successful treatment with thalidomide [14]. This supports our thesis that protein M may act as a clotting factor inhibitor. Therefore, in our opinion it seems to be reasonable to recommend a detailed coagulation evaluation in MM patients with bleeding complications and prolongation of screening coagulation tests.

## Disclosure of Conflict of Interests

Szczepaniak Tomasz: SC in Clinical Trials ran by Janssen-Cilag, Amgen, Onyx; received a fee for hematological workshop in September 2015 from Celgene; Dytfeld Dominik: Co-Investigator in Clinical Trials ran by Janssen-Cilag, Amgen, Onyx; received a grant from Janssen, Advisory Board Member: Celgene, Amgen, Janssen, Novartis; Komarnicki Mieczysław: Principal Investigator in Clinical Trials ran by Janssen-Cilag, Amgen, Onyx

The other authors declare that they have no competing interests.

## Ethics Statement

This study was performed in agreement with the Declaration of Helsinki and approved by the local Ethical Committee (Poznan University of Medical Sciences).

## References

1. Auner HW, Cenci S (2015) Recent advances and future directions in targeting the secretory apparatus in multiple myeloma. *Br J Haematol* 168: 14-25.
2. Eby CS (2007) Bleeding and thrombosis risks in plasma cell dyscrasias. *Hematology Am Soc Hematol Educ Program*.
3. Kyle RA (1975) Multiple myeloma: review of 869 cases. *Mayo Clin Proc* 50: 29-40.
4. Kyle RA, Gertz MA, Witzig TE, Lust JA, Lacy MQ, et al. (2003) Review of 1027 patients with newly diagnosed multiple myeloma. *Mayo Clin Proc* 78: 21-33.
5. Eby C (2009) Pathogenesis and management of bleeding and thrombosis in plasma cell dyscrasias. *Br J Haematol* 145: 151-163.
6. Yılmaz B, Köklü S, Kulaç I (2013) Relapse of multiple myeloma presenting with melena. *Dig Endosc* 25: 208-209.
7. Reddy N, Karampelas I, Chanan-Khan A, Fenstermaker R, Padmanabhan S (2007) Aggressive relapse of multiple myeloma with intracerebral extension and associated hemorrhage. *Leuk Lymphoma* 48: 1228-1230.
8. Porath J, Maisano F, Belew M (1985) Thiophilic adsorption--a new method for protein fractionation. *FEBS Lett* 185: 306-310.
9. Boschetti E (2001) The use of thiophilic chromatography for antibody purification: a review. *J Biochem Biophys Methods* 49: 361-389.
10. Lihme A, Heegaard PM (1991) Thiophilic adsorption chromatography: the separation of serum proteins. *Anal Biochem* 192: 64-69.
11. Colwell NS, Tollefsen DM, Blinder MA (1997) Identification of a monoclonal thrombin inhibitor associated with multiple myeloma and a severe bleeding disorder. *Br J Haematol* 97: 219-226.
12. Glaspy JA (1992) Hemostatic abnormalities in multiple myeloma and related disorders. *Hematol Oncol Clin North Am* 6: 1301-1314.
13. Carr ME Jr, Dent RM, Carr SL (1996) Abnormal fibrin structure and inhibition of fibrinolysis in patients with multiple myeloma. *J Lab Clin Med* 128: 83-88.
14. Perez Botero J, Burns D, Thompson CA, Pruthi RK (2013) Successful treatment with thalidomide of a patient with congenital factor V deficiency and factor V inhibitor with recurrent gastrointestinal bleeding from small bowel arteriovenous malformations. *Haemophilia* 19: e59-61.