

Immunohistopathological Studies on Rats Injected with CCl₄ and Treated with Propolis and Honey Bee

Kadry A Elbakry, Nahed A Omar* and Shaymaa M Nasr

Department of Zoology, Faculty of Science, Damietta University, New Damietta City, Damietta, Egypt

Abstract

Background: The liver and kidneys play a pivotal role in the metabolism of nutrients, drugs, hormones, metabolic waste products and thereby maintaining body homeostasis. The present study was planned to demonstrate the favorable hepatonephroprotective effect of honey or propolis against CCl₄ histopathological, histochemical and immunohistochemistry.

Material and methods: Rats were randomly divided into 4 groups:

The first group of 10 rats serves as control. The second were maintained as CCl₄, then third and fourth maintained as honey and propolis respectively for period of experiment (6 weeks). Pieces of liver and kidney were subjected to histopathological and immunohistochemistry procedures and the obtained sections (5 μm thick) were stained with H&E also with silver nitrate stain and anti laminin antibody for immuno- histochemistry.

Result: Marked histopathological alteration were observed in the studied sections under the influence of CCl₄, the most common changes were cloudy swelling of hepatocytes, fatty changes, clear vacuolation of renal cells and congested blood vessels. After treated with honey and propolis showed improvement of hepatocytes and renal tissues.

Conclusion: This study indicated that CCl₄ has a toxic effect on liver and kidney. Honey and propolis improve the structural integrity of the cell membrane and ameliorates histopathological, histochemical and immunohistochemistry changes.

Introduction

Carbon tetrachloride is widely used as hepatotoxic compound for screening the anti-hepatotoxic/hepatoprotective activity of drugs in experimental model systems, because CCl₄-induced hepatotoxicity is regarded as an analogue of liver injury caused by a variety of hepatotoxicity in man. It has been generally reported and accepted that CCl₄-induced hepatotoxicity due to its hepatotoxic metabolites and trichloromethyl free radicals (•CCl₃) induced lipid peroxidation [1,2]. Therefore, one of the therapeutic strategies against liver injury is to find antioxidant compounds that are able to block liver injury through scavenging of trichloromethyl free radicals generated by CCl₄ [2].

Propolis is a resinous hive product collected by honey bees from exudates and buds of plants and mixed with wax and bee enzymes [3,4]. It also contained flavonoids, sugar, and aliphatic acids. Flavonoids are thought to be responsible for many of its biological and pharmacological activities including anticancer [5], anti-inflammatory [6] and antioxidant effects [7]. Propolis has several biological and pharmacological properties, as antimicrobial [8], anti-inflammatory [9], antioxidant [10, 11], antiparasitic [12], immune modularity and immune stimulant effects and it increased the percentage of protected animals suggesting its use in vaccines as an adjuvant [13,14].

Honey is one of honey bees' products which are used in medicine in many cultures since ancient times. Honey is the main source of concentrated sweetness in the diet of many people and contained about 80% carbohydrate, 20% water and traces of protein and ash [15]. Honey is known to exhibit a broad spectrum of activities including antiviral, antibacterial and immunostimulant [16]. It was found to have antioxidant activity due to its high content of flavonoids [17,18]. The aim of the present study is to determine the pathological findings in liver and kidney tissues due to CCl₄ toxicity and the therapy of honey and propolis. Also, Immuno-staining of laminin in kidney and liver tissues before and after therapy.

The human body is exposed nowadays to increasing attacks by toxic compounds in polluted air, industrially processed foods, alcohol

and drug consumption that increase liver toxicity, leading to more and more severe cases of hepatic disorders [19].

Material and Methods

Animals

Forty male albino Wistar rats weighing 120-140 g were purchased from Helwan animal station, Ministry of Health, Egypt. Animals were allowed to adapt for two weeks and housed in animal house of Zoology Department, Faculty of Science, Damietta University, Egypt. CCl₄ used in the present study purchased from Modern lab Co. for Chemicals, Egypt. Honey were purchased from general markets in New Damietta City, Damietta, Egypt. Propolis was purchased from local pharmacy.

Preparation of propolis

The method was done according to [20], briefly, the propolis was prepared by dissolving 16.8 mg in 10 ml of distilled water. After shaking for 10 minutes, the water extract was centrifuged at 1000 rpm for 10 minutes. The supernatant of the water extract was used for the treatment of rats.

Experimental groups

Rats were divided into 4 groups each of 10 rats. Normal control group: Fed in standard food and water. CCl₄ group: injected ip with

*Corresponding author: Nahed A. Omar, Department of Zoology, Faculty of Science, Damietta University, New Damietta City, Damietta, Egypt, E-mail: nahedomar2000@yahoo.com

Received June 30, 2015; Accepted July 04, 2015; Published July 14, 2015

Citation: Elbakry KA, Omar NA, Nasr SM (2015) Immunohistopathological Studies on Rats Injected with CCl₄ and Treated with Propolis and Honey Bee. Pigmentary Disorders 2: 197. doi:10.4172/2376-0427.1000197

Copyright: © 2015 Elbakry KA, et al. This is an open-access article distributed under the terms of the Creative Commons Attribution License, which permits unrestricted use, distribution, and reproduction in any medium, provided the original author and source are credited.

0.5 mg/kg of b. wt. of CCl₄ twice weekly for six weeks. Honey group: injected ip with 0.5 mg/kg of b. wt. of CCl₄ twice weekly for six weeks and treated with 10% honey bee in drinking water daily. Popolis group: injected ip with 0.5 mg/kg of b. wt. of CCl₄ twice weekly for six weeks and treated with propolis orally, (40 µl/rat/day) day after day for six weeks.

Histological study

For light microscopic examination: Liver and kidney samples were collected and fixed in 10% buffered formalin for 24 hours. Serial 5 µm paraffin sections were prepared for pathological study, with hematoxylin and eosin (H&E), Masson Trichrome (MT), silver nitrate and immunohistochemical examination with anti laminin antibody.

H/E stain

Liver tissue specimens were fixed in 10% formalin and embedded in paraffin wax and 5 micrometer thickness were cut. Sections were stained with H/E stain according to Drury and Wallington [21].

Masson trichrome stain

The method was done according to Carson [22]. Briefly, liver specimens were fixed in Zinker solution for 24 hours, washed in 50% alcohol and treated with diluted iodine solution, then washed in 3% sodium thiosulphate. Sections were stained firstly with haematoxylen, then with Masson A solution for 5 minutes. They were washed in distilled water and stained with Masson B solution for 5 minutes and differentiated in 1% phosphomolybdic acid for 5 minutes, stained with 2.5% fast green solution for 2 minutes, then differentiated in 1% glacial acetic acid. Sections were dehydrated, cleared in xylene and mounted with DPX.

Silver stain

Many methods of silver staining have been developed. Two general classifications are :-1) silver amine or alkaline method, and 2) silver nitrate or acidic method [23]. Detection levels of proteins using the various staining methods are determined by how quickly the back-ground develops. The silver amine methods usually have lower background than the silver nitrate methods and, therefore, have typically been more sensitive. A drawback to the use of the silver diammine method is the use of glutaraldehyde for fixing and sensitization [24,25]. Glutaraldehyde is not compatible with matrix-assisted laser desorption/ion- ization mass spectrometry (MALDI-MS) [26-28] because it causes protein-protein cross-linkages. The use of various types of sensitizers with the silver nitrate method has been shown to decrease the background and increase detection sensitivity. The ProteoSilver™ Kits are silver nitrate-based with a unique sensitizer solution and optimized protocols which produces better sensitivity (0.1 ng/mm²) than typically claimed using a silver amine method, but is MALDI-MS compatible [29,30]. The ProteoSilver Plus Kit also contains destaining solutions for removal of silver ions from excised bands for enhanced MALDI-MS sensitivity [31].

Immunohistochemistry

Hepatic tissues were processed to paraffin blocks. Sections were dewaxed in xylene and rehydrated in descending grades of alcohol. Microwave antigen retrieval in 10 mM sodium citrate at pH 6 was carried out for 20 minutes. Sections were subsequently covered with 3% hydrogen peroxide for 10 minutes. Sections were hydrated in descending series of alcohol. Sections were covered with 100 µl of PBS containing 10% normal swine serum for 1 hour in humified chamber to reduce unspecific background staining. 100 µl of rabbit anti-laminin

(Muri Lab Prep) (diluted 1:50 in blocking buffer) were applied to slides overnight at 4°C in humified chamber, then sections washed in PBS 3 times. 100 µl of biotinylated swine anti-rabbit antibody diluted 1:500 in blocking buffer were applied for 2 hours in humified chamber. After washing in PBS , 100 µl of Avidin –Biotin complex was added for two hours in humified chamer. 100 µl of freshly prepared diaminobezidine-HCl (Sigma) were added to devlope colour for 12 minutes. Sections were washed in running water to stop colour development . Sections were dehydrated, counterstained and coverslip in Permount [32]. Assessment of HBeAg and its antibodies may be an important predictor of which chronic carriers of HBV will develop chronic active liver disease [33].

Results

Liver histopathology

H/E stain: The hepatocytes showed acidophilic cytoplasm with single central rounded vesicular nuclei and some of the cells were binucleated (Figure 1). In group II (CCL₄ alone group), most of the hepatocytes contained multiple, large cytoplasmic vacuoles and some hepatocytes had deeply acidophilic cytoplasm and deeply stained nuclei (Figure 2). After P and H administration, remarkable improvement in the hepatocytes was noticed as they appeared nearly similar to that of the control rats. Only few hepatocytes appeared with slight vacuolated cytoplasm (Figure 3). On the other hand, in the CCL₄/recovery group the liver was still markedly affected. Hepatocytes appeared with highly vacuolated cytoplasm and deeply stained nuclei (Figure 4).

Masson's trichrome stain: In Masson's trichrome stained sections

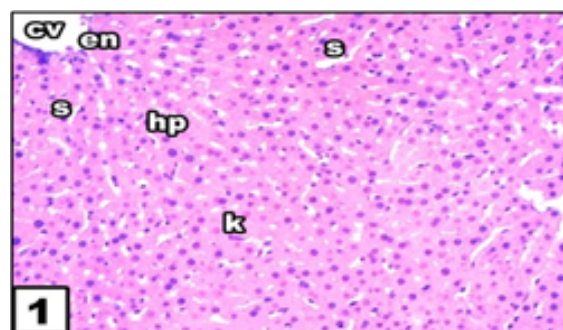


Figure 1: Light photomicrograph of liver section from control untreated rat showing central vein (CV) lined by endothelial cells (en), hepatic cells (hp), kupffer cells (K) and narrow sinusoid (S). (H&E, 400x).

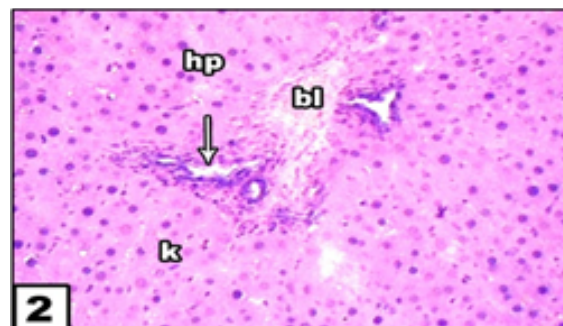


Figure 2: Liver section After 6 weeks CCl₄ treated rat showing inflammatory cell collection spaces of sinusoids (arrow) hepatocyte degeneration and congested blood vessels.

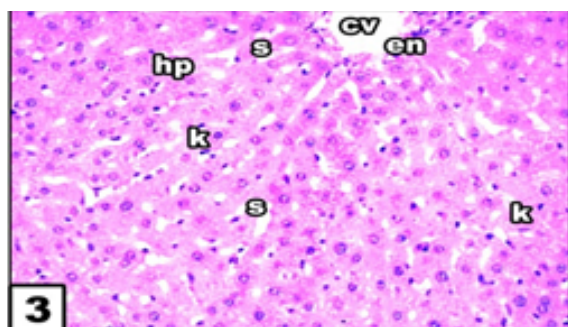


Figure 3: After 6 weeks CCl₄ rat treated with honey bee showing improvement of hepatic architecture.

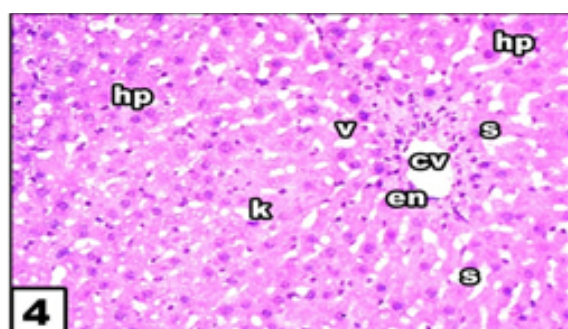


Figure 4: After 6 weeks CCl₄ rat treated with propolis showing normal lobular architecture with well brought out central vein and prominent nucleus and nucleolus.

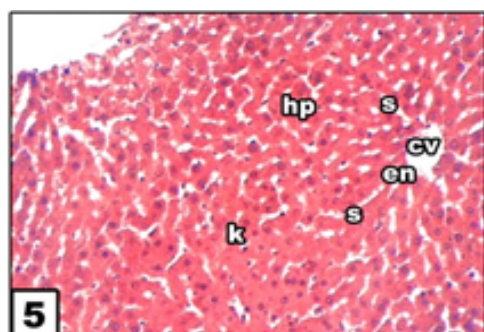


Figure 5: Light photograph of liver section after control untreated rat showing central vein (CV) lined by endothelial cells (en), hepatocytes (hp), Kupfer cells (K) and narrow sinusoid (S). (Masson Trichrom, 400x).

the parenchyma of the liver in control groups appeared to be supported with a stroma of very delicate meshwork of collagenous fibers. Few collagenous fibers surrounding the central veins, in portal area and in capsules were seen (Figure 5). In subgroup IIA (CCl₄ alone group), the stroma was well defined. There was thick connective tissue capsule and an apparent increase in the collagen fibers around the central veins, in between hepatocyte cords and in portal areas (Figure 6). In CCl₄/P and H groups, few collagen fibers were detected (Figure 7) while in the CCl₄/recovery group the collagen fibers were very numerous (Figure 8).

Silver stain: In silver nitrate stained sections, Histology of liver sections of normal control animals (group 1) showed normal liver

architecture with central vein, and cytoplasm and prominent nucleus and nucleolus were preserved (Figure 9). The liver sections of CCl₄ treated animals (group 2) showed degeneration in sinusoids and become as vacuoles (Figure 10). Honey bee and propolis treatment (group 3,4) appeared to significantly prevent the CCl₄ toxicity as revealed by the hepatic cells which were preserved cytoplasm. This also caused a marked decrease in inflammatory cells (Figures 11 and 12).

Kidney histopathology

H/E satin: In Heamatoxin and eosin stained sections, CCl₄ administration alone caused prominent histopathological damage in the kidney compared with the control rats (Figure 13). The kidney sections from the control- and honey-treated groups showed normal glomeruli, and tubulointerstitial cells (Figure 14). In contrast, the

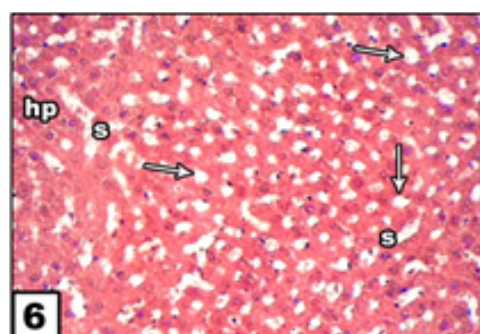


Figure 6: Liver section after 6 weeks CCl₄ treated rat showing degeneration of sinusoids that become as vacuoles (arrow).

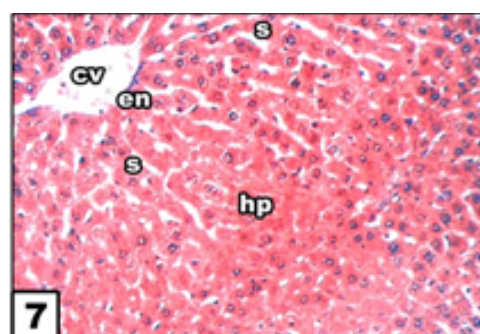


Figure 7: Liver section after 6 weeks CCl₄ treated with honey bee showing improvement of general hepatic architecture.

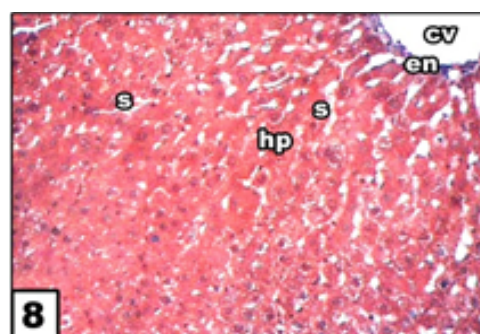


Figure 8: After 6 weeks CCl₄ treated with propolis showing regeneration in hepatic architecture nearly as seen in control group and vacuolation decreased.

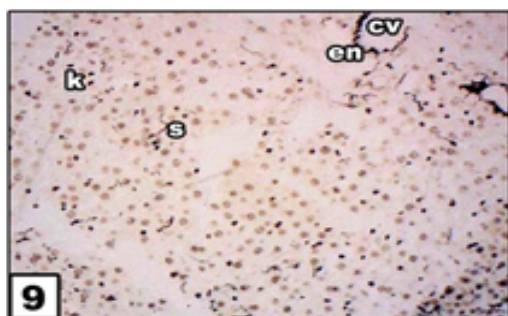


Figure 9: Photomicrograph of liver section from control untreated rat showing stained reticular fibers displaying central vein (cv) lined by endothelial cells(en), kupffer cells(k) and narrow sinusoids(s). (Silver nitrate.400X).

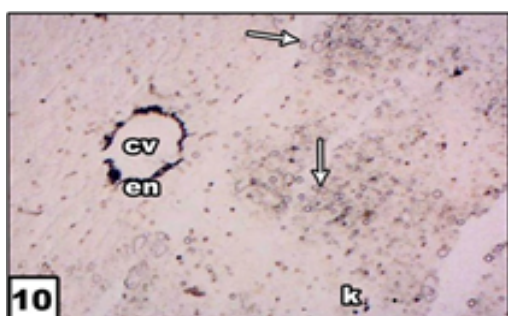

Figure 10: Liver section after 6 weeks CCl₄ treated rats showing stained reticular fibers displaying increase in vacuoles (arrows) and mononuclear cells degeneration.

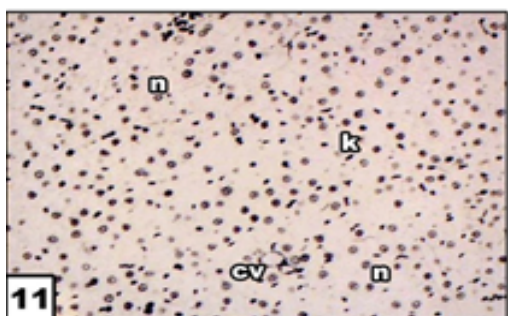


Figure 11: Liver section after 6 weeks CCl₄ treated with honey bee showing improvement of general hepatic architecture and normal prominent nucleus (n).

kidneys of CCl₄-treated rats showed marked deleterious histological changes. The kidney sections showed significant glomerular and tubular degenerations varying from, glomerular basement thickening, interstitial inflammation, tubular cell swelling, pycnotic nuclei, medullary vascular congestion and moderate to severe necrosis (Figure 15). propolis-treated group of rats preserved normal morphology of the kidney and shows normal architecture of the kidney (Figure 16).

Masson trichrome stain: In masson trichrome stained sections, histology of Kidney sections of normal control animals (group 1) showed normal kidney architecture (Figure 17). The kidney sections of CCl₄ treated animals (group 2) showed clear vacuolation of cells and dilation in space of bowmans capsule (Figure 18). Honey bee and propolis treatment (group 3,4) appeared to significantly prevent the

CCl₄ toxicity with regeneration in glomeruli and interstitial spaces nearly as seen in normal control (Figures 19 and 20).

Sliver nitrate: In silver nitrate stained sections Histopathological changes in Kidney sections of normal control animals (group 1) showed normal structure of glomerulus and bowman capsule (Figure 21). The kidney sections of CCl₄ treated animals (group 2) showed clear vacuolation of cells and dilation in space of bowman's capsule (Figure 22). Honey bee and propolis treatment (group 3,4) appeared to significantly prevent the ccl4 toxicity with regeneration in glomeruli and interstitial spaces nearly as seen in normal control (Figures 23 and 24).

Immunohistochemical examination: Immunohistochemistry

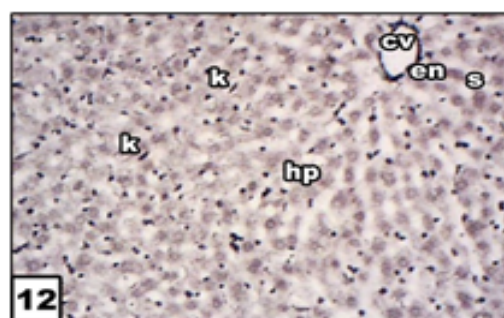


Figure 12: Liver section from 6 weeks CCl₄ treated with propolis showing normal liver lobular architecture with well brought out central vein and prominent nucleus and nucleolus.

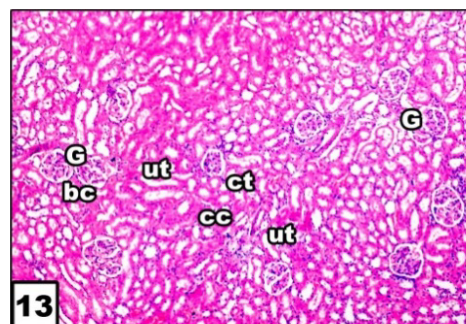


Figure 13: Photomicrograph of a T.S in kidney section of control untreated rat displaying the normal structure of the glomerulus (G), Boman's capsule (bc), uriniferous tubules (ut),collecting tubules (ct) and cubical cells. (H.E.400X).

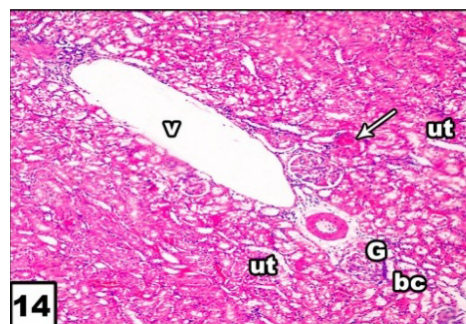


Figure 14: After 6 weeks ccl₄ of treated rat showing clear vacuolation of cells, cubical cell become vacuolated and toxicity with congested blood vessels is present (arrow).

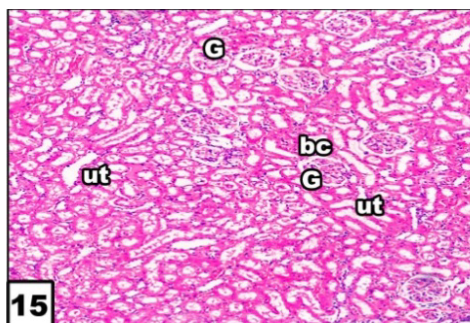


Figure 15: After 6 weeks ccl₄ treated with honey bee showing normal morphology and architecture of kidney, only bands lining uriniferous tubules.

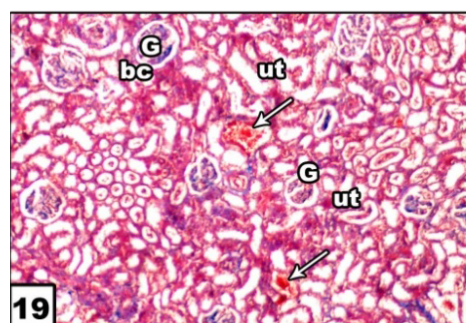


Figure 19: After 6 weeks CCl₄ treated with honey bee showing normal morphology with exception of only few congested blood vessel of tubules (arrow).

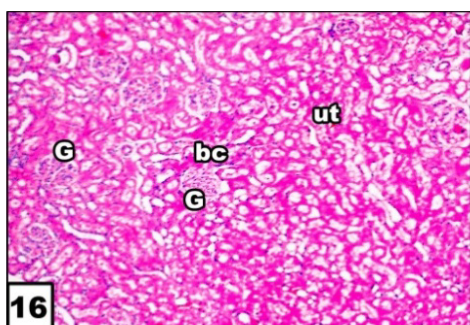


Figure 16: After 6 weeks treated with CCl₄ and propolis showing improvement of general kidney architecture.

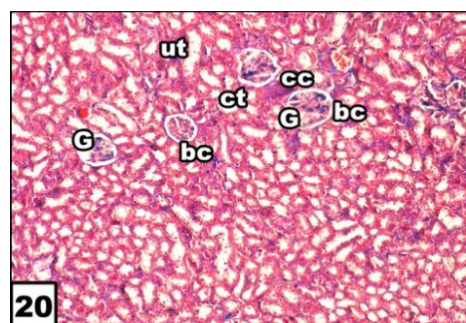


Figure 20: After 6 weeks CCl₄ treated with propolis showing regeneration in glomeruli and interstitial spaces nearly as seen in control group.

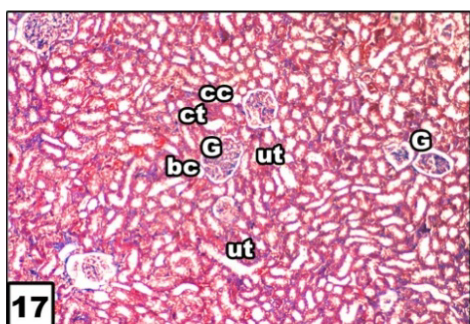


Figure 17: Kidney section of control untreated rat displaying the normal structure of renal architecture. (Masson Trichrome.400X).

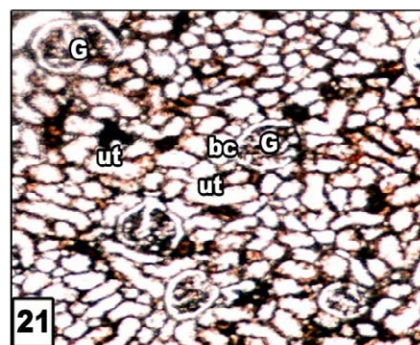


Figure 21: Photomicrograph of a T.S in kidney section of control untreated rat showing stained reticular fibers displaying the normal structure of the glomerulus (G) and bowman's capsule (bc). (Silver stain.400X).

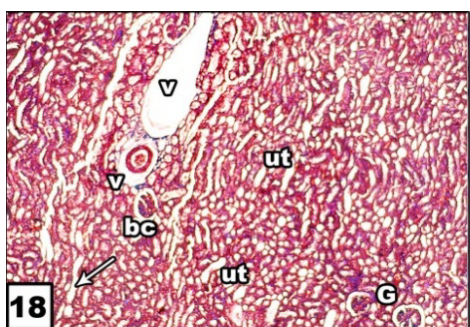


Figure 18: After 6 weeks CCl₄ of treated rat showing clear vacuolation of cells, dilation in space of Bowman's capsule and tubular infiltration (arrow).

of the control liver tissues stained with anti-laminin showed normal structure of the liver (Figure 25 a). In CCl₄ injected rats, hepatic tissues stained with anti-laminin showed extensive hepatocellular necrosis (Figure 25 b).

The pathology of hepatic tissues stained with anti-laminin in CCl₄ injected rats and treated with honey showed improvement of general hepatic architecture and slight hepatocellular fibrosis (Figure 25 c).

The pathology of hepatic tissues stained with anti-laminin in CCl₄ injected rats and treated with propolis showed normal liver lobular architecture with slight hepatocellular fibrosis (Figure 25 d).

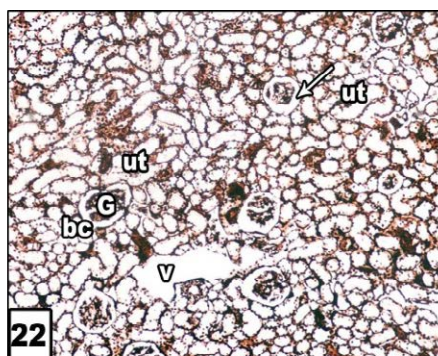


Figure 22: After 6 weeks CCl₄ of treated rat showing presence of clear vacuoles of cells and dilation in space of bowman's capsule (arrow).

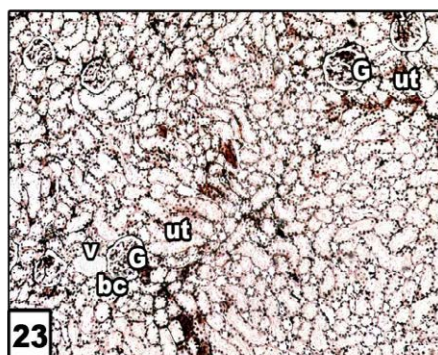


Figure 23: After 6 weeks CCl₄ treated with honey bee showing normal morphology with exception of only small vacuoles.

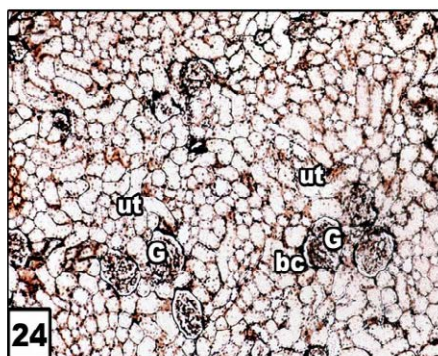


Figure 24: After 6 weeks CCl₄ treated with propolis showing almost normal morphology and architecture of kidney, glomeruli and tubules appeared to be regenerated.

Discussion

The present study showed that, CCl₄ administration for six weeks, resulted in loss of the usual hepatic architecture, many vacuoles with dark stained nuclei in most of the liver cells. This structural damage was due to edema of the organelles [33].

Liver fibrosis was clearly evidenced, in the present work, by a significant increase in area percentage of the collagen fibers in Masson trichrome stained section. It was explained that hepatic fibrosis is usually initiated by hepatocytes damage leading to activation of Kupffer cells

and subsequent release of cytokines and growth factors. These factors activate HSCs which proliferate and transform into myofibroblasts-like cells that deposit large amounts of connective tissue components [34]. Moreover, CCl₄ causes oxidative stress that activates HSCs [35].

One of the structural glycoproteins is a high molecular weight molecule called laminin [31]. It is well known from previous immunohistochemical studies that laminin and type IV collagen are permanent constituents of the basement membrane of late and early chorionic villi and of placental blood vessels [36-38]. It has also been reported that basement membrane components such as type IV collagen and laminin can be synthesized by trophoblastic cells [39]. The basement membranes may control selective permeability for macromolecules as well as providing structural tissue support. Laminin, which binds to itself, to type IV collagen, to heparin, and to cell surface receptors, is able to promote the adhesion and growth of various epithelial cells and tumour cells [40,41], as well as the outgrowth of neurites [42]. The interactions of cells with various tissue matrices may result in quite different cellular responses, and modification of the extra cellular matrix structure is likely to play an important role in the regulation of cell behaviour during developmental processes laminin might be an essential constituent of placental basement membranes and might play an important role in the function and structure of the villi. In addition, significantly enhanced laminin expression in the basement membrane beneath the trophoblastic epithelium might modulate the characteristics of the trophoblastic cells in hydatidiform moles in an autocrine and/or paracrine fashion. Serum laminin P-1 concentrations are reported to be high in patients with fibrosis of the liver, e.g. chronic hepatitis, liver cirrhosis, alcoholic liver disease [43-45], various malignant tumours [46-49], and pregnancy. In the case of liver fibrosis, increased deposition of basement membrane components, such as type IV collagen and laminin, in the peri-sinusoidal walls of the liver has been reported [50-53]. In the case of malignancy, [50] reported that serum laminin P-1 values were increased in ~50% of cancer patients. This increase may be due to the destruction of the basement membrane by tumour invasion and increased synthesis of fibrous components surrounding the tumour.

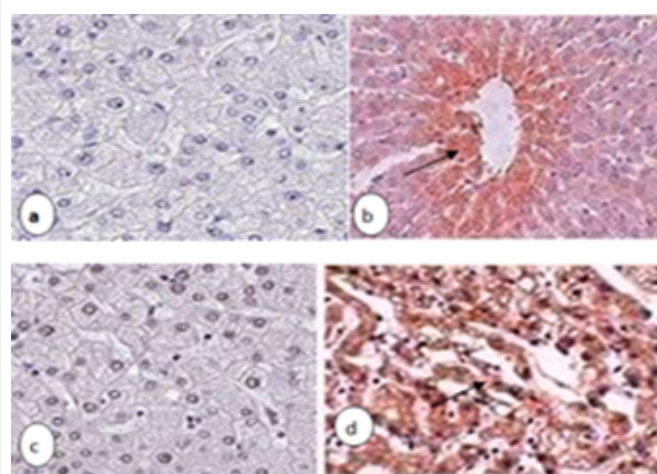


Figure 25: Anti-laminin immunostaining of liver section. (a) Control rats showed normal tissue and no positive stain. (b) CCl₄ injected rats, showed strong positive stain of laminin (arrow) (c) CCl₄ and treated with honey showed no positive laminin. (d) CCl₄ injected rats and treated with propolis showed weak positive laminin (arrow0... .stain.munoperoxidase×250).

References

- Basu S (2003) Carbon tetrachloride-induced lipid peroxidation: eicosanoid formation and their regulation by antioxidant nutrients. *Toxicology* 189: 113-127.
- Lee GP, Jeong WI, Jeong DH, Do SH, Kim TH, et al. (2005) Diagnostic evaluation of carbon tetrachloride-induced rat hepatic cirrhosis model. *Anticancer Res* 25: 1029-1038.
- Hegazi AG, Abd El Hady, EL Menway, Al Mehdar H (2004) "Egyptian propolis : 5 influence of propolis administration on some chicken biochemical parameters". *applied veterinary science NRC* 1: 43-58.
- Nasir GA, Mohsin S, Khan M, Shams S, Ali G, et al. (2013) Mesenchymal stem cells and Interleukin-6 attenuate liver fibrosis in mice. *J Transl Med* 11: 78.
- Valente MJ (2011) Biological activities of Portuguese propolis: protection against free radical- induced erythrocyte damage and inhibition of human renal cancer cell growth in vitro. *Food and Chemical Toxicology*, 49: 86-92
- Nirala SK, Bhadauria M (2008) Propolis reverses acetaminophen induced acute hepatorenal alterations: a biochemical and histopathological approach. *Arch Pharm Res* 31: 451-461.
- Yousef MI, Esmail AM, Baghdadi HH (2004) Effect of isoflavones on reproductive performance, testosterone levels, lipid peroxidation, and seminal plasma biochemistry of male rabbits. *J Environ Sci Health B* 39: 819-833.
- Bobis S, Jarocha D, Majka M (2006) Mesenchymal stem cells: characteristics and clinical applications. *Folia Histochem Cytobiol* 44: 215-230.
- Zickri MB, Ahmad NA, Maadawi ZM, Mohamady YK, Metwally HG (2012) Effect of stem cell therapy on induced diabetic keratopathy in albino rat. *Int J Stem Cells* 5: 57-64.
- Kruse PF, Patterson MK (1973) *Tissue culture: methods and applications*, Academic Press, New York.
- Sun H, Yu L, Wei H, Liu G (2012) A novel antihepatitis drug, bicyclol, prevents liver carcinogenesis in diethylnitrosamine-initiated and phenobarbital-promoted mice tumor model. *J Biomed Biotechnol* 2012: 584728.
- An J, Beauchemin N, Albanese J, Abney TO, Sullivan AK (1997) Use of a rat cDNA probe specific for the Y chromosome to detect male-derived cells. *J Androl* 18: 289-293.
- Geerts AM, Vanheule E, Praet M, Van Vlierberghe H, De Vos M, et al. (2008) Comparison of three research models of portal hypertension in mice: macroscopic, histological and portal pressure evaluation. *Int J Exp Pathol* 89: 251-263.
- Fu X, Li H (2009) Mesenchymal stem cells and skin wound repair and regeneration: possibilities and questions. *Cell Tissue Res* 335: 317-321.
- Mahdy KA, Morsy FA (2001) Hepatoprotective effects of honey on experimental liver injuries induced by some food additives. *J Egypt So Toxicol* 25: 37-46.
- Mato I, Huidobro JF, Simal-Lozano J, Sancho MT (2003) Significance of nonaromatic organic acids in honey. *J Food Prot* 66: 2371-2376.
- Molan PC (2002) Revival of honey as a medicine. *Honeybee Sci* 23: 153-160.
- Aljadi AM, Kamaruddin MY (2004) Evaluation of the phenolic contents and antioxidants capacities of two Malaysian floral honeys. *Food Chem* 85: 513-518.
- Mabrouk GM, Zohny SF, Ali EM, Ismail EF, Moselhy SS (2004) Bee honey and *Nigella sativa* inhibit nitric oxide mediated cytochrome C release and down-regulation of connexin 43 induced by methyl nitrosourea in hepatic tissues of sprague dawley rats. *Egypt J Biochem* 22: 73-87.
- Andritoin calin vasile, Lacramioara ochiuz, Vasile Andritoin ,Marcel Popa (2014) Effect of Apitherapy formulations against carbon tetrachloride-induced toxicity wistar rats after three weeks of treatment. *molecules* 19:13374-13391.
- Orsolić N, Basić I (2005) Antitumor, hematostimulative and radioprotective action of water-soluble derivative of propolis (WSDP). *Biomed Pharmacother* 59: 561-570.
- Drury RA and Walligton EA (1980) *Carlton's Histopathological Techniques*. (5th Edn) Oxford University press, Oxford, New York, Toronto.
- Carson FL (1990) *Histotechnology. A self-instructional text*, ASCP Press, Chicago.
- Rabilloud T, Vuillard L, Gilly C, Lawrence JJ (1994) Silver-staining of proteins in polyacrylamide gels: a general overview. *Cell Mol Biol (Noisy-le-grand)* 40: 57-75.
- Hochstrasser DF, Patchornik A, Merrill CR (1988) Development of polyacrylamide gels that improve the separation of proteins and their detection by silver staining. *Anal Biochem* 173: 412-423.
- Rabilloud T (1992) A comparison between low background silver diammine and silver nitrate protein stains. *Electrophoresis* 13: 429-439.
- Rabilloud T (1990) Mechanisms of protein silver staining in polyacrylamide gels: a 10-year synthesis. *Electrophoresis* 11: 785-794.
- Yan JX, Wait R, Berkelman T, Harry RA, Westbrook JA, et al. (2000) A modified silver staining protocol for visualization of proteins compatible with matrix-assisted laser desorption/ionization and electrospray ionization-mass spectrometry. *Electrophoresis* 21: 3666-3672.
- Sinha P (2001) A new silver staining apparatus and procedure for matrix-assisted laser desorption/ionization-time of flight analysis of proteins after two-dimensional electrophoresis. *Proteomics* 1: 835-840.
- Blum H (1987) Improved silver staining of plant proteins, RNA and DNA in polyacrylamide gels. *Electrophoresis* 8: 93-99.
- Rabilloud T, Carpentier G, Tarroux P (1988) Improvement and simplification of low-background silver staining of proteins by using sodium dithionite. *Electrophoresis* 9: 288-291.
- Gharahdaghi F, Weinberg CR, Meagher DA, Imai BS, Mische SM (1999) Mass spectrometric identification of proteins from silver-stained polyacrylamide gel: a method for the removal of silver ions to enhance sensitivity. *Electrophoresis* 20: 601-605.
- Timpl R, Rohde H, Robey PG, Rennard SI, Foidart JM, et al. (1979) Laminin--a glycoprotein from basement membranes. *J Biol Chem* 254: 9933-9937.
- Filipec Kanizaj T, Kunac N (2015) Hepatitis C: New challenges in liver transplantation. *World J Gastroenterol* 21: 5768-5777.
- Tasci I, Mas N, Mas MR, Tuncer M, Comert B (2008) Ultrastructural changes in hepatocytes after taurine treatment in CCl₄ induced liver injury. *World J Gastroenterol* 14: 4897-4902.
- Yang FR, Fang BW, Lou JS (2010) Effects of Haobie Yangyin Ruanjian decoction on hepatic fibrosis induced by carbon tetrachloride in rats. *World J Gastroenterol* 16: 1458-1464.
- Blankenship TN, Enders AC, King BF (1992) Distribution of laminin, type IV collagen, and fibronectin in the cell columns and trophoblastic shell of early macaque placentas. *Cell Tissue Res* 270: 241-248.
- Blankenship TN, King BF (1993) Developmental changes in the cell columns and trophoblastic shell of the macaque placenta: an immunohistochemical study localizing type IV collagen, laminin, fibronectin and cytokeratins. *Cell Tissue Res* 274: 457-466.
- Nanaev AK, Milovanov AP, Domogatsky SP (1993) Immunohistochemical localization of extracellular matrix in perivillous fibrinoid of normal human term placenta. *Histochemistry* 100: 341-346.
- Autio-Harmainen H, Sandberg M, Pihlajaniemi T, Vuorio E (1991) Synthesis of laminin and type IV collagen by trophoblastic cells and fibroblastic stromal cells in the early human placenta. *Lab Invest* 64: 483-491.
- Kleinman HK, Cannon FB, Laurie GW, Hassell JR, Aumailley M, et al. (1985) Biological activities of laminin. *J Cell Biochem* 27: 317-325.
- Martin GR, Timpl R (1987) Laminin and other basement membrane components. *Annu Rev Cell Biol* 3: 57-85.
- Baron-Van Evercooren A, Kleinman HK, Ohno S, Marangos P, Schwartz JP, et al. (1982) Nerve growth factor, laminin, and fibronectin promote neurite growth in human fetal sensory ganglia cultures. *J Neurosci Res* 8: 179-193.
- Niemelä O, Risteli L, Sotaniemi EA, Risteli J (1985) Type IV collagen and laminin-related antigens in human serum in alcoholic liver disease. *Eur J Clin Invest* 15: 132-137.
- Niemelä O, Risteli J, Blake JE, Risteli L, Compton KV, et al. (1990) Markers of fibrogenesis and basement membrane formation in alcoholic liver disease. Relation to severity, presence of hepatitis, and alcohol intake. *Gastroenterology* 98: 1612-1619.
- Gressner AM, Tittor W (1986) Serum laminin--its concentration increases with portal hypertension in cirrhotic liver disease. *Klin Wochenschr* 64: 1240-1248.

47. Schneider M, Voss B, Högemann B, Eberhardt G, Gerlach U (1989) Evaluation of serum laminin P1, procollagen-III peptides, and N-acetyl-beta-glucosaminidase for monitoring the activity of liver fibrosis. *Hepatogastroenterology* 36: 506-510.
48. Collazos J, Díaz F, Genollá J (1993) Serum concentrations of laminin in cirrhosis of the liver. *Gut* 34: 974-976.
49. Kropf J, Gressner AM, Tittor W (1991) Logistic-regression model for assessing portal hypertension by measuring hyaluronic acid (hyaluronan) and laminin in serum. *Clin Chem* 37: 30-35.
50. Brocks DG, Strecker H, Neubauer HP, Timpl R (1986) Radioimmunoassay of laminin in serum and its application to cancer patients. *Clin Chem* 32: 787-791.
51. Schaffner F, Poper H (1963) Capillarization of hepatic sinusoids in man. *Gastroenterology* 44: 239-242.
52. Popper H, Uenfriend S (1970) Hepatic fibrosis. Correlation of biochemical and morphologic investigations. *Am J Med* 49: 707-721.
53. Hahn E, Wick G, Pencev D, Timpl R (1980) Distribution of basement membrane proteins in normal and fibrotic human liver: collagen type IV, laminin, and fibronectin. *Gut* 21: 63-71.