

Incus Morphometry: A Possible Tool in Sex Determination

Kamal Singh*, Aarti Rohilla and Jyoti Rohila

Department of Anatomy, Pt. B. D. Sharma Post Graduate Institute of Medical Sciences, Rohtak-124001, Haryana, India

*Corresponding author: Dr. Kamal Singh, Assistant Professor, Department of Anatomy, 18/CH, Medical Campus, Pt. B. D. Sharma PGIMS, Rohtak-124001, Haryana, India, Tel: +91-9812531007; E-mail: drkamalanatomy@gmail.com

Received date: September 18, 2015; Accepted date: April 21, 2016; Published date: April 25, 2016

Copyright: © 2016 Kamal S, et al. This is an open-access article distributed under the terms of the Creative Commons Attribution License, which permits unrestricted use, distribution, and reproduction in any medium, provided the original author and source are credited.

Abstract

The adult human skeleton is sexed using morphological and metrical traits of big intact bones like skull, mandible, pelvis and long bones etc. The Incus is housed in the middle ear; so it remains well protected even in the mutilated bodies. Morphometry of the 120 human Incus bones from 60 cadavers have been studied with the aim to know the sexual dimorphism in north Indian population. It is observed that study of normal dimensions and indices will provide insight for the surgeons and will have surgical implications in reconstruction of ossicular chain, which may have been congenitally absent, malformed, fixed, disrupted or destroyed by trauma or disease. These are the results for guidance and future manipulation in the field of ENT and Forensic Medicine.

Keywords: Ear ossicles; Incus; Indices; Ossiculoplasty; Middle ear cavity; Prosthesis

Introduction

The ossicles (malleus, incus and stapes) are the smallest bones in the human body and are structurally and functionally most complicated. They do not have periosteum and cannot be regenerated. They are in the form of ossicular chain across the tympanic cavity from the tympanic membrane (lateral wall) of middle ear to the fenestra vestibule (oval window) in the medial wall of middle ear. The malleus and incus are derived from Meckel's cartilage and ossification begins in the fourth month of intrauterine life and is completed by the eighth month while, stapes is derived from Reichert's cartilage reaches an advanced state of maturity at birth [1,2]. Determination of sex in the inadequate skeletal remains of the bodies is a challenging task even for experienced forensic experts. Sex determination is the first essential step in medicolegal autopsies for positive identification more so in an unidentified decomposed/mutilated body [3]. Many a time, even the most skilled expert is filled with trepidation while deciding the sex in inadequate remains of a body. The ear ossicles remain protected in the petrous part of the temporal bone and can be retrieved from the remnants of even severely mutilated bodies.

Although the dissection of cadaveric temporal bone is a must for trainee otolaryngologists, however, forensic experts remain oblivious to ear ossicles as the review of literature revealed no study to utilize the morphometry of incus for sex determination. The incus is the 2nd largest among ossicles which comprises of Body, Short Limb, Long Limb with Lenticular Process, and a facet for articulation with head of Malleus. The body forms the large ovoid part of the bone. It articulates anteriorly with Malleus as a saddle-shaped articulation and posteriorly with Stapes as a ball and socket articulation. Studies on embryogenesis of the hearing [4-6] have shown that the ear differs from one individual to another with a saying that "No two ears are the same" [7]. The malformations like synostosis between malleus and incus [8], absence of incus [9-13] and malformations of incudostapedial joint [14-16] may also be associated with malformation of the external ear.

In the present study we attempt to evaluate the applicability of Incus Morphometric indices as a potential tool for determination of sex.

Material and Method

The study was conducted on sixty unidentified cadavers ("Unidentified" means that the cadaver is not belonging to any person or family) in different stages of decomposition during medicolegal postmortem examination. The ossicles were procured manually after dissection of the petrous part of temporal bone by using *Cobbler's Cut Method* [17] and 120, Incus bones were retrieved as the Ossicles attains the stage of maturity within the 4th-5th Month of Intrauterine life [2]. So, it does not imply any advantage to classify them as Young, Middle and Older Adult. So, the following parameters of cleaned and dried bones were studied from selected points as depicted in the diagrams (Figure 1).

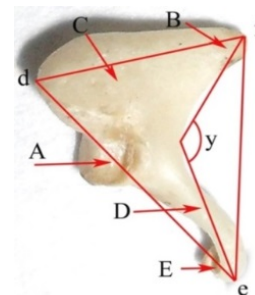


Figure 1: Cleaned and dried temporal bone. Total length (d-e) mm: Maximal distance between the superior edge of the body and the end of the long process. Total width (d-f) mm: Maximal distance between the superior edge of the body and the end of the short process. Maximal distance top of the processes (e-f) mm: Maximal distance between the tips of the processes. Angle (y): Angle between the processes. Index: Total width × 100/total length of incus. Weight of Incus (mg).

These Morphometric parameters were measured by the digital vernier caliper with the least count of 0.01 mm. The weights of the bones were measured by the electronic micro-balance of ‘Sartorius CP224S’ model with the minimal readability of 0.1 mg.

The angles were measured with the standard ruler and protractor on the photographs of the ossicles taken by fugifilm 10.0 megapixel camera with 5x optical zoom.

The bones and camera were fixed in same position, distance, and orientation with respect to each other for each measurement. All the measurements were taken by one setup. Each reading was taken thrice and a mean of all three was taken to rule out any error.

The results of the study were computed and analyzed with SPSS software. Normal descriptive statistics i.e., means, standard deviation & P-Value as well as Canonical discriminant function coefficients in discriminant function analyses were performed. The discriminant function formula is as follows:

$$F(X) = A1X1 + A2X2 + \dots + ANXN + C$$

Where F(X) represents the discriminant function score, X1 to XN are the measured variables, A1 to AN are the unstandardized coefficients of each variable and C is the function’s constant. The

sectioning point (Z0) for each Discriminant function is calculated from the weighted mean of values at the group centroids for males and females using the formula provided by Xavier [18].

$$Z0 = [(Zm \times Nf) + (Zf \times Nm)] / (Nm + Nf)$$

Where Zm and Zf are the group centroids for male and female groups, Nm and Nf being the number of Incus bones of males and females respectively. Any value above the sectioning point will be classified as male and the values below the sectioning point will be classified as female.

Observations and Results

Descriptive statistics of both the sexes for Left & Right sides of Incus Bone were analyzed and compared respectively (Tables 1 and 2). We observed no statistical significance on comparison of morphometric parameters of incus of both the sexes for left & right side respectively. But, Discriminant Function Analysis of the different parameters of incus showed that these parameters provides us a good criteria in determining the group Centroids and significance of percentage accuracy in determination of sex (Tables 3-6).

Sr. No.	Morphometric Parameter	Male Left Side Mean ± SD	Female Left Side Mean ± SD	P-Value
1	Total Length (mm)	6.682 ± 0.498	6.666 ± 0.334	0.88
2	Total Width (mm)	5.112 ± 0.396	4.942 ± 0.281	0.061
3	Maximal distance between Top of Processes (mm)	5.985 ± 0.447	6.031 ± 0.313	0.646
4	Angle (y0)	75.000 ± 8.878	72.800 ± 8.198	0.323
5	Index	76.714 ± 6.176	74.270 ± 4.717	0.09
6	Weight (mg)	26.833 ± 4.539	25.857 ± 2.654	0.313

Table 1: Descriptive statistics of the left Incus bone measurements.

Sr. No.	Morphometric Parameter	Male Right Side Mean ± SD	Female Right Side Mean ± SD	P-Value
1	Total Length (mm)	6.691 ± 0.419	6.656 ± 0.330	0.718
2	Total Width (mm)	5.104 ± 0.394	5.013 ± 0.279	0.303
3	Maximal distance between Top of Processes (mm)	6.039 ± 0.459	5.993 ± 0.290	0.647
4	Angle (y0)	74.500 ± 8.982	75.067 ± 7.492	0.792
5	Index	76.429 ± 5.828	75.445 ± 4.810	0.479
6	Weight (mg)	26.747 ± 4.615	25.777 ± 3.053	0.341

Table 2: Descriptive statistics of the right incus bone measurements.

On applying DFA on the individual parameters for the left side has produced a sex determination accuracy of 66.7% in males with maximal distance top of the process, and 66.7% in females with weight of the left incus bone.

Whereas a 60% accuracy for sex determination was being observed with total width for males, females & both (Table 3).

On applying DFA on the individual parameters for the right side has produced a sex determination accuracy of 60% in males with total width, and 56.7% in females with total length & weight of the right incus bone.

Whereas a 56.7% accuracy for sex determination was being observed with total width for males, females & both (Table 4).

Sr. No	Parameters	Unstandardized Coefficients	DF's Constant	Wilk's Lambda	Group Centroids		Correctly Assigned		
					M	F	M	F	T
A	Total length (d-e) mm	2.358	-15.736	1	0.02	-0.02	16.70%	43.30%	30%
B	Total width (d-f) mm	2.911	-14.636	0.941	0.247	-0.247	60%	60%	60%
C	Maximal distance top of the processes (e-f) mm	2.589	-15.557	0.996	0.06	-0.06	66.70%	50%	58.30%
D	Angle (y0)	0.117	-8.649	0.983	0.129	-0.129	60%	43.30%	51.70%
E	Index	0.182	-13.738	0.951	0.222	-0.222	50%	60%	55%
F	Weight	0.269	-7.085	0.982	0.131	-0.131	53.30%	66.70%	60%

Table 3: Discriminant function analysis showing % accuracy for sex determination by taking individual parameters of left incus.

Sr. No.	Parameters	Unstandardized Coefficients	DF's Constant	Wilk's Lambda	Group Centroids		Correctly Assigned		
					M	F	M	F	T
A	Total length (d-e) mm	2.653	-17.703	0.998	0.047	-0.047	50%	56.70%	53.30%
B	Total width (d-f) mm	2.929	-14.818	0.982	0.134	-0.134	60%	53.30%	56.70%
C	Maximal distance top of the processes (e-f) mm	2.604	-15.663	0.996	0.059	-0.059	43.30%	46.70%	45%
D	Angle (y0)	0.121	-9.042	0.999	-0.034	0.034	36.70%	43.30%	40%
E	Index	0.187	-14.212	0.991	0.092	-0.092	46.70%	46.70%	46.70%
F	Weight	0.256	-6.712	0.984	0.124	-0.124	43.30%	56.70%	50%

Table 4: Discriminant function analysis showing % accuracy for sex determination by taking individual parameters of right incus.

On applying DFA on the different combination of parameters for the left side it is observed that has produced a sex determination with maximum accuracy of 53.3% can be carried out by taking parameters in serial no. 5 of Table 5 in males. Whereas a maximum of 66.7% can be accurately classified by using serial no. 3, 4, 5 and 6 (Table 5).

A total of 60% accuracy for sex can be defined for sex determination while taking serial no. 5 alone implying that length, width, maximal distance & weight can best classify the left incus as male or female.

On applying DFA on the different combination of parameters for the right side it is observed that has produced a sex determination with maximum accuracy of 53.3% can be carried out by taking parameters in serial no. 8 of Table 6 in males; whereas a maximum of 56.7% can be accurately classified by using serial no. 1 & 8 (Table 6). A total of 55% accuracy for sex can be defined for sex determination while taking serial no. 8 alone implying that width & weight could be the best parameter for determination of sex of an individual by using right incus bone.

Sr. No.	Parameters	Unstandardized Coefficients	DF's Constant	Wilk's Lambda	P-Value	Group Centroids		Correctly Assigned		
						M	F	M	F	T
1	D+F (Angle + Weight)	0.080 0.188	-10.838	0.968	0.393	0.179	-0.179	40%	56.70%	48.30%
2	A+C (Length + Maximum Distance)	-2.328 3.235	-3.902	0.991	0.772	-0.094	0.094	46.70%	46.70%	46.70%
3	A+F (Length + Weight)	-1.986 0.372	3.461	0.973	0.453	0.165	-0.165	50%	66.70%	58.30%
4	A+B+C+D+F (Length + Width + Maximum)	-0.336 2.035	-4.25	0.877	0.199	0.369	-0.369	50%	66.70%	58.30%

	Distance + Angle + Weight)	-2.113 0.058 0.176								
5	A+B+C+F (Length + Width + Maximum Distance + Weight)	-0.784 2.322 -1.730 0.196	-1.213	0.901	0.211	0.326	-0.326	53.30%	66.70%	60%
6	A+B+C (Length + Width + Maximum Distance)	0.024 2.983 -1.368	-6.942	0.923	0.208	0.285	-0.285	46.70%	66.70%	56.70%
7	A+B (Length + Width)	-0.782 3.136	-10.545	0.935	0.147	0.26	-0.26	53.30%	50%	51.70%
8	B+F (Width + Weight)	2.698 0.042	-14.682	0.939	0.169	0.25	-0.25	53.30%	60%	56.70%

Table 5: Discriminant function analysis showing % accuracy for sex determination by taking different combinations of parameters of left incus.

Sr. No.	Parameters	Unstandardized Coefficients	DF's Constant	Wilk's Lambda	P-Value	Group Centroids		Correctly Assigned		
						M	F	M	F	T
1	D+F (Angle + Weight)	-0.039+ 0.247	-3.561	0.983	0.606	0.131	-0.131	43.30 %	56.70 %	50%
2	A+C (Length + Maximum Distance)	0.924+ 2.012	-18.266	0.996	0.892	0.062	-0.062	33.30 %	36.70 %	35%
3	A+F (Length + Weight)	-1.257+ 0.319	0.008	0.982	0.598	0.133	-0.133	46.70 %	50%	48.30 %
4	A+B+C+D+F (Length + Width + Maximum Distance + Angle + Weight)	-1.624+ 0.169+ 1.088+ 1.972+ -0.046	-6.698	0.967	0.869	0.181	-0.181	40%	46.70 %	43.30 %
5	A+B+C+F (Length + Width + Maximum Distance + Weight)	-1.537+ 0.187+ 0.663+ 1.998	-8.742	0.971	0.799	0.17	-0.17	46.70 %	43.30 %	45%
6	A+B+C (Length + Width + Maximum Distance)	-0.661+ 2.839+ 1.166	-16.971	0.979	0.749	0.145	-0.145	46.70 %	50%	48.30 %
7	A+B (Length + Width)	0.003+ 2.928	-14.832	0.982	0.591	0.134	-0.134	36.70 %	53.30 %	45%
8	B+F (Width + Weight)	1.913+ 0.139	-13.333	0.976	0.496	0.155	-0.155	53.30 %	56.70 %	55%

Table 6: Discriminant function analysis showing % accuracy for Sex Determination by taking different combinations of parameters of right incus.

Discussion

Morphometric analysis of ear ossicles had been the subject of interest since the mid fifteenth century [8] and earlier researchers have observed insignificant variations in the morphology of incus not only in both the sexes but also on both sides. Studies on embryogenesis of the hearing [19] have shown that the ear differs from one individual to another with a saying that “No two ears are the same” [20]. The review of Indian as well as international literature revealed that morphometry of ossicles has been studied by many investigators more so in males [21-23].

This study represents an endeavour by the investigators to provide a comprehensive coverage of measurement of the various parameters of the incus. The literature, so far as available, is remarkably devoid of extensive observations even on the gross anatomy of the ossicles. Earlier studies by Natekar et al. reveal various morphometric measurements of malleus and incus [24].

Auditory ossicles specially regarding incus was under consideration for study by a group of research workers. Even though the total length

of incus, total width and angle of incus was studied widely only a few have studied the maximum distance between tip of process [8,11,12,24-28].

The study of index of incus was carried out in three different population Natufian, En Gedi and Recent India [8,26]. The incus weight was exclusively done and reported by Harneja and Chaturvedi; Natekar and De Souza [23,24].

These reported studies from Indian and other research workers throughout the world have studied the parameters of the ear ossicles particularly in males [26,29-32]. The various morphometric results of bisexual and bilateral values of incus were compared with previous researchers are shown in Table 7.

Although results of Morphometric analyses did not reveal a statistically significant level of sexual dimorphism, but on Discriminant functional analysis it is found that Incus bone can be used a tool for determination of sex with maximum accuracy up to 66.7%.

Sr. No.	Authors	Morphometric Parameters of Incus									
		Total (mm)	Length	Total (mm)	Width	Maximal distance between Tips of Processes (mm)	Angle (y0)	Index	Weight (mg)		
1	Present Data (2010)	6.674		5.043		6.01	74.342	75.714	26.303		
2	Natekar & De Souza (2006)	6.52		5.06		5.86			20.74		
3	Unur, Ulger, Ekinci (2002)	6.5		4.9		6.1	100				
4	Siori et al (1995)										
	Gebelen/Asiut*	6.49		4.89		6.02					
	Antinoe*	6.78		5.14		6.15					
5	Unur et al (1993)	6.7		5.1		6.1	99				
6	Arrensburg et al. (1981)										
	Natufian*	6.5		5.1			95	79.7			
	Roman (En Gedi)*	6.6		5.3			95	79.6			
	Recent India*	6.4		5.1			88	80.1			
7	Harneja & Chaturvedi (1973)								25.06		
8	Angel (1972)	6.8		4.9							
9	Arrensburg & Nathan (1972)	6.8		5.1			94				
10	Harada (1972)	6.8		4.8		4.2					
11	Bouchet & Giraut (1968)	6.5		5.1			95				
12	Masali (1968)	6.4		4.8							
13	Heron (1923)			5.2			76				

Table 7: Comparison of Morphometric data of incus from present study and some previous studies.

Conclusion

The findings in our study revealed subtle sex differences by accuracy and suggested that the assumptions of previous investigators in this regard need to be reassessed. Thus, this study may turn out to be a potential source of forensic investigation for evaluation of sex in severely mutilated and decomposed bodies during postmortem examination. The dimensions of the incus will provide insight to the otolaryngologist surgeons for implications in reconstruction of ossicular chain to regain the original mechanics. This study will also give a basis for teaching the medical students about the basic and detailed structure of the ear (external, middle, internal) as well as its related significance in Clinical Medicine, ENT and Forensic Science.

References

1. Krogman WM (1962) The Human Skeleton In Forensic Medicine. Charles C Thomas, Springfield, Illinois, USA.
2. Berkovitz BKB (2005) External and middle ear. In: Standring S (ed.) Gray's Anatomy: The anatomical basis of clinical practice. Edinburg: Churchill livingstone Elsevier pp: 649-661.
3. Kranioti EF, Michalodimitrakis M (2009) Sexual dimorphism of the humerus in contemporary Cretans: A population-specific study and a review of the literature. J Forensic Sci 54: 996-1000.
4. Lempert J, Wolff D (1945) Histopathology of incus and head of malleus in cases of stapedia ankylosis. Arch otolaryngol 42: 339-367.
5. Mawson SR, Ludman H (1979) Applied anatomy: The middle ear. In: Arnold E, editor. Disease of the ear. A text book of otology (4th edn.) Lavenham, Suffolk: The Lavenham Press Ltd pp: 34-36.
6. Doran A (1879) Morphology of the Mammalian Ossicula Auditiva. J Anat Physiol 13: 401-406.
7. Rodriguez-Vazquez JF (2005) Development of the stapes and associated structures in human embryos. J Anat 207: 165-173.
8. Arensburg B, Harell M, Nathan H (1981) The Human Middle Ear Ossicles: Morphometry and taxonomic implications. J Hum Evol 10: 199-205.
9. Urbantschitsch V (1876) Zur Anatomie der Gehörknöchelchen des Menschen. Archiv für Ohrenheilkunde 11: 1.
10. Heron IC (1923) Measurements and observations upon the human auditory ossicles. Am J of Phys Anthropol 6: 11-26.
11. Bouchet A, Giraud M (1968) Contribution a l'etude orphologique et radiologique des osselets de l'ouïe. Compte rendu de l' Association des Anatomistes 53 Congres 141: 588-600.
12. Masali M (1968) The Ear Bones and the Vertebral Column as Indications of Taxonomic and Postural Distinctions among Old World Primates with Reference to the Origin of Man. Torino: Rosenberg and Sellier.
13. Dass Ramji, Grewal BS, Thapar SP (1966) Human stapes and its variations. I. General Features. J Laryngol 80: 11-25.
14. Anson BJ, Karabin JE, Martin J (1939) Stapes, fistula ante fenestrum and associated structures in man. II. From the foetus at term to the adult of seventy years. Arch Otolaryngol 29: 939-973.
15. Beaton LE, Anson BJ (1940) Adult Form of the Human Stapes in the Light of its Development. Quart Bull Northwestern Univ Med School 14: 258-269.
16. De Vincentiis I, Cimino A (1957) Morphology, measurements and weight of the middle ear ossicles. Riv Biol 49: 181-204.
17. Singh K, Sirohiwal BL, Rohilla A, Chhabra S, Gupta G (2014) Cobbler's Cut: An Innovative Technique for Middle Ear Dissection. J Forensic Res 5: 222.
18. Xavier MJ (2004) A Practical Guide to Analyzing Survey data. Boston: Houghton Mifflin Company.
19. Anson BJ, Hanson JR, Richany SF (1960) Early embryology of the auditory ossicles and associated structures in relation to certain anomalies observed clinically. Ann Otol Rhinol Laryngol 69: 427-447.
20. Hough JVD (1963) Congenital malformations of the middle ear. Arch Otol Head Neck Surg 78: 335-343.
21. Aycan K, Unur E, Bozkir MG (1990) Anatomical study of malleus. J Health Sci 1: 152-158.
22. Unur E, Ulger H, Ekinci N (2002) Morphometrical and morphological variations of middle ear ossicles in the newborn. Erciyes Tip Dergisi (Erciyes Medical Journal) 24: 57-63.
23. Harneja NK, Chaturvedi RP (1973) A Study of the Human Ear Ossicles. Indian J Otol 25: 154-160.
24. Natekar PE, De Souza FM (2006) A morphometric study of malleus and incus and its clinical implications. Indian J Otol 12: 6-9.
25. Angel JL (1972) A Middle Palaeolithic temporal bone from Darra-I-Kur, Afghanistan. Translations of the American Philosophical Society 62: 54-56.
26. Moggi-Cecchi J, Collard M (2002) A fossil stapes from Sterkfontein, South Africa, and the hearing capabilities of early hominids. J Hum Evol 42: 259-265.
27. Unur E, Aycan K, Ekinci N (1993) The study of incus from morphometric view. Erciyes Medical J 15: 16-19.
28. Harada O, Ishii H (1972) The Condition of the auditory ossicles in microtia. Plast Reconst Surg 50: 48-53.
29. Rak Y, Clarke RJ (1979) Ear ossicle of Australopithecus robustus. Nature 279: 62-63.
30. Rak Y, Clarke RJ (1979) Aspects of the middle and external ear of early hominids. Am J Phys Anthropol 51: 471-474.
31. Sarrat R, Guzman G, Tores A (1988) Morphological variations of Human ossicula tympani. Acta Anat 131: 146-149.
32. Olszewski J (1989) Structure of middle ear in infants. Otolaryngol Pol 43: 278-283.