

Insidious Dropped Foot in a Young Adult

Balaji Krishnaiah¹, Vitaliy Zhivotenko¹, Mayur Chalia¹, Charles Specht² and Aiesha Ahmed^{1*}

¹Department of Neurology, Penn State Milton S. Hershey Medical Center, USA

²Department of Pathology, Penn State Milton S. Hershey Medical Center, USA

*Corresponding author: Aiesha Ahmed, Department of Neurology, Penn State Milton S. Hershey Medical Center, 30 Hope Drive, EC 037, Hershey, PA 17033, USA, Tel: +717-531-1377; Fax: 717-531-0384; E-mail: aahmed1@hmc.psu.edu

Rec date: Apr 02, 2016; Acc date: May 10, 2016; Pub date: May 20, 2016

Copyright: © 2016 Krishnaiah B et al. This is an open-access article distributed under the terms of the Creative Commons Attribution License, which permits unrestricted use, distribution, and reproduction in any medium, provided the original author and source are credited.

Abstract

Introduction: Intraneural perineurioma is a rare benign tumor composed of perineural cells. It typically affects teenagers and young adults and tends to present as a gradual onset motor predominant neuropathy. Pain and sensory disturbances are uncommon.

Methods: We discuss a case of sciatic perineurioma which was diagnosed with the help of multiple diagnostic modalities including electro diagnostic testing, imaging and biopsy.

Results: An electro diagnostic study was done which showed chronic severe left sciatic neuropathy with on-going denervation and MRI of the left lower extremity revealed enlargement and increase signal of the left sciatic nerve. A left sciatic nerve biopsy revealed intraneural perineurioma.

Conclusion: Intraneural perineurioma should be included in the differential diagnosis of focal neuropathy in a young adult. Imaging and electro diagnostic studies can be useful to indicate the likely presence of an intraneural neoplasm.

Keywords: Weakness; Atrophy; Denervation; Tumor

Introduction

Intraneural perineurioma is a rare benign tumor composed exclusively of whorls of perineurial cells surrounding nerve fibres with restriction to the boundaries of a peripheral nerve [1]. The Intraneural form was first described in 1964 as interstitial hypertrophic neuritis [2]. It typically affects teenagers and young adults with males and females being affected equally. Occurrence in young children below the age of ten is rare [1].

Median age of onset of neurological symptoms was 14 years (range 0.5–55 years) and median age at evaluation was 17 years (range 2–56 years). Intraneural perineurioma demonstrated EMA reactivity for the whorled formations whereas onion bulb formations demonstrated Schwann cell marker reactivity (S-100). Eventually this led to the nomenclature of 'pseudo-onion bulbs' when describing whorls of perineurial cells and 'onion bulbs' when describing whorls of Schwann cell processes.

Intraneural perineurioma can occur in both upper and lower limbs with mostly focal location. In approximately one-sixth of cases, more than one nerve was involved and they were plexus neuropathies. It tends to present as a gradual onset motor predominant neuropathy or plexopathy with mild sensory symptoms and signs. Pain and sensory disturbances are uncommon.

We discuss a case of sciatic perineurioma which was diagnosed with the help of multiple diagnostic modalities including electro diagnostic testing, imaging and biopsy.

Case Report

A 22 year old woman presented with insidious onset of progressive left foot drop since the age of 17. Initially she was occasionally tripping over objects on the floor; this progressed to the point where she required a brace for support. She has significant weakness of her left foot dorsiflexion and weight bearing on her left leg. She had intermittent stabbing pain in the lateral aspect of the thigh, shin and dorsum of the foot. There was no history of bowel or bladder incontinence. She did not describe any weakness or sensory changes in the right leg or in the bilateral upper extremities.

On examination, the pertinent motor exam findings for the left lower extremity (Medical Research Council [MRC] grading) are as follows: knee flexion 4/5, foot dorsiflexion 2/5, foot eversion and inversion 3/5, big toe extension 0/5. There was diffuse atrophy of the left lower extremity, calf worse than thigh. Sensory exam was variable and did not fit a dermatomal or sensory nerve distribution. Reflexes were absent at the left ankle. She had a high steppage gait and was able to stand on her toes but not her heels. Remainder of the neurological exam was unremarkable.

Clinical laboratory findings included normal or negative complete blood count, glucose, electrolytes, BUN, creatinine, AST, ALT, sedimentation rate, anti-nuclear antibody titer, vitamin B12 level, free T4, thyroid stimulating hormone, serum protein electrophoresis and serum immunofixation study.

An electrodiagnostic study was done. The results showed chronic severe left sciatic neuropathy with ongoing denervation; the nerve conduction results and needle examination is summarized in Tables 1 and 2 respectively.

Nerve	Nerve Distal (m/s)	Sensory Latency	Sensory Distal Amplitude (µV)	Motor Distal Latency (m/s)	Motor Distal Amplitude (mV)	Motor Conduction Velocity (m/s)	F Wave Latency (m/s)
Sural R.	3.9 (<4.2)		25.4 (>6.0)	-	-	-	-
Superficial Peroneal R.	3.6 (<4.4)		14.3 (>6.0)	-	-	-	-
Sural L.	NR		NR	-	-	-	-
Superficial Peroneal L	NR		NR	-	-	-	-
Peroneal R. †	-	-	-	3.8 (<6.1)	7.45 (>2.0)	45.1(>41.0)	45.1 (<56.0)
Tibial R.‡	-	-	-	3.5 (<6.1)	11.34 (>3.0)	42.2 (>41.0)	48.1 (<56.0)
Peroneal L.†	-	-	-	4.5 (<6.1)	2.23 (>2.0)	35.0 (>41.0)	57.0 (<56.0)
Peroneal (TA) L.	-	-	-	4.2	0.23 (>5.0)	31.7 (>44.0)	
Tibial L.‡	-	-	-	6.0 (<6.1)	2.38 (>3.0)	37.0 (>41.0)	56.9(<56.0)

NR = no response. Normal values are given in parentheses.
 †Stimulating ankle, recording extensor digitorum brevis muscle.
 ‡Stimulating ankle, recording abductor hallucis muscle.

Table 1: Nerve Conduction Studies.

Muscle	Insert Activity	Spontaneous Activity				Voluntary Activity				Max Activity	Vol.
		Fibs	+Waves	Fasc's	Other	Amp	Dur	Recruit	Polys		
Tibialis anterior.L	Incr	4+	4+	None	Myotonia	Incr 2+	Incr 3+	Decr 4+	None	Max.	
Gastrocnemius (Medial head).L	Incr	3+	3+	None	None	Incr 4+	Incr 4+	Decr 3+	None	Max.	
Vastus medialis.L	Normal	None	None	None	None	Normal	Normal	Normal	None	Max.	
Iliopsoas.L	Normal	None	None	None	None	Normal	Normal	Normal	None	Max.	
Tensor fasciae latae.L	Normal	None	None	None	None	Normal	Normal	Normal	None	Max.	
Biceps femoris (long head).L	Incr	4+	4+	None	CRDs	Incr 3+	Incr 3+	Decr 3+	None	Max.	

Table 2: Needle Examination; CRD: Complex Repetitive Discharges.

MRI of the left lower extremity (Figure 1) revealed enlargement and increase signal of the left sciatic nerve within the thigh and mild-moderate atrophy of the left semimembranosus, semitendinosus and biceps femoris muscles. She underwent a left sciatic nerve neurolysis with fascicular nerve biopsy which revealed intraneural perineurioma, WHO grade I (Figure 2).

Discussion

Intraneural perineurioma is a benign neoplastic proliferation of perineurial cells that is associated with abnormalities of the long arm of chromosome 22, mainly monosomy or deletion of the 22q11- q13.1 bands [3]. It typically occurs during adolescence and has no male or female predilection. For most patients, the presenting symptoms include painless mononeuropathy that is characterized by slowly

progressive muscle weakness in the affected muscle group. Muscle atrophy can also develop.

Various reports indicate that intraneural perineurioma represents between 1 and 5% of neural tumors, but it is probably under-diagnosed because of unfamiliarity with the condition and the invasiveness of nerve biopsy. There are no identified risk factors or causative factors for Perineurioma. Perineurioma most commonly involves the ulnar nerve (17%), followed by peroneal nerve (9%) and sciatic nerve (8%) [4,5]. Involvement of tibial nerve is much less common (4%).

The differential diagnosis for focal thickening of a peripheral nerve includes neurofibroma, schwannoma, traumatic neuroma, intraneural perineurioma and, less likely, Charcot-Marie-Tooth (CMT) disease or chronic inflammatory demyelinating polyneuropathy (CIDP). Macroscopically, a proliferation of perineurial cells causes fusiform expansion of the affected nerve. This occurs around single axons

within the affected nerve, giving rise to a microscopic appearance of pseudo-onion bulbs.

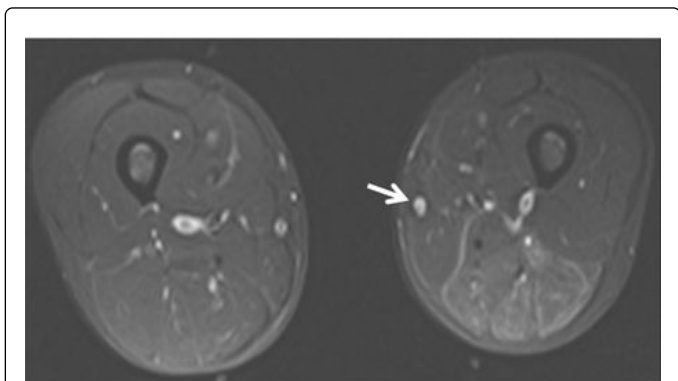


Figure 1: MRI of left thigh: Axial T2 weighted fat saturated image showing enlargement and increased signal of the left sciatic nerve at the level of the distal thigh. There is fatty atrophy of the left semimembranosus, semitendinosus, and biceps femoris muscle.

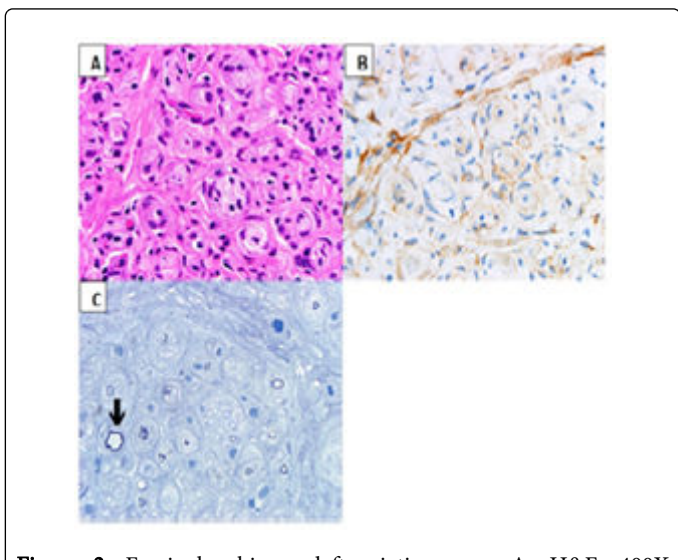


Figure 2: Fascicular biopsy left sciatic nerve. A- H&E, 400X Intraneural perineurioma with whorling pseudo-onion bulb formations. B- EMA, 400X the neoplastic perineurial cells are positive for EMA (brown stain) in a membranous distribution. C- Plastic-embedded thin section, toluidine blue, 400X Myelin is dark blue with this stain. Note residual thinly myelinated axons among the pseudo-onion bulb formations (arrow).

By immunohistochemistry, true onion bulb formations include S100-positive Schwann cells. Perineurial cells are positive for Epithelial Membrane Antigen (EMA) and are S100-negative [6-8]. Neurofilament staining highlights the axons within the pseudo-onion bulb formations of the tumor. EMA-positive, S100-negative pseudo-

onion bulbs are not a feature of neurofibroma, schwannoma, or traumatic neuroma [5]. CIDP and CMT can have true onion bulbs that are S100-positive and EMA-negative.

CSF protein is almost always normal in perineurioma but is elevated in CIDP. Electrodiagnostic studies in nerves affected by perineurioma can show features of demyelination and axonal degeneration. MRI demonstrates segmental thickening and abnormal hyperintense signal of nerve on the axial T2-weighted fat saturated images.

Without treatment, the prognosis of perineurioma is poor, as the tumor is a progressive condition that will eventually cause total loss of nerve function. The most common treatment is surgical resection with nerve grafting or end-to-end anastomosis. Recurrence is uncommon with complete surgical resection [9,10]. This WHO grade I tumor has not been associated with systemic metastases [11].

Conclusion

Intraneural perineurioma should be included in the differential diagnosis of focal neuropathy in a young adult. Imaging and electrodiagnostic studies can be useful to indicate the likely presence of an intraneural neoplasm. Surgical resection with histopathologic evaluation of biopsy tissue is required for definitive diagnosis.

References

1. Ostergaard JR, Smith T, Stausbøl-Grøn B (2009) Intraneural perineurioma of the sciatic nerve in early childhood. *Pediatr Neurol* 41: 68-70.
2. Imaginariojda G, Coelho B, Tome F, Luis M (1964) Monosymptomatic Interstitial Hypertrophic Neuritis. *J Neurol Sci* 1: 340-347.
3. Emory TS, Scheithauer BW, Hirose T, Wood M, Onofrio BM, et al. (1995) Intraneural perineurioma. A clonal neoplasm associated with abnormalities of chromosome 22. *Am J Clin Pathol* 103: 696-704.
4. Hamazaki S, Fujiwara K, Okada S (2004) Intraneural perineurioma involving the ulnar nerve. *Pathol Int* 54: 371-375.
5. Wang LM, Zhong YF, Zheng DF, Sun AP, Zhang YS, et al. (2014) Intraneural perineurioma affecting multiple nerves: a case report and literature review. *Int J Clin Exp Pathol* 7: 3347-3354.
6. Almefty R, Webber BL, Arnautovic KI (2006) Intraneural perineurioma of the third cranial nerve: occurrence and identification. Case report. *J Neurosurg* 104: 824-827.
7. Boyanton BL Jr, Jones JK, Shenaq SM, Hicks MJ, Bhattacharjee MB (2007) Intraneural perineurioma: a systematic review with illustrative cases. *Arch Pathol Lab Med* 131: 1382-1392.
8. Wadhwa V, Thakkar RS, Maragakis N, Höke A, Sumner CJ, et al. (2012) Sciatic nerve tumor and tumor-like lesions - uncommon pathologies. *Skeletal Radiol* 41: 763-774.
9. Damm DD, White DK, Merrell JD (2003) Intraneural perineurioma--not restricted to major nerves. *Oral Surg Oral Med Oral Pathol Oral Radiol Endod* 96: 192-196.
10. Kuntz NL (2008) Diagnosis and treatment of peripheral nerve lesions in children. *Pediatrics and Child Health* 18: s39-s42.
11. Louis DN, Ohgaki H, Wiestler OD, Cavenee WK, Burger PC, et al. (2007) The 2007 WHO classification of tumours of the central nervous system. *Acta Neuropathol* 114: 97-109.