

Intracranial Hypertension in Behcet Disease: A Case Report

Figen Guney^{1*}, Banu Bozkurt² and Yahya Paksoy³

¹Department of Neurology, Necmettin Erbakan University, Turkey

²Department of Ophthalmology, Selcuk University, Turkey

³Department of Radiology, Selcuk University, Turkey

Abstract

Behcet disease (BD) is a chronic multisystem disorder characterized predominantly by recurrent episodes of occlusive vasculitis. According to the accumulated data, it is seen that intracranial hypertension generally develops secondary to the cerebral venous sinus thrombosis in BD. In the study, it was aimed in light of literature to discuss a case where intracranial hypertension occurred without venous sinus thrombosis. A 36-year-old female was evaluated for the symptoms of blurred vision in her left eye for the last 3 months and transient visual obscurations in her right eye beginning 3 days ago. It was found out that the patient had been diagnosed with BD one and a half months ago. Fundus examination revealed bilateral swollen optic discs. Lumbar puncture revealed an opening pressure of 360 mm H₂O, with normal composition. The patient was diagnosed with intracranial hypertension developing secondary to BD according to modified Dandy criteria. Methylprednisolone 1000 mg intravenously (IV) for 5 days, followed by prednisolone 60 mg po, was administered. A significant improvement was observed in the complaints and papilledema of the patient. Inflammation could play a significant role in the intracranial hypertension developing without venous sinus thrombosis in BD. As a result, BD should be considered in the differential diagnosis in patients with intracranial hypertension especially in areas where the disease prevalence is high.

Keywords: BD; Occlusive vasculitis; Intracranial hypertension; Inflammation

Introduction

Behcet disease (BD) is a chronic multisystem disorder characterized predominantly by recurrent episodes of occlusive vasculitis. The diagnosis remains mostly clinical and currently the most widely used diagnostic criterion is the International Study Group's classification, according to which a definitive diagnosis required recurrent oral ulcerations plus two of the following: recurrent genital ulcerations, skin lesions, eye lesions and a positive pathergy test. The prevalence of BD is very high in Japan (7-8.5:100,000) and might be even higher in Mediterranean countries (80-300:100,000 in two areas in Turkey) compared with Western countries (1:500,000 in North America) [1-13].

Clinical and imaging data suggest that the clinical variation is also seen with the neurological involvement in BD, which may be sub-classified into two major forms. One is attributable to small venous inflammatory disease with focal or multifocal central nervous system (CNS) parenchymal involvement, and is seen in the majority of patients. It is designed the central nervous system-neuro-Behçet syndrome (CNS-NBS or intra-axial neuro-Behçet syndrome). The other form is caused by cerebral venous sinus thrombosis (CVST or extra-axial NBS) with limited symptoms and a better neurological prognosis. The reported frequency of neurological involvement among BD patients ranges from 2.2% to 49%, but larger series have shown a rate of approximately 5%. Intracranial hypertension is the most common example and has special importance in Behçet's disease (BD). These patients, with or without dural sinus thrombosis, comprise 11-35% of all n-BD patients. Herein, it was aimed to discuss a case which has papilledema and intracranial hypertension developing without venous sinus thrombosis, along with BD [14-23].

Case Report

A 36-year-old female was evaluated for the symptoms of blurred vision in her left eye for the last 3 months and transient visual obscurations in her right eye beginning 3 days ago. Visual obscurations in her right eye lasted a few seconds and occurred several times a day. It was found out that the patient had been diagnosed with BD according to criteria by International study group one and a half months earlier.

She had multiple apthous ulcers and genital ulcers for two years. The patient had developed pustular skin lesions in her arms and legs 6 months ago, and applied to no doctors until one and a half months ago owing to these complaints. For one and a half month, she had been found out to be administered with 0.5 mg pills 3 × 1 p.o of colchicine. She had no history of taking hormonal contraceptives, Vitamin A, or tetracycline. In addition to these, the patient was determined to have tension type headache (according to IHS criteria). She was afebrile and fully oriented, with no neck stiffness. Several oral ulcers were present, as well as erythema nodosum on the arms and legs. Her best corrected visual acuities were 20/20 and 20/25 in her right and left eyes with +1.00 D, respectively. Intraocular pressure measured with Goldmann application tonometry were 16 mmHg in both eyes. Fundus examination revealed bilateral swollen optic discs with blurred margins, splinter hemorrhages on the disc margins and tortuous vessels (Figures 1a and 1b). Ishihara colour testing was normal in both eyes. Humphrey visual field demonstrated a remarkable visual field loss in the superonasal quadrant, a mild loss in the inferonasal quadrant and an enlarged blind spot in the right eye (Figure 2a) and a severe visual field loss in the inferior quadrant and an enlarged blind spot in the left eye (Figure 2b and 2c). Pattern visual evoked potential (p-VEP) amplitudes and P100 wave latencies (100 and 107 ms) were normal in the right and left eyes, respectively (Figure 3a and 3b). Her weight was 82.4 kg, height 156 cm, waist-hip ratio was 100 cms and body mass index was 33.90. The case was examined with cranial, orbital MR imaging (MRI), and intracranial venous MR angiographic protocols. There was no abnormality in venous imaging. Cranial MR imaging was normal, except for the depression of the hypophysis towards to sella

***Corresponding author:** Figen Guney, Department of Neurology, Necmettin Erbakan University, Turkey, Tel: +90 332 2236380; Fax: +90 332 3340492; E-mail: guneyfigen@yahoo.com.tr

Received October 12, 2015; **Accepted** March 26, 2016; **Published** March 31, 2016

Citation: Guney F, Bozkurt B, Paksoy Y (2016) Intracranial Hypertension in Behcet Disease: A Case Report. J Clin Case Rep 6: 748. doi:[10.4172/2165-7920.1000748](https://doi.org/10.4172/2165-7920.1000748)

Copyright: © 2016 Guney F, et al. This is an open-access article distributed under the terms of the Creative Commons Attribution License, which permits unrestricted use, distribution, and reproduction in any medium, provided the original author and source are credited.

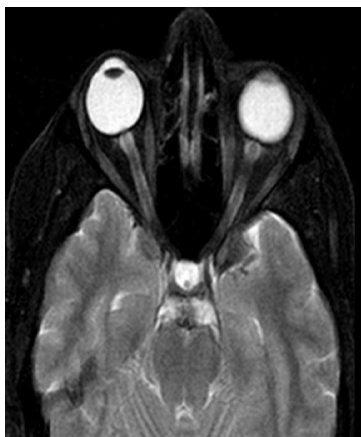

Figure 1a: Right fundus photographs showing swollen optic discs with blurred margins, splinter hemorrhages on the disc margins and tortuous vessels.

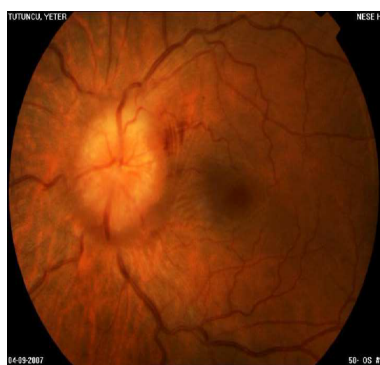


Figure 1b: Left fundus photographs showing swollen optic disc with blurred margins, splinter hemorrhages on the disc margins and tortuous vessels.

floor. Orbital T2- weighted fat suppressed MR image showed excess of fluid around the optic nerve and contrast enhanced T1-weighted fat suppressed axial MR image showed bilateral small protrusion in optic disk place. These findings suggested intracranial hypertension.

Lumbar puncture revealed an opening pressure of 360 mm H₂O, with normal composition. The IgG index is normal in cerebrospinal fluid (CSF). Oligoclonal band (OCB) was negative in CSF. HLA typing was positive for B5. Complete blood count, routine biochemistries, liver function tests, thyroid function tests, lipid profiles, and creatine kinase level were all normal limits. Rheumatoid factor, C-reactive protein, ASO, antinuclear antibody titers, anti-dsDNA antibodies were normal. Serological testing (HIV, CMV, EBV, hepatitis virus, syphilis, toxoplasmosis, borrelia, brucella) were negative. The patient was evaluated to have intracranial hypertension developing secondary to BD according to Dandy criteria. Methylprednisolone 1000 mg IV for 5 days, followed by prednisolone 60 mg p.o., was administered. The dose of prednisolone was planned to be tapered decreasingly within three months' time. The visual obscuration complaint in the right eye of the patient was completely improved after ten days, and the complaint of blurred vision in the left eye was also partly decreased. Lumbar puncture was performed again. CSF pressure was 130 mm H₂O. Twenty days after treatment, MR appearance of previous pathologies was regressed. In her follow-up 2 months later, she was also advised to lose weight, since the body index of the patient indicated obesity. Her uncorrected visual acuities were 20/20 and

20/25 in her right and left eyes, respectively, and she was emmetropic. Fundus examination revealed resolution of her disc edema in both eyes with optic disc pallor in her both eyes (Figures 1c and 1d). Intraocular pressures measured with Goldmann applanation tonometry were 17 mmHg and 15 mmHg, in the right and left eye, respectively, and she was emmetropic. Humphrey visual field demonstrated a remarkable

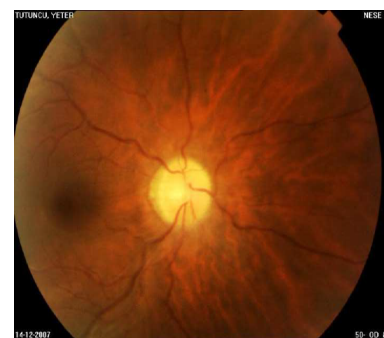

Figure 1c: Fundus photographs of both eyes showing complete resolution of papilledema.

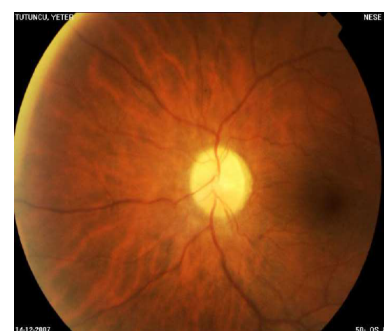


Figure 1d: Fundus photographs of both eyes showing complete resolution of papilledema.

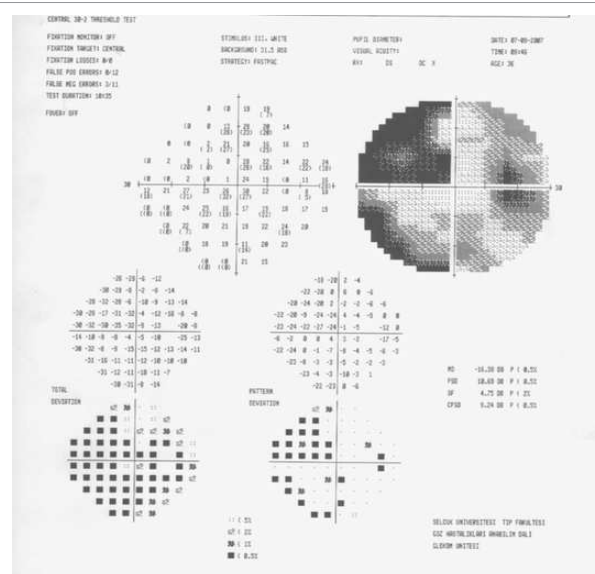


Figure 2a: Humphrey visual field demonstrates a remarkable visual field loss in the superonasal quadrant, a mid loss in the inferonasal quadrant and an enlarged blind spot in the right eye.




Figure 2b: Humphery visual field demonstrates a severe visual field loss in the inferiorquadrant and an enlarged blind spot in the left eye.

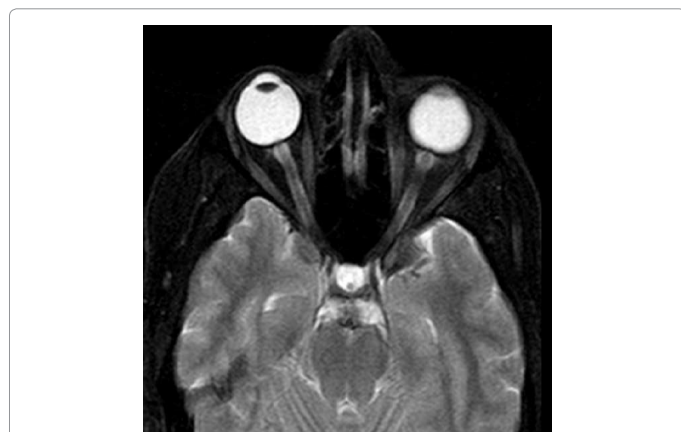

Figure 2c: Humphery visual field demonstrates a remarkable improvement with only a mildvisual field loss in the inferonasal quadrant and an enlarged blind spot in the right eye.

improvement with only a mild visual field loss in the inferonasal quadrant and enlarged blind spot in the right eye and a moderate visual field loss in the inferior quadrant and enlarged blind spot in the left eye. P-VEP showed delayed latency in P100 wave in right (128 ms) and left eyes (127 ms), compared to the initial P-VEP tests (Figure 3b). No difference was observed in the body mass index of the patient during her 2-month follow-up.

Discussion

BD is a multisystem vasculitis of unknown origin. Recurrent oral ulcer can be found in 99% of all patients and it is the first symptom in 70% of the cases. Ocular compromise can be found in up to 70-85% of the patients, skin lesions in 85% of cases and genital ulcers in approximately 70%. It has a world-wide distribution with clustering among populations having a high prevalence of HLA-B5. The most common ocular symptom is that of anterior uveitis, but necrotizing retinal vascular lesions can also be present and are frequently obscured

by the severity of the anterior reaction, but in the absence of uveitis, papilledema is a rare manifestation and has been described infrequently.

Masheter first reported the co-existence of headaches developing secondary to intracranial thromboflebitis and papilledema in BD. Wolf et al. also suggested that only papilledema as an indicator of the involvement of CNS could be rarely observed in BD without headaches, nausea and vomiting. In a study including 32 patients with BD and performed by Colvard et al., ocular manifestations in all patients were assessed, and it was reported that only 3 patients were diagnosed with papilledema, but uveitis was determined in all those 3 subjects. Kalbian and Challis reported that papilledema was determined in 5 of 12 patients with BD and pointed out that of all these 5 cases, only 2 had papilledema not accompanied by uveitis. Benign intracranial hypertension was reported to be in those 3 patients with papilledema. Of these 3 patients, 2 were reported to have nausea, vomiting, neck stiffness and bilateral papilledema, and no assessment could be carried out as to CSF.

Pamir et al. reported papilledema developing secondary to intracranial hypertension to be determined in 6 cases with BD. Headache was also reported to be marked in all of the patients. Of 6

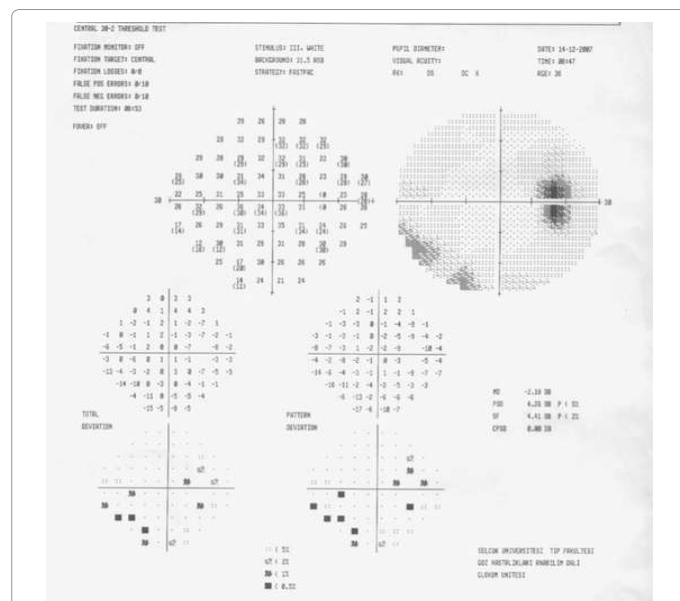


Figure 2d: Humphery visual field demonstrates a moderate visual field loss in the inferiorquadrant and enlarged blind spot in the left eye.

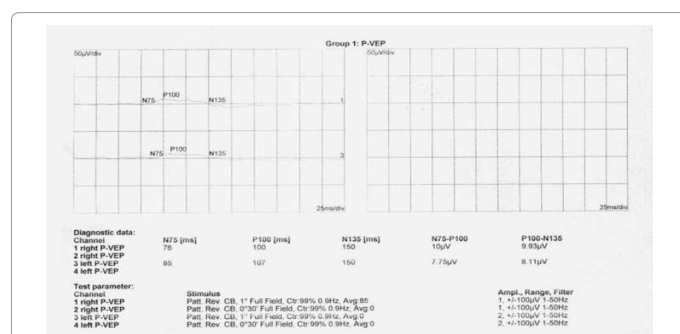


Figure 3a: P-VEP amplitudes and P100 wave latencies (100 and 107 ms) are normal both in the right and the left eyes, respectively.

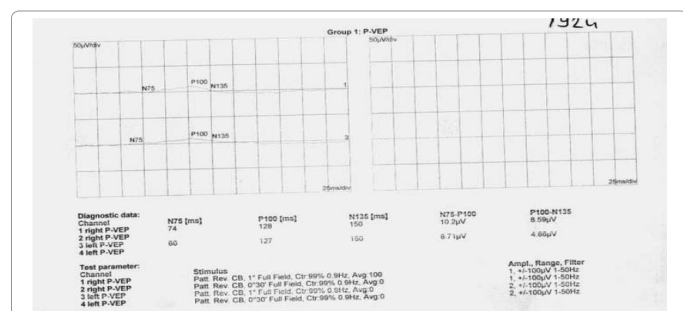


Figure 3b: PVEP showing delayed latency in P100 wave in the right (128) and the left eyes (127 ms).

patients, 3 were also reported to display an increase in intracranial pressure secondary to dural venous sinus thrombophlebitis. Teh et al. reported 2 cases with BD with headaches and bilateral papilledema, as well as intracranial hypertension. It was also suggested in this report that no dural sinus thrombosis was detected in these patients. Gallinaro et al. reported a case with papillitis and sixth nerve paresis secondary to BD. Mitra and Koul, reported a girl at the age of 10, who had been firstly presented with papilledema and intracranial hypertension and then found to have BD. Akman-Demir et al. reported intracranial hypertension in 34 of 200 neuro-BD cases, and pointed out that intracranial hypertension was secondary to dural sinus thrombosis in 20 of them, and it was secondary to superior vena cava occlusion in one case. In the report despite adequate radiological studies, intracranial hypertension etiology wasn't determined in 5 patients. No MRI or angiographic evaluation could be improved in 8 patients. Siva et al. performed CSF investigation in 47 of 164 cases with BD and found that 10 of them (21%) had higher CSF pressures. In the 8 of 47 patients, no MRI or CT could be performed; of 39 patients, 30 were determined parenchymal lesion, 4 to be venous sinus thrombosis and 5 to be normal MRI values. Çelebisoy et al. researched 62 pseudotumour patients etiologically in 2002, and 3 patients were reported to have BD, 1 of the 3 patients was determined to have sinus thrombosis and use of oral contraceptive pills, and 1 to have only venous sinus thrombosis. The third case had only BD. Besides, 33 patients with pseudotumour cerebri were determined to have obesity in their etiology. Tarzi et al. presented a BD case with bilateral papilledema, exhibiting normal CSF pressure. Erdem et al. reported a BD with intracranial hypertension secondary to dural sinus thrombosis. 12-year-old male case of BD with intracranial hypertension developing secondary to inferior sagittal sinus thrombosis was reported by Can et al.

However, in the cases of BD mentioned above to be co-existed with intracranial hypertension, except for the study by Çelebisoy et al., no information about whether such results as obesity to precipitate intracranial hypertension exist in the patients was encountered. In our case, it could be considered that obesity induces intracranial hypertension, along with BD.

In the light of the literature, pseudotumour cerebri occurs potentially in obese women of child-bearing age. However, contrary to popular belief, there is no evidence that body weight influences these cutoff values. In the literature, there is inconsistent information about whether obesity caused intracranial hypertension or not. There is evidence that weight reduction may lead to resolution of intracranial hypertension. A direct cause and effect mechanism has been proposed, with increased intra-abdominal and intra-thoracic pressure causing raised central venous pressures, but this does not explain the fact that although obesity is common, intracranial hypertension is rare.

However, it is well-established that high pressure headache may arise without papilledema, and it is possible that obesity is the cause of the headache in the patients by this mechanism.

However, on 10th day of the treatment, both CSF pressure turned to normal values and on the tenth day of the treatment and the symptoms of the patient pulled through although there is no change in the body as index of the patient. This may suggest that obesity is not very effective in the occurrence of intracranial hypertension.

The syndrome of increased intracranial pressure (ICP) without ventriculomegaly or mass lesion, and with normal cerebrospinal fluid (CSF) composition, was first described more than a century ago, yet little is still known concerning its pathogenesis. Conditions causing intracranial hypertension: The Monroe-Kellie hypothesis postulates that the intracranial volume is composed of blood volume, CSF and brain volume. Any addition of volume or any process blocking CSF flow will cause an increase ICP. Conditions causing increased ICP can be grouped into four subsets: 1. Increased CSF production, 2. Increased vascular volume, 3. Increased venous pressure with subsequent reduced CSF resorption, and 4. reduced reuptake of CSF through the paccionian granulations.

BD is thought to have an autoimmune origin on the basis of the vasculitic nature of the disease and the cellular characteristics of the lesion infiltrate. The principal features include perivascular infiltrates of lympho-mononuclear cells, swelling or proliferation of endothelial cells leading to partial obliteration of small vessels, and fibrinoid degeneration. Inflammation is thought to be mediated in part by cytokines associated with the Th1 subset of T lymphocytes. A number of inflammatory markers have been shown to be elevated in the serum of patients, including TNF, interleukin (IL)-1B, IL-18, and IL-8. Up regulation of T-bed expression has been reported, providing further support for the role of the Th1 subset of T cells in BD [24-27].

Conclusion

As seen in our case, intracranial hypertension can develop without venous sinus thrombosis and papilledema can be seen without active uveitis findings in some cases with BD. In BD, inflammation can play an important role in intracranial hypertension without venous sinus thrombosis. Non-granulomatous inflammation within the CSF space may reduce reuptake of CSF through paccionian granulations and the condition also causes increased ICP. A definite response to the treatment in our case with corticosteroids supports the role of inflammation in intracranial hypertension.

As a result, BD should be considered in the differential diagnosis in patients with intracranial hypertension, especially in areas where the disease prevalence is high.

References

1. Akman-Demir G, Serdaroglu P, Tasçi B (1999) the Neuro-Behçet study group. Clinical patterns of neurological involvement in Behçet's disease: evaluation of 200 patients. *Brain* 122: 2171-2181.
2. Akman-Demir G, Bahar S, Baykan-Kurt B, Gurvit IH, Serdaroglu P (1996) Intracranial hypertension in Behçet's disease. *Eur J Neurol* 3: 33-70.
3. Can E, Kara B, Somer A, Keser M, Salman N (2006) Neuro-Behçet disease presenting as secondary pseudotumor syndrome: case report. *European Journal of Paediatric Neurology* 97-99.
4. Colvard DM, Robertson DM, O'Duffy JD (1977) The ocular manifestations of Behçet's disease. *Arch Ophthalmol* 95: 1813-1817.
5. Celebisoy N, Seçil Y, Akyürekli O (2002) Pseudotumor cerebri: etiological factors, presenting features and prognosis in the western part of Turkey. *Acta Neurol Scand* 106: 367-370.

6. Erdem H, Dinç A, Pay S, Simşek I, Uysal Y (2006) A neuro-Behçet's case complicated with intracranial hypertension successfully treated by a lumboperitoneal shunt. *Joint Bone Spine* 73: 200-201.
7. Friedman DI, Jacobson DM (2004) Idiopathic intracranial hypertension. *J Neuroophthalmol* 24: 138-145.
8. Gallinano C, Robinet-Combes A, Sale Y, Richard P, Saraux A, et al. (1995) [Neuropapillitis in Behçet disease. A case]. *J Fr Ophtalmol* 18: 147-150.
9. Borhani Haghighi A, Pourmand R, Nikseresht AR (2005) Neuro-Behçet disease. A review. *Neurologist* 11: 80-89.
10. Headache classification committee of the International Headaches Society (2004) The international classification of headache disorders. *Cephalalgia* 24: 1-160.
11. (1990) Criteria for diagnosis of Behçet's disease. International Study Group for Behçet's Disease. *Lancet* 335: 1078-1080.
12. Kalbani VV, Challis MT (1970) Behçet's disease. Report of twelve cases with three manifesting as papilledema. *Am J Med* 49: 823-829.
13. Li B, Yang P, Zhou H, Zhang Z, Xie C, et al. (2003) T-bet expression is upregulated in active Behçet's disease. *Br J Ophthalmol* 87: 1264-1267.
14. Masheter HC (1959) Behcet's syndrome complicated by intracranial thrombophlebitis. *Proc R Soc Med* 52: 1039-1040.
15. Mege JL, Dilsen N, Sanguedolce V (1993) Overproduction of monocyte derived tumor necrosis factor alpha, interleukin (IL)6, IL-8 and increased neutrophil superoxide generation in Behçet's disease. A comparative study with familial Mediterranean fever and healthy subjects. *J Rheumatol* 20: 1544-1549.
16. Mitra S, Koul RL (1999) Paediatric neuro-Behçet's disease presenting with optic nerve head swelling. *Br J Ophthalmol* 83: 1096.
17. Nishida T, Hirayama K, Nakamura S, Ohno S (1998) Proliferative response of CD8+ gamma delta+ T cells to *Streptococcus sanguis* in patients with Behçet's disease. *Ocul Immunol Inflamm* 6: 139-144.
18. Pamir MN, Kansu T, Erben A, Zileli T (1981) Papilledema in Behçet's syndrome. *Arch Neurol* 38: 643-645.
19. Lee SK, Choi SJ, Kim SD, Lim DJ (2011) Rapid Atypical Progression of Neuro-Behçet's Disease Involving Whole Brainstem and Bilateral Thalami. *J Korean Neurosurg Soc* 50: 68-71.
20. Serdaroğlu P (1998) Behçet's disease and the nervous system. *J Neurol* 245: 197-205.
21. Siva A, Kantarci OH, Saip S, Altintas A, Hamuryudan V, et al. (2001) Behçet's disease: diagnostic and prognostic aspects of neurological involvement. *J Neurol* 248: 95-103.
22. Tarzi MD, Lightman S, Longhurst HJ (2005) An exacerbation of Behçet's syndrome presenting with bilateral papillitis. *Rheumatology (Oxford)* 44: 953-954.
23. Teh LS, O'Connor GM, O'Sullivan MM, Pandit JC, Beck L, et al. (1990) Recurrent papilloedema and early onset optic atrophy in Behçet's syndrome. *Ann Rheum Dis* 49: 410-411.
24. Walker RW (2001) Idiopathic intracranial hypertension: any light on the mechanism of the raised pressure? *J Neurol Neurosurg Psychiatry* 71: 1-5.
25. Wolf SM, Schotland DL, Phillips LL (1965) involvement of nervous system in behcet's syndrome. *Arch Neurol* 12: 315-325.
26. Yates PA, Michelson JB (2006) Behçet disease. *Int Ophthalmol Clin* 46: 209-233.
27. Yazici H (1994) Behçet's syndrome (the vasculitides). In: Klippel JH, Dieppe PA (Eds). *Rheumatology*; Mosby Year Book, Europe, London.