

Intraoperative Functional Luminal Imaging to Assess Esophagogastric Junction Distensibility during Per-Oral Endoscopic Myotomy in Pediatric Patients

Robert Wright, Stephanie Chao, James Wall*

Division of Pediatric Surgery, Lucile Packard Children's Hospital Stanford, USA

*Corresponding author: James Wall, 777 Welch Road, Suite J Stanford CA 94305, USA, Tel: 650-725-5577; E-mail: jkwall@stanford.edu

Received date: July 04, 2014, Accepted date: Aug 14, 2014, Published date: Aug 20, 2014

Copyright: © 2014 Wright R, et al. This is an open-access article distributed under the terms of the Creative Commons Attribution License, which permits unrestricted use, distribution, and reproduction in any medium, provided the original author and source are credited.

Abstract

Per-oral Endoscopic Myotomy (POEM) is a transmural endoscopic surgical technique that is gaining widespread adoption in the management of adult achalasia. The endoscopic approach offers excellent access to the muscular wall of the esophagus enabling division of the abnormal circular fibers. The procedure offers the benefits of being incisionless, preserving the outer longitudinal esophageal muscle fibers and avoiding a hiatal dissection. Endoscopic functional luminal imaging probes enable real-time measurement of luminal diameter and pressure. These probes offer intraoperative guidance to the extent and completeness of the POEM procedure. Post-operative measurements have been correlated to outcomes of dysphagia and reflux in the adult population. No functional luminal imaging exists for the pediatric population. 2 POEM procedures were performed at our children's hospital using luminal imaging.

Keywords: Per-oral endoscopic myotomy; Pediatric patients; Childrens

Introduction

Per-oral Endoscopic Myotomy (POEM) is a transmural endoscopic surgical technique for the treatment of esophageal motility disorders including achalasia. The POEM for achalasia is performed by making a mucosal incision in the esophageal wall and then creating a submucosal tunnel that allows endoscopic access to the muscular layers of the esophagus. The endoscopic approach is incisionless and enables the potential advantage of selective division of the inner circular muscles fibers implicated in the pathophysiology of achalasia without cutting the outer longitudinal muscle fibers. The POEM does not include an anti-reflux procedure. Proponents believe that avoiding a hiatal dissection and avoiding division of the longitudinal fibers may reduce the rate of reflux compared to the high rate of reflux seen after Heller myotomy alone, which has made fundoplication a standard adjunct to the procedure.

The POEM technique was proposed in a survival animal study by Pasricha et al. in 2007 [1]. Inoue performed the first human procedures in 2008 for achalasia in Japan with no serious complications and promising long-term results [2]. Stavropoulos introduced the POEM procedure to North America in 2010 [3]. Swanstron et al. went on to show excellent long term results and compare POEM to Laparoscopic Heller Myotomy (LHM) with partial fundoplication in a retrospective non-randomized review of outcomes from their institution [4]. In both POEM and LHM, symptoms and objective esophageal physiology were equally improved with similar rates of reflux. Patients undergoing POEM had a significantly shorter hospital stay. Larger randomized prospective studies are needed to further show the risks and benefits of POEM compared to LHM. POEM does have the potential to be a treatment option for patients with comorbidities which may limit surgical options. An endoscopic approach also offers access to areas of the esophagus not possible with LHM. In the pediatric population, the incidence of achalasia is low

with an annual estimated incidence is 0.02 to 0.18 cases per 100,000 children [5,6]. Accordingly, the POEM procedure has been reported in only a few pediatric cases globally [7-9].

Endolumenal Functional Lumen Imaging Probe (EndoFLIP, Crospon, Galway Ireland) is an endoscopic balloon catheter that measures the pressure within the balloon and the diameter of the catheter at 5 mm increments for a total length of 8 cm. Using these measurements, further characteristics such as distensibility can be calculated [10]. The system has been used to calibrate Nissen fundoplication and other upper GI interventions [11]. Pre- and post-operative measurements were reported for a cohort of adults undergoing POEM with an average age of 51.7 years. Pre-POEM diameter and cross-sectional area at a fill volume of 30ml were 6.3 mm (± 1.8) and 32.9 mm² (± 23.1), respectively. Post-POEM diameter and cross-sectional area of the gastroesophageal junction were 11.3 mm (± 1.7) and 102.38 mm² (± 28.2) [12]. Average post-operative Eckardt score was 1 (0-3).

The EndoFLIP system offer significant potential benefits in the POEM procedure as the surgeons ability to visually determine the extent and adequacy of the myotomy is limited. No baseline data for EndoFLIP exists in pediatric achalasia.

Methods

Two male teenage patients, ages 16 and 17 years old, with Type I achalasia were offered the POEM procedure with endolumenal functional imaging under an IRB approved protocol (IRB#26375).

The achalasia symptoms were measured both pre-myotomy and one month post-myotomy using the Eckardt score [13]. The Eckardt score is a cumulative score of the four most common symptoms of achalasia (dysphagia, chest pain, regurgitation, and weight loss). The totals range from 0 to 12 with 12 being the most severe. A post-treatment score of less than four is successful.

The POEMs were performed using a GIF-H180 high-definition gastroscope with a single 2.8 mm working channel (Olympus, Center Valley PA). An esophageal overtube (US Endoscopy, Mentor, OH) was used to facilitate repeated introductions of the endoscope. The distance to the GE junction was measured and the entry site for the mucosal incision was chosen 10 cm above the GE junction. The mucosa was elevated using a submucosal injection of indigo carmine. A 2 cm longitudinal mucosal incision was made at the 20'clock position (Figure 1a) using a triangle tip endoscopic knife (Olympus, Center Valley, PA). An angled clear endoscopic cap (Olympus, Center Valley PA) facilitated entry through the mucosal incision into the

submucosal plane. A tunnel was created through the submucosal plane to the level of the GE junction using a combination of blunt dissection, triangle tip cautery and indigo carmine injections (Figure 1b). The tunnel was carried 2 cm onto the stomach and the extent of tunneling was confirmed by retroflex view from the stomach. The circular muscle fibers of the esophagus were divided beginning 2 cm below the gastro-esophageal junction (Figure 1c). The final myotomy was 8-9 cm in length and bacitracin solution was used to irrigate the tunnel prior to closure. The mucosotomy was closed (Figure 1d) using multiple endoscopic clips (Olympus, Center Valley, PA).

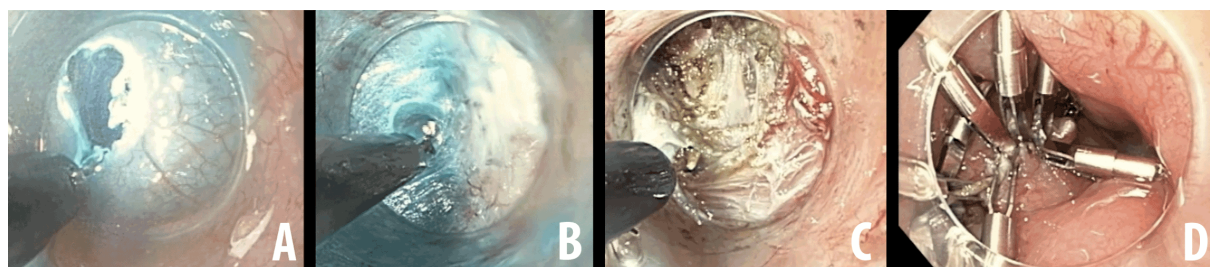


Figure 1: Selected intraoperative images of the Per-Oral Endoscopic Myotomy. A) Mucosal incision B) Dissection of the submucosal plane exposing circular muscle fibers C) Selective division of circular muscle fibers with preservation of underlying longitudinal muscle fibers D) closure of mucosal incision with endoscopic clips.

EndoFLIP intraluminal imaging was used pre- and post-POEM in both cases (Figure 2). The EndoFLIP catheter was centered at the gastroesophageal junction and a fill volume of 30 ml was used to achieve balloon pressures of 15-25 mmHg, enabling apposition of the balloon to the lumen wall without dilation. This was completed under general anesthesia immediately prior to the mucosal incision and after the division of the circular muscle fibers prior to mucosotomy closure.

one-month as measured by Eckardt score was similar to what has been reported in the adult population.

Results

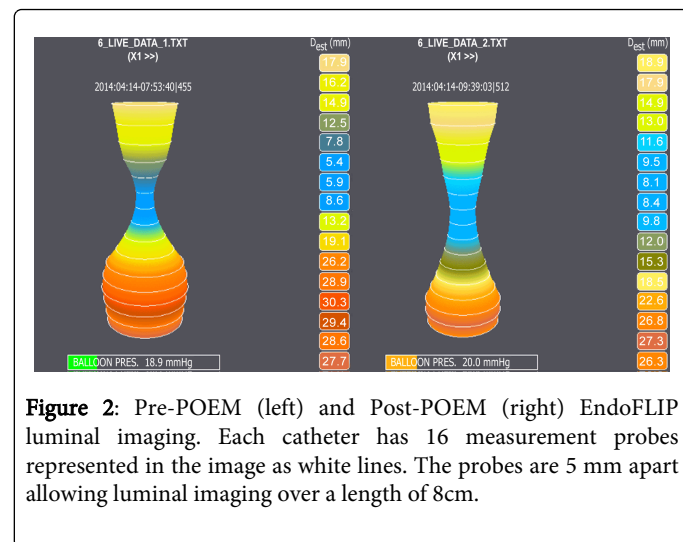
The first patient was 16 years old (64.5 kg) with a pre-operative Eckardt score of 5 and the second was 17 years old (39.6 kg) with a pre-operative Eckardt score of 10. At one-month follow-up both patients reported complete resolution of dysphagia and regurgitation and reported Eckardt scores of 0 and 1 respectively.

The POEMs were performed by a pediatric surgeon with an average operative time of 222 minutes. One patient developed an intra-operative carboperitoneum that was decompressed with a Varess needle. Both patients were placed on a liquid diet for a period of two weeks and then advanced to a regular diet.

Pre- and Post-POEM measurements are shown in Table 1. Notably there was a sizeable increase for both patients in the distensibility scores from pre- (0.98 mm²/mmHg and 1.17 mm²/mmHg) to post-POEM (2.63 mm²/mmHg and 2.47 mm²/mmHg).

Discussion

POEM procedures were successfully performed in the pediatric population using the EndoFLIP luminal imaging system. The pre- and post-POEM diameters, cross-sectional areas and distensibilities are all on the low end of the ranges reported in adult patients whose average age in the fifth decade of life. However, the resolution of symptoms at



Patient	1	2
Pre_POEM weight (kg)	64.5	39.6
Pre-POEM Eckardt score	5	10
Pre-POEM minimum diameter (mm)	5.1	5.4
Pre-POEM minimum Cross Sectional Area (mm ²)	21	23
Pre-POEM Distensibility (mm ² /mmHg)	0.98	1.17
Post-POEM Eckardt score	0	1

Post-POEM minimum diameter (mm)	8.7	8.1
Post-POEM minimum Cross Sectional Area (mm ²)	59	52
Post-POEM Distensibility (mm ² /mmHg)	2.63	2.47

Table 1: Pediatric POEM Cases; All values at 30 ml filling mode.

While the current patients did not reach the EG junction distensibility mark of 2.9 set by Rohof [14] their symptoms were resolved and they have not developed any recurrence. The 2.9 cutoff

was developed using a cohort of healthy adults (40 ± 4.1 years). Additional studies in adults measuring distensibility pre- and post-POEM (Table 2) have much higher post distensibility (8.2 ± 3) [15]. The patients in these studies did have slightly higher pre distensibility (1.8 ± 1.1). There may be fundamental differences in the distensibility of adults and children past the physical size or space such as tissue plasticity. Studies in children with larger samples and a healthy baseline will be needed to establish age specific recommendations [16-18]. Long-term EndoFLIP imaging in POEM patients may also help explain the differences observed.

Patient	Rieder et al. [16]	Teitelbaum et al. [15]	Teitelbaum et al. [17]	Verlaan et al. 2013 [18]
Number of POEM Patients	4	14	19	10
Age (in years)	64 17	48 15	49 16	43 (IQR 31-66)
Pre-POEM Eckardt score		7 2	7 2	8 (IQR 4-8)
Pre-POEM Distensibility (mm ² /mmHg)	0.8 (0.7-1.0)	1.8 1.1	1.8 1.4	1.0 (IQR 0.8-1.5)
Post-POEM Measure	Immediately after POEM			3 months after POEM
Post-POEM Eckardt score		Not reported	Not reported	1 (IQR 0-1)
Post-POEM Distensibility (mm ² /mmHg)	3.1 (Range 1.7-3.4)	8.2 3	9.3 4.1	2.9 (IRQ 1.3-19.6)

Table 2: Adult reported POEM cases; All values at 30 ml filling mode.

In conclusion, two successful POEM procedures in children have been completed using intra-operative measurement techniques. In contrast to adults, early results suggest teenage patients may initially have narrower EG junctions leading to lower post-myotomy distensibility. Short-term health outcomes have been excellent possibly indicating a lower distensibility threshold for pediatric patients. With similar or potentially better outcomes, endoscopic procedures have the potential to reduce patient inconveniences such as pain and hospital stay. Further, the use of intra-operative luminal imaging allows the surgeon real-time feedback on their progress.

References

- Pasricha PJ, Hawari R, Ahmed I, Chen J, Cotton PB, et al. (2007) Submucosal endoscopic esophageal myotomy: a novel experimental approach for the treatment of achalasia. *Endoscopy* 39: 761-764.
- Inoue H, Minami H, Kobayashi Y, Sato Y, Kaga M, et al. (2010) Peroral endoscopic myotomy (POEM) for esophageal achalasia. *Endoscopy* 42: 265-271.
- Stavropoulos SN, Harris MD, Hida S, Brathwaite C, Demetriou C, et al. (2010) Endoscopic submucosal myotomy for the treatment of achalasia (with video). *Gastrointest Endosc* 72: 1309-1311.
- Bhayani NH, Kurian AA, Dunst CM, Sharata AM, Rieder E, et al. (2014) A comparative study on comprehensive, objective outcomes of laparoscopic Heller myotomy with per-oral endoscopic myotomy (POEM) for achalasia. *Ann Surg* 259: 1098-1103.
- Mayberry JF, Mayell MJ (1988) Epidemiological study of achalasia in children. *Gut* 29: 90-93.
- Marlais M, Fishman JR, Fell JM, Haddad MJ, Rawat DJ (2011) UK incidence of achalasia: an 11-year national epidemiological study. *Arch Dis Child* 96: 192-194.
- Maselli R, Inoue H, Misawa M, Ikeda H, Hosoya T, et al. (2012) Peroral endoscopic myotomy (POEM) in a 3-year-old girl with severe growth retardation, achalasia, and Down syndrome. *Endoscopy* 44 Suppl 2 UCTN: E285-287.
- Familiari P, Marchese M, Gigante G, Boskoski I, Tringali A, et al. (2013) Peroral endoscopic myotomy for the treatment of achalasia in children. *J Pediatr Gastroenterol Nutr* 57: 794-797.
- Lee BH, Shim KY, Hong SJ, Bok GH, Cho JH, et al. (2013) Peroral endoscopic myotomy for treatment of achalasia: initial results of a Korean study. *Clin Endosc* 46: 161-167.
- Perretta S, Dallemagne B, McMahon B, D'Agostino J, Marescaux J (2011) Video. Improving functional esophageal surgery with a "smart" bougie: Endoflip. *Surg Endosc* 25: 3109.
- Hoppo T, McMahon BP, Witteman BP, Kraemer SJ, O'Rourke RW, et al. (2011) Functional lumen imaging probe to assess geometric changes in the esophagogastric junction following endoluminal fundoplication. *J Gastrointest Surg* 15: 1112-1120.
- Familiari P, Gigante G1, Marchese M1, Boskoski I1, Bove V1, et al. (2014) EndoFLIP system for the intraoperative evaluation of peroral endoscopic myotomy. *United European Gastroenterol J* 2: 77-83.
- Eckardt VF (2001) Clinical presentations and complications of achalasia. *Gastrointest Endosc Clin N Am* 11: 281-292, vi.
- Rohof WO, Hirsch DP, Kessing BF, Boeckxstaens GE (2012) Efficacy of treatment for patients with achalasia depends on the distensibility of the esophagogastric junction. *Gastroenterology* 143: 328-335.
- Teitelbaum EN, Boris L, Arafat FO, Nicodeme F, Lin Z, et al. (2013) Comparison of esophagogastric junction distensibility changes during POEM and Heller myotomy using intraoperative FLIP. *Surgical endoscopy* 27: 4547-4555.
- Rieder E, Swanstrom LL, Perretta S, Lenglinger J, Riegler M, et al. (2013) Intraoperative assessment of esophagogastric junction distensibility during per oral endoscopic myotomy (POEM) for esophageal motility disorders. *Surgical endoscopy* 27: 400-405.

-
17. Teitelbaum EN, Soper NJ, Pandolfino JE, Kahrilas PJ, Boris L, et al. (2014) An extended proximal esophageal myotomy is necessary to normalize EGJ distensibility during Heller myotomy for achalasia, but not POEM. *Surg Endosc* .
18. Verlaan T, Rohof WO, Bredenoord AJ, Eberl S, Rosch T, et al. (2013) Effect of peroral endoscopic myotomy on esophagogastric junction physiology in patients with achalasia. *Gastrointestinal endoscopy* 78:39-44.