

## Intravascular Ultrasound guided Percutaneous Coronary Intervention for the Ostial Lesion of the Anomalous Left Circumflex Artery Originated from Left Coronary Cusp Directly

Toshiki Kuno\*, Kenji Hashimoto and Yohei Numasawa

Department of Cardiology, Ashikaga Red Cross Hospital, Tochigi, Japan

\*Corresponding author: Toshiki Kuno, Department of Cardiology, Ashikaga Red Cross Hospital, Tochigi, Japan, Tel: 81284210121; E-mail: [kuno-toshiki@hotmail.co.jp](mailto:kuno-toshiki@hotmail.co.jp)

Rec date: Jun 03, 2016; Acc date: Jun 27, 2016; Pub date: Jun 30, 2016

Copyright: © 2016 Kuno T, et al. This is an open-access article distributed under the terms of the Creative Commons Attribution License, which permits unrestricted use, distribution, and reproduction in any medium, provided the original author and source are credited.

### Abstract

Percutaneous coronary intervention (PCI) for the ostial lesion of the anomalous left circumflex artery (LCX) originating from the left coronary cusp is challenging because of the difficulty in correctly determining the position of the ostium. This report examines the case of an 81-year-old man with a non-ST segment elevation myocardial infarction with an anomalous LCX origin. An angiography showed the diffuse plaque including the ostium. After successfully engaging an Amplatz-Left guiding catheter and observing the lesion with intravascular ultrasound (IVUS), we dilated the vessel with a balloon. Since we needed to implant the stent to cover the ostial lesion, we used IVUS in combination with angiography to correctly determine the position of the ostium. The stent was implanted successfully and, to our knowledge, this is the first case report of PCI for the separated ostium of the anomalous LCX originating from the left coronary cusp, including the ostial lesion. We also present the IVUS images of both the left anterior descending artery and the LCX.

**Keywords:** Anomalous coronary artery; Myocardial infarction; Percutaneous coronary intervention

### Abbreviations

LAD: Left Anterior Descending Artery; IVUS: Intravascular Ultrasound; LCC: Left Coronary Cusp; LCX: Left Circumflex Artery; LAO: Left Anterior Oblique

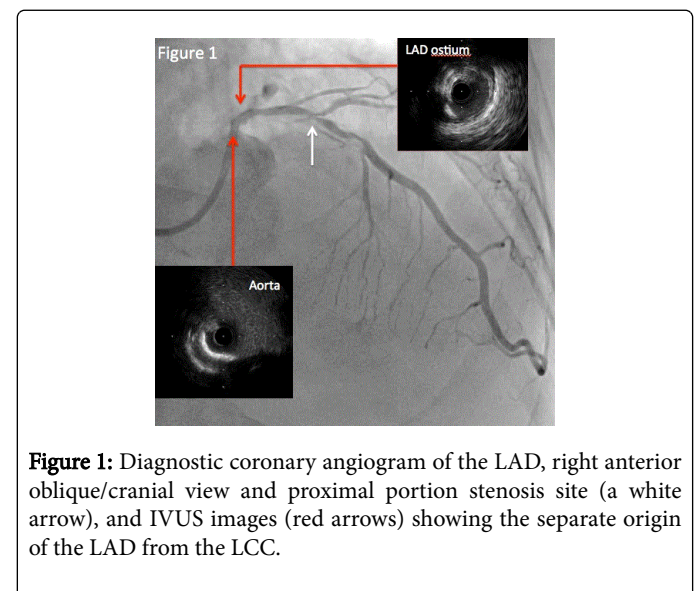
### Introduction

A separate origin of the left anterior descending (LAD) and left circumflex artery (LCX) from the left coronary cusp (LCC) is a rare congenital anomaly and is found in 0.29%-0.69% of coronary angiography or computed tomography cases [1-4]. However, reports of percutaneous coronary intervention (PCI) for an anomalous LCX originating from the LCC are scarce. Performing PCI for an ostial lesion of an anomalous LCX from the LCC is challenging because of the difficulty in correctly determining the position of the ostium. We report a case of non-ST elevation myocardial infarction with an ostial lesion of the anomalous LCX origin, in which the patient underwent successful PCI with intravascular ultrasound (IVUS).

### A Case Report

An 81-year-old man was admitted because of a non-ST-elevation myocardial infarction (NSTEMI) and pulmonary edema. He had a history of hypertension, chronic kidney disease (creatinine 2.0 mg/dl), cerebral infarction, PCI for the right coronary artery and LAD for NSTEMI, atrial fibrillation, and congestive heart failure. The electrocardiogram showed ST depression in V4-6 leads. His creatine kinase level was 420 IU/L, the MB isozyme level was 38 IU/L, and the BNP was 1066 pg/ml. Echocardiography revealed severe hypokinesis of the lateral and posterior walls compared with a previous report and a

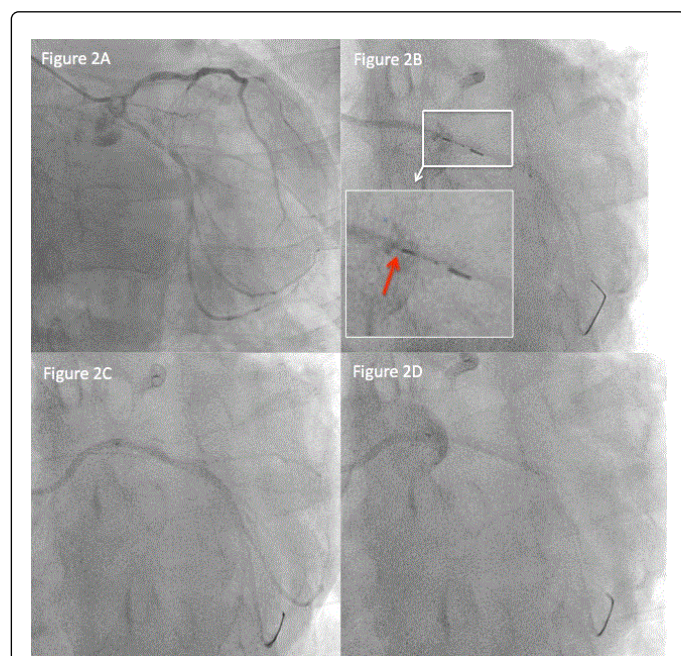
44% ejection fraction. After stabilizing heart failure with noninvasive positive pressure ventilation and intravenous carperitide and furosemide, we performed a coronary angiography. Previous coronary angiography and IVUS (Opticross® Boston Scientific, Marlborough, Massachusetts, USA) revealed separate origins of the LAD and LCX (Figure 1) (Online Video 1).



**Figure 1:** Diagnostic coronary angiogram of the LAD, right anterior oblique/cranial view and proximal portion stenosis site (a white arrow), and IVUS images (red arrows) showing the separate origin of the LAD from the LCC.

We applied a 6-F sheath via a right trans-radial approach. The coronary angiogram with a 4-F diagnostic catheter, Judkins-Left 4.0, Heartcath® (Terumo, Tokyo, Japan), showed an anomalous LCX origin from the LCC with 90% stenosis in the ostium, but it was not engaged completely (Figure 2A, Online Video 2). We could have engaged using the 5-F Amplatz-Left 1.0, Goodtec® (Goodman, Gifu, Japan), but the

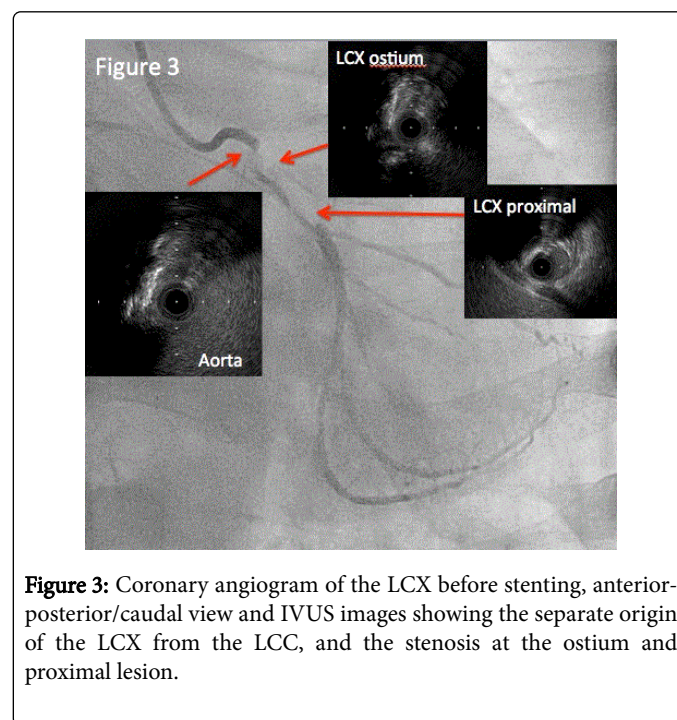
arterial pressure decreased because the catheter was wedged; thus, we could not inject contrast. Then, we proceeded to PCI with a 6-F Profit<sup>®</sup> Amplatz-Left with a side-hole guiding catheter (Goodman) (Online Video 3) After engaging, we observed the stenosis clearly with the angiogram. We inserted a guidewire (SIONblue<sup>®</sup> [Asahi Intecc, Nagoya, Japan]) across the lesion. Then, we observed the lesion with IVUS, View It<sup>®</sup> (Terumo). IVUS showed a diffuse plaque including the ostial lesion (Online Video 4). We dilated the lesion with a 2.5 × 10-mm scoring balloon (Scoreflex<sup>®</sup> [OrbusNeichi, AN Hoevelaken, Netherlands]). After dilating the vessel, we marked the ostium position with IVUS (Figure 2B, Online Video 5); however, injecting contrast in LCX was difficult because of the diffuse proximal lesion. We then smoothly delivered a 3.0 × 26-mm drug-eluting stent (Resolute Integrity<sup>®</sup> [Medtronic, Minneapolis, USA]). Next, we injected contrast in LCX with the different guiding catheter positions (Figures 2C, Online Video 6 and 2D, Online Video 7). To correctly determine the ostium position in combination with IVUS marking following which the stent was implanted (Figure 3).



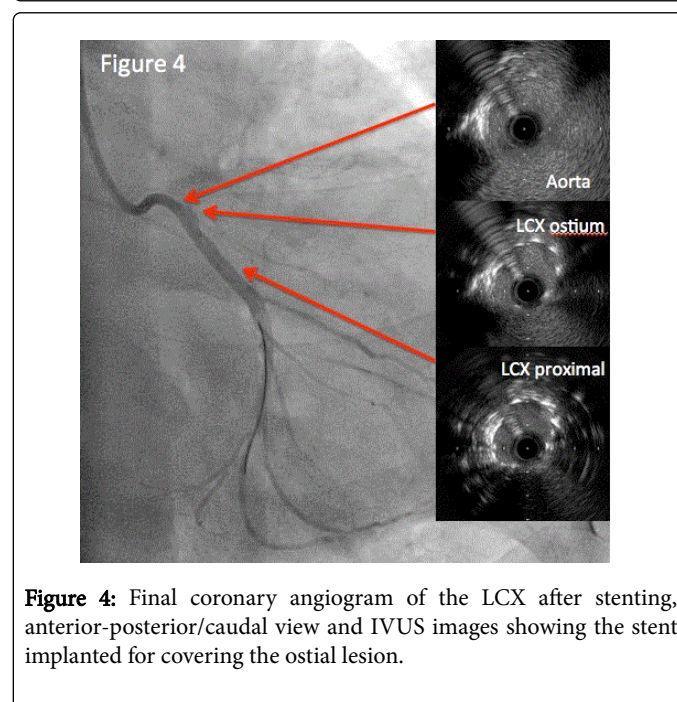
**Figure 2:** A) Diagnostic coronary angiogram of the LCX showing the separate origins of the LAD and LCX; B) IVUS marking of the ostium of the LCX with contrast injection, LAO/caudal view, a red arrow showing the sensor of the IVUS; C) Contrast injection from the ostium, LAO/caudal view; D) Contrast injection from the aorta, LAO/caudal view.

After stenting, IVUS revealed a good stenting position covering the ostial lesion completely (Figure 4, Online Video 8). Because IVUS also showed that the stent was not dilated completely, we dilated the stent with a non-compliant balloon (Powered Lacrosse<sup>®</sup> [Goodman]). The patient's final coronary angiogram showed successful stenting in the ostium/proximal lesion of the LCX (Figure 4, Online Video 9). The total contrast volume for angiography and PCI was 90 ml, and the peak creatinine after PCI was 2.1 mg/dl. The patient was discharged and remained asymptomatic at the 3-month follow-up. After discharge, computed tomography with electrocardiogram synchronization

without contrast showed separate origins of the LAD and LCX and successful stenting in the ostium of the LCX (Figure 5).



**Figure 3:** Coronary angiogram of the LCX before stenting, anterior-posterior/caudal view and IVUS images showing the separate origin of the LCX from the LCC, and the stenosis at the ostium and proximal lesion.

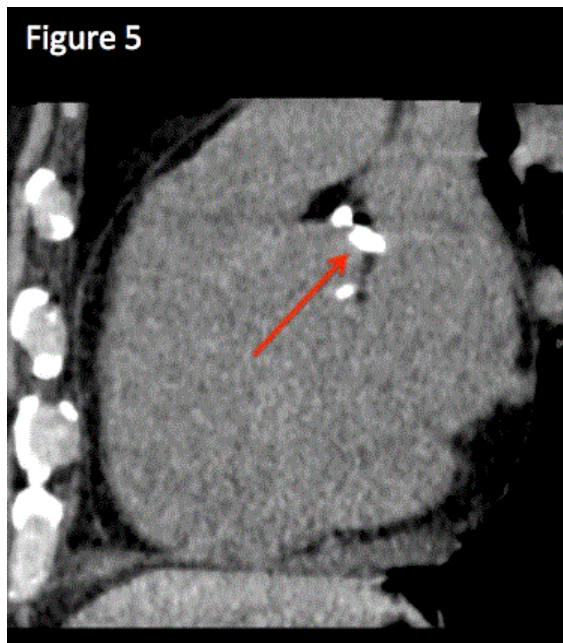


**Figure 4:** Final coronary angiogram of the LCX after stenting, anterior-posterior/caudal view and IVUS images showing the stent implanted for covering the ostial lesion.

## Discussion

The separate origin of the LAD and LCX from the LCC is a rare congenital anomaly with a prevalence of 0.29%-0.69% [1-4]. PCI for an ostial lesion of an anomalous LCX originating from the LCC is challenging because it is difficult to correctly determine the position of the ostium. Complete stent coverage is needed for an aorto-ostial lesion because of high restenosis rates [5].





**Figure 5:** Computed tomography with electrocardiogram synchronization without contrast showing the stent implanted to cover the ostial lesion and separate origins of the LAD and LCX from the LCC.

IVUS is effective for an ostial lesion; a previous report showed the accurate stent position for a left main ostial lesion [6]. In this case, we used IVUS, in combination with angiographies with different guiding catheter positions, to correctly determine the position of the ostium. It was difficult to determine the correct position of the ostium with IVUS marking with contrast injection because the LCC was also contrasted. Therefore, we contrasted the ostium with different guiding positions to confirm the ostium position, in combination with the contrast image

with IVUS marking, and implanted the stent successfully. A previous report showed IVUS images of the LAD of separate origins of the LAD and LCX [7]; however, we showed IVUS images of the LAD and LCX. To the best of our knowledge, this is the first case report of PCI for the separate ostium of the anomalous LCX originated from the left coronary sinus including the ostial lesion, and demonstrating the separate origins of the LAD and LCX with IVUS.

## Conclusion

We recommend using IVUS to implant the stent for ostial lesions of the LCX originated from the LCC. We describe a successful case of treating the anomalous LCX ostial lesion with IVUS.

## References

1. Graidis C, Dimitriadis D, Karasavvidis V, Dimitriadis G, Argyropoulou E, et al. (2015) Prevalence and characteristics of coronary artery anomalies in an adult population undergoing multidetector-row computed tomography for the evaluation of coronary artery disease. *BMC cardiovascular disorders* 15: 112.
2. Akpinar I, Sayin MR, Karabag T, GURSOY YC, KUCUK E, et al. (2013) Differences in sex, angiographic frequency, and parameters in patients with coronary artery anomalies: single-center screening of 25 368 patients by coronary angiography. *Coronary artery disease* 24: 266-271.
3. Sohrabi B, Habibzadeh A, Abbasov E (2012) The incidence and pattern of coronary artery anomalies in the north-west of Iran: a coronary arteriographic study. *Korean circulation journal* 42: 753-760.
4. Yildiz A, Okcun B, Peker T, Arslan C, Olcay A, et al. (2010) Prevalence of coronary artery anomalies in 12,457 adult patients who underwent coronary angiography. *Clinical cardiology* 33: 60-64.
5. Dishmon DA, Elhaddi A, Packard K, Gupta V, Fischell TA (2011) High incidence of inaccurate stent placement in the treatment of coronary aorto-ostial disease. *The Journal of invasive cardiology* 23: 322-326.
6. Eeckhout E, Berger A, Lyon X, Imsand C, Davin L, et al. (2005) Elective ostial left main stenting: a tailored approach. *The Journal of invasive cardiology* 17: 125-128.
7. Thomas J, Shavelle DM (2005) Intravascular ultrasound imaging of separate ostium of left anterior descending and circumflex arteries. *Heart* 91: 1079.