

Laimer's Diverticulum, A Rare True Diverticulum Inferior to the Cricopharyngeus: Report of a Case and Review of the Literature

Duy Nguyen*, Mohammad Moslemi, Badi Rawashdeh, Mark Meyer, Cameron Garagozlo, Simin Golestani, Barbara Tempesta, Keith Maas, Abdul Wali Yousufzai and Farid Gharagozloo

The University of Arizona Medical Center, Tucson, Arizona, USA

Abstract

Hypopharyngeal esophageal diverticula are rare with the most common type being the Zenker's diverticulum. This diverticulum arises from Killian's triangle above the cricopharyngeus muscle; however there are two much rarer hypopharyngeal diverticula distinct from the Zenker's diverticulum, the Killian-Jamieson diverticulum and the Laimer's diverticulum. We present a 46 year old male with a hypopharyngeal diverticulum inferior to the cricopharyngeus in the posterior midline consistent with a Laimer's diverticulum, detail our surgical technique, and review the literature on the diagnosis, etiology, and treatment of this rare phenomenon.

Keywords: Laimer's; Esophageal; Cricopharyngeus; Diverticulum; Zenker's

Introduction

Proximal esophageal diverticula are rare with the most common type being Zenker's diverticulum. This diverticulum results from the lack of relaxation of the cricopharyngeus muscle during swallowing, causing a pulsion diverticulum in Killian's triangle between the cricopharyngeus and the inferior pharyngeal constrictor muscles [1]. A much rarer type, Laimer's diverticulum, has been described in three prior case reports [2-4] and arises from the posterior upper esophagus, inferior to the cricopharyngeus. We present a case of a patient with a hypopharyngeal posterior true diverticulum inferior to the cricopharyngeus consistent with Laimer's diverticulum.

Materials and Methods

The patient is a 46 year old male presenting with six months of persistent cough and coughing up food remnants shortly after consumption. We proceeded with standard diagnostic testing including barium swallow, esophagogastroduodenoscopy, and esophageal manometry to determine the etiology of these symptoms. Based on these findings we determined the need for surgical intervention.

Results

Esophagogastroduodenoscopy (Figure 1) and barium swallow (Figure 2) and showed a proximal esophageal diverticulum erroneously diagnosed as Zenker's diverticulum. Manometric studies were not possible due to preferential insertion of the manometry probe into the diverticulum.

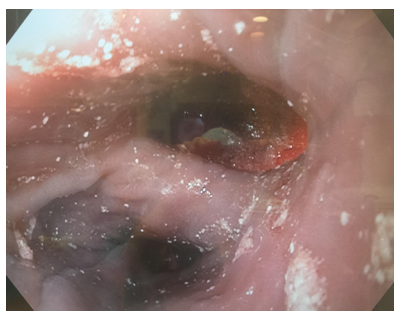


Figure 1: Preoperative Upper Endoscopy. Demonstrating two lumens in the esophagus.

The patient underwent a hypopharyngeal diverticulectomy and cricopharyngotomy via a left neck approach.

Technique

This procedure began with a left transcervical approach. Once adequate exposure of the deep neck structures was obtained, endoscopy was performed to clearly identify the esophagus and diverticulum. There were several features that made this diverticulum distinct from a Zenker's diverticulum. First, this diverticulum had a wide neck (Figure 1). Second, it was covered by esophageal muscle. Third, it emanated from below the cricopharyngeus (Figure 3) in Laimer's Triangle.

The diverticulum was carefully dissected free from surrounding tissue, and a myotomy was begun just distal to the inferior margin of the diverticulum and extended 3 cm distally. A 60 French bougie was placed in the lumen of the esophagus and the diverticulum was excised.

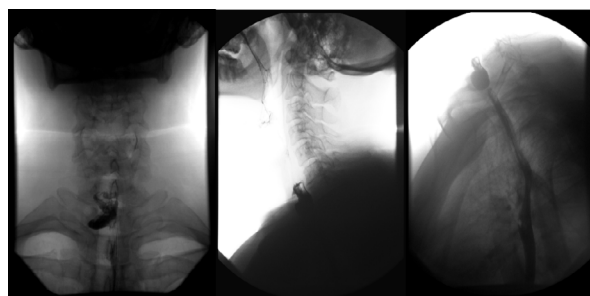


Figure 2: Preoperative barium esophagram. Anterior and lateral views demonstrating a 2 cm diverticulum with a 1 cm neck emerging from the posterior aspect of the esophagus and extending to the right cervical region.

***Corresponding author:** Duy Nguyen, The University of Arizona Medical Center, Division of Cardiothoracic Surgery, 1501 N. Campbell Avenue, PO Box 245071, Tucson, AZ 85724-507, USA, Tel: (520) 626-7951; Fax: (520) 626-4042; E-mail: duynguyen@surgery.arizona.edu

Received September 03, 2014; **Accepted** October 26, 2014; **Published** October 28, 2014

Citation: Nguyen D, Moslemi M, Rawashdeh B, Meyer M, Garagozlo C, et al. (2014) Laimer's Diverticulum, A Rare True Diverticulum Inferior to the Cricopharyngeus: Report of a Case and Review of the Literature. J Clin Case Rep 4: 423. doi:[10.4172/2165-7920.1000423](https://doi.org/10.4172/2165-7920.1000423)

Copyright: © 2014 Nguyen D, et al. This is an open-access article distributed under the terms of the Creative Commons Attribution License, which permits unrestricted use, distribution, and reproduction in any medium, provided the original author and source are credited.

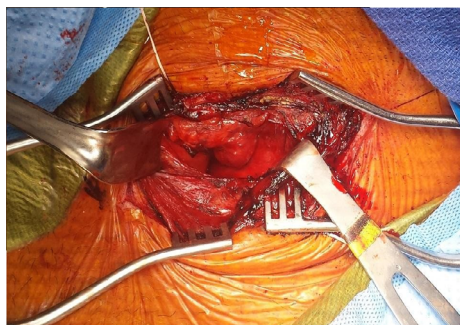


Figure 3: Intraoperative image of dissected neck and diverticulum. Exposure of the esophagus with posterior diverticulum dissected and brought into surgical field.

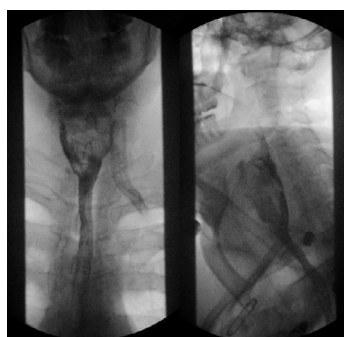

Figure 4: Postoperative barium esophagram anterior and lateral views showing esophageal contour and no contrast extravasation.

using a 30 mm TA linear stapler using 3.75 cm staples (blue load). The staple line was covered with esophageal muscle using interrupted 4-0 vicryl sutures. A Jackson Pratt drain was placed along the staple line and the wound was closed.

Post-operative management

The patient was kept NPO for 5 days, after which a barium esophagram showed normal swallowing, normal esophageal contour, and no evidence of contrast extravasation (Figure 4). Diet was advanced as tolerated and the Jackson Pratt drain was removed once daily output was below 15 ml. The patient was discharged on postoperative day 5 on a mechanical soft diet.

Follow-up

On 4 week follow up, patient was tolerating a regular diet, having minimal dysphagia and no complaints of persistent cough or coughing up food remnants after eating.

Discussion

The most common hypopharyngeal diverticula, Zenker's diverticulum, was described by Ludlow in 1769 [5] and has an annual incidence of 2 per 100,000 [6]. Zenker's is described as a pulsion diverticulum caused by esophageal dysmotility and inadequate relaxation of the cricopharyngeus muscle. It is hypothesized that when pharyngeal pressures increase against the contracted cricopharyngeus, a diverticulum forms in the weakest region above the cricopharyngeus, Killian's Triangle [7] (Figure 5).

Less commonly is Killian-Jamieson diverticulum [8-11]. First

described in 1983, this diverticulum is located in the Killian-Jamieson area inferior to the cricopharyngeus on the anterolateral aspects of the esophagus near the insertion of the cricopharyngeus into the cricoid cartilage (Figure 6) [12].

Much less common is Laimer's diverticulum which arises inferior to the cricopharyngeus in the posterior midline (Figure 5) in Laimer's triangle, located in the posterior aspect of the esophagus covered only by the circular layer of esophageal muscle [13]. Laimer's diverticulum has been documented in three cases in the literature [2-4]. In 1993, Boysen reported two large hypopharyngeal diverticula in one patient with an upper diverticulum originating above the cricopharyngeus and a lower diverticulum originating below the cricopharyngeus. Kobayashi and Kumoi reported a single diverticulum coming from Laimer's triangle. The present report describes the fourth patient with a Laimer's diverticulum.

Laimer's diverticulum can be differentiated from a Zenker's diverticulum by the fact that the diverticulum: 1) originates below rather than above the cricopharyngeus muscle; 2) is broad based; 3) is seen in a

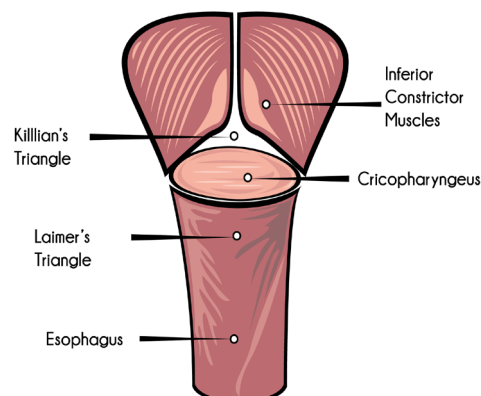


Figure 5: Diagram of the posterior view of pharyngeal muscles. Killian's triangle is located above the cricopharynx and below the inferior constrictor muscles. Laimer's triangle is located below the cricopharynx and above the confluence of the longitudinal esophageal muscle layer.

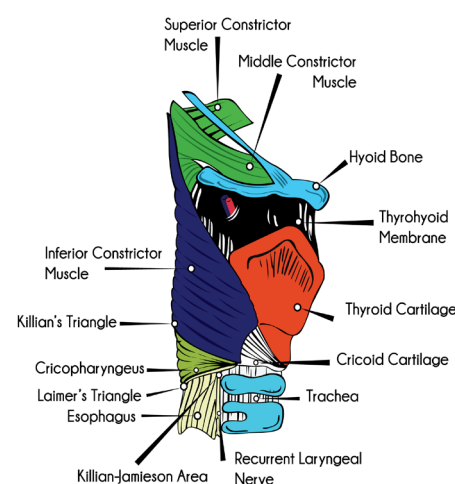


Figure 6: Diagram of the lateral view of pharyngeal muscles. The Killian-Jamieson area is located bilaterally inferior to the insertion of the cricopharynx into the cricoid cartilage.

younger patient population, thereby suggesting an intrinsic esophageal dysmotility disorder as opposed to senile dysmotility related to the lack of relaxation of the cricopharyngeus muscle associated with Zenker's diverticulum; 4) is a full thickness true diverticulum.

Laimer's diverticulum most likely is related in its pathophysiology to diverticula of the body of the esophagus. There is growing evidence that many mid-esophageal diverticula are caused by esophageal dysmotility disorders, calling into question the classic description of full thickness and midesophageal diverticula being created by a traction mechanism. Borrie reviewed 50 consecutive cases of esophageal diverticula finding 5 mid esophageal diverticula. 4 out of these 5 had documented motor disorders of the esophagus with no history of intrathoracic infections [14]. These authors suggested that all patients with diverticula of the body of the esophagus undergo manometric studies in order to accurately diagnose the etiology. This fact likely applies to patients with suspected Laimer's diverticulum.

It is important to note that Laimer's diverticulum may not be easily differentiated from Zenker's diverticulum using preoperative contrast studies. Endoscopy would be diagnostic in differentiating these two diverticula because Laimer's diverticulum will have a broad base. Because of its locations, Laimer's diverticulum cannot be treated using transoral endoscopic techniques. Careful endoscopy helps in this vital differentiation. The optimal approach to a patient with Laimer's diverticulum is a transcervical diverticulectomy and an esophageal myotomy distal to the diverticulum. The side for the cervical operative approach should be chosen based on the location of the diverticulum. Due to the presence of a dysmotility disorder and the long suture line for the diverticulectomy, these patients should be treated like other patients with esophageal resection and oral intake should commence following a negative contrast study five to nine days following surgery.

Conclusion

Laimer's diverticulum is an extremely rare hypopharyngeal posterior midline true esophageal diverticulum inferior to the cricopharyngeus muscle. The low incidence of this phenomenon leaves the etiology and most efficacious treatment unclear, though there is support for a pulsion mechanism secondary to an esophageal dysmotility disorder. We recommend manometric studies to identify

motor dysfunction and a left transcervical pharyngomyotomy and diverticulectomy for these patients.

References

1. Costantini M, Zaninotto G, Rizzetto C, Narne S, Ancona E (2004) Oesophageal diverticula. *Best Pract Res Clin Gastroenterol* 18: 3-17.
2. Kumoi K, Ohtsuki N, Teramoto Y (2001) Pharyngo-esophageal diverticulum arising from Laimer's triangle. *Eur Arch Otorhinolaryngol* 258: 184-187.
3. Boysen M, Aasen S, Løvteit T, Bakka A (1993) Two simultaneously occurring hypopharyngo-oesophageal diverticula. *J Laryngol Otol* 107: 49-50.
4. Kobayashi M, Ito S, Sawada T, Deguchi M, Lin S, et al. (1993) [A case of diverticulum originating from the Laimer's triangle (in Japanese)]. *Geka Shinryou* 35: 889-892.
5. Ludlow A (1769) A case of obstructed deglutition from a preternatural dilatation of, and bag formed in the pharynx. *Medical Observations and Inquiries* 3: 85-101.
6. Laing MR, Murthy P, Ah-See KW, Cockburn JS (1995) Surgery for pharyngeal pouch: audit of management with short- and long-term follow-up. *J R Coll Surg Edinb* 40: 315-318.
7. Costantini M, Zaninotto G, Rizzetto C, Narne S, Ancona E (2004) Oesophageal diverticula. *Best Pract Res Clin Gastroenterol* 18: 3-17.
8. Tang SJ, Tang L, Chen E, Myers LL (2008) Flexible endoscopic Killian-Jamieson diverticulotomy and literature review (with video). *Gastrointest Endosc* 68: 790-793.
9. Lee CK, Chung IK, Park JY, Lee TH, Lee SH, et al. (2008) Endoscopic diverticulotomy with an isolated-tip needle-knife papillotome (Iso-Tome) and a fitted overtube for the treatment of a Killian-Jamieson diverticulum. *World J Gastroenterol* 14: 6589-6592.
10. Rubesin SE, Levine MS (2001) Killian-Jamieson diverticula: radiographic findings in 16 patients. *AJR Am J Roentgenol* 177: 85-89.
11. Rodgers PJ, Armstrong WB, Dana E (2000) Killian-Jamieson diverticulum: a case report and a review of the literature. *Ann Otol Rhinol Laryngol* 109: 1087-1091.
12. Ekberg O, Nylander G (1983) Lateral diverticula from the pharyngo-esophageal junction area. *Radiology* 146: 117-122.
13. Schunke M, Schulte E, Schumacher U. *Atlas of Anatomy: Neck and Internal Organs*. 2006; 33.
14. Borrie J, Wilson RL (1980) Oesophageal diverticula: principles of management and appraisal of classification. *Thorax* 35: 759-767.